Check for updates

Dermoid and Epidermoid Cysts of Scalp: Case Series of 234 Consecutive Patients

Alessandro Prior[1,2], Pasquale Anania[1,2], Mattia Pacetti[1], Francesca Secci[1], Marcello Ravegnani[1], Marco Pavanello[1], Gianluca Piatelli[1], Armando Cama[1], Alessandro Consales[1]

Key words
- Cranial
- Cyst
- Dermoid
- Epidermoid
- Pediatric
- Scalp
- Skull

From the [1]Division of Neurosurgery, IRCCS Istituto Giannina Gaslini, Genoa; and [2]Neurosurgery Unit, Ospedale Policlinico "San Martino," Genoa, and University of Turin, Turin, Italy

To whom correspondence should be addressed: Pasquale Anania, M.D.
[E-mail: pas.anania@gmail.com]

Citation: World Neurosurg. (2018) 120:119-124.
https://doi.org/10.1016/j.wneu.2018.08.197

Journal homepage: www.WORLDNEUROSURGERY.org

Available online: www.sciencedirect.com

1878-8750/$ - see front matter © 2018 Elsevier Inc. All rights reserved.

■ BACKGROUND: **Dermoid and epidermoid cysts are among the most frequent lesions of the scalp in the pediatric population. Optimal management of a suspected dermoid or epidermoid cyst in children is debated: Some authors advocate conservative management on the basis of the benign histology of these entities, while others prefer surgical excision.**

■ OBJECTIVE: **Our objective is to demonstrate that excision of dermoid and epidermoid cysts is a safe procedure and that early surgery is effective in preventing potential complications related to cyst growth.**

■ METHODS: **We retrospectively collected data on patients who underwent surgery for excision of proven dermoid or epidermoid cysts between January 2006 and October 2017.**

■ RESULTS: **In 234 patients, 237 cysts were excised. Mean age at presentation was 26.99 ± 32.7 months; 48.7% of patients were operated on between 1 and 3 years of age, and 32.9% were younger than 1 year of age. Cysts were more frequently located in the frontal bone than in occipital and supraorbital regions. In 36.28% of cases there was no significant cranial impingement, while 21.94% of the cysts eroded through a partial thickness of the cranium, 12.23% were in the full thickness of the skull, and 0.84% had epidural extension. We identified 22 intradiploic cysts. Statistical analysis demonstrated significant association between frontal and pterional localization and bone erosion. Neither major complications nor cyst recurrence were observed.**

■ CONCLUSIONS: **Excision of dermoid and epidermoid cysts is a safe procedure for neurosurgeons dealing with this disease, even in young patients. Early resection is recommended due to the potential adverse effects that may occur if these cysts are left untreated.**

INTRODUCTION

Dermoid and epidermoid cysts are benign cutaneous tumors that may be present at birth and develop from the entrapment of the surface ectoderm along the lines of embryonic fusion.[1] The head is a frequent location for these lesions in pediatric patients.[2-4] Concerns arise over the correct management of a solitary lump on the head of a child, thought to be a dermoid or epidermoid cyst. The fact that these cysts are benign lesions could suggest a conservative management with planned follow-up.[5] On the other hand, a more aggressive management with surgical excision has been advocated because cysts characteristically tend to enlarge[6,7] and are able to erode the cranial bone with possible consequent epidural extension. Cysts can also become symptomatic because of rupture or infection.[7-9] Another important advantage of surgical excision is the possibility of obtaining a histologic diagnosis because, though rare, malignant tumors must be considered in the differential diagnosis of a solitary lump in the head of a child.[10] Malignancies may also rarely develop into long-lasting scalp dermoids.[11] Finally, cosmetic issues should also be taken into account.[12] Here we present our case series of 234 consecutive pediatric patients who underwent surgical excision of histologically proven dermoid or epidermoid cysts of the head. To the best of our knowledge, this is the largest series of dermoid and epidermoid cysts of the scalp reported in the literature. Concerns about the management of these lesions are also discussed.

METHODS

We use PROCESS guidelines for the description of our case series.[13] Our research is registered in Research Registry (UIN researchregistry3732). We retrospectively analyzed the clinical data of consecutive pediatric patients who underwent surgical excision of a histologically proven dermoid or epidermoid cysts.

Data Collection

From January 2006 to November 2017, 234 children underwent surgery for excision of 237 cysts at Gaslini Children's Research Hospital, Genoa, Italy. Collected data included demographic information, lesion location, lesion number, bone involvement, intradural extension, type of resection (en bloc or piecemeal), histologic diagnosis, recurrent disease at follow-up, and esthetic outcome. Skull erosion was defined as insignificant (a), partial thickness (b), full thickness (c), and full

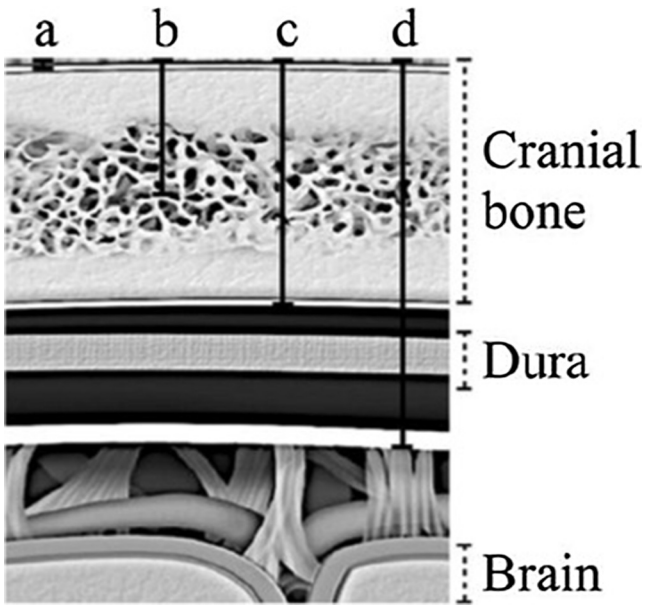

Figure 1. Bone erosion classification. Erosion was defined as a) insignificant, b) partial thickness, c) full thickness, and d) full thickness with epidural extension. (From Khalid S, Ruge J. Considerations in the management of congenital cranial dermoid cysts. *J Neurosurg.* 2017;20:30-34.)

thickness with epidural extension (d) according to the classification proposed by Khalid and Ruge (Figure 1).[14] Furthermore, we identified as "intradiploic" those cysts growing within the diploe and potentially expanding or infiltrating the inner and outer tables.[15,16]

Preoperative Management

After physical examination and medical history evaluation, all pediatric patients with suspected dermoid or epidermoid cysts on their heads underwent ultrasound examination. Thereafter, in case of ultrasound suspicion of high-grade bone erosion, a computed tomography scan of the head was performed for further confirmation and evaluation. A minimum size to perform a surgical treatment has not been considered; indeed, in most cases, patients sought medical attention when the lesions were small but visually appreciable and tended to increase over time.

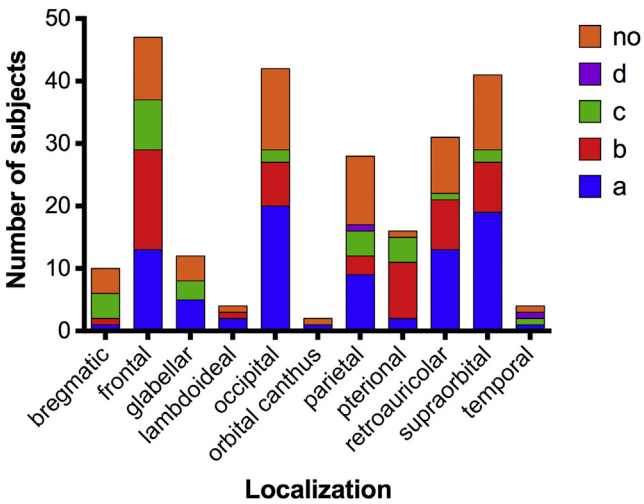

Figure 2. The figure shows cyst locations and related bone invasion for each location. The frontal region is the most frequent location. Frontal and pterional cysts have a higher extension to skull bone.

Operative Management

All surgical procedures were performed by one of the authors. Surgery consisted of a small skin incision just above the cyst. The operative approach depended on lesion location. For cysts located in the supraorbital or glabellar region, eyelid incisions were performed. For cysts located in the frontal bone on the midline, the incision was made behind the hairline. Gross total resection was the aim of surgical treatment. In case of cyst rupture during dissection, care was taken to remove all the material extruded from the cyst with copious irrigation and coagulation. The pericranial flap over the cyst was removed, and its free margins were coagulated. If cranial remodeling under the cyst or erosion and infiltration of the skull were observed, copious irrigation and monopolar coagulation of the bone were performed. In case of dural violation (depression or thinning of the dura), dural opening and intradural exploration were performed. Pericranial flap for closure was used only in case of epidural extension or dural violation with its opening. Cranioplasty was never performed in our cases because extension of skull erosion was reduced, also thanks to early diagnosis at a young age. We did not repair these small bone defects because, during growth, bone repair is spontaneous.

Postoperative Management

Patients were usually hospitalized on the day before surgery and discharged the day after. Analgesic drugs were used for management of postoperative pain. After discharge, patients were examined as outpatients twice: first at 1 week from surgery and then 3 months after surgery. We asked the patients' parents and pediatricians to report any change in the wound or suspected cyst recurrence.

Download English Version:

https://daneshyari.com/en/article/10215700

Download Persian Version:

https://daneshyari.com/article/10215700

Daneshyari.com