




ELSEVIER

Contents lists available at ScienceDirect

Medical Mycology Case Reports

journal homepage: www.elsevier.com/locate/mmcrr

Gastrointestinal cryptococcoma – Immune reconstitution inflammatory syndrome or cryptococcal relapse in a patient with AIDS?

Abdu K. Musubire^{a,c,*}, David B. Meya^{a,b,c}, Robert Lukande^d, Andrew Kambugu^{a,b}, Paul R. Bohjanen^b, David R. Boulware^b

^a Infectious Disease Institute, College of Health Sciences, Makerere University, Kampala, Uganda

^b Division of Infectious Diseases & International Medicine, Department of Medicine, University of Minnesota, Minneapolis, MN, USA

^c Department of Medicine, School of Medicine, College of Health Sciences, Makerere University and Mulago Hospital, Kampala, Uganda

^d Department of Pathology, College of Health Sciences, Makerere University, Kampala, Uganda

ARTICLE INFO

Article history:

Received 31 January 2015

Received in revised form

11 March 2015

Accepted 23 March 2015

Available online 26 March 2015

Keywords:

HIV

AIDS

Cryptococcal meningitis

Cryptococcoma

Antiretroviral therapy

Immune reconstitution inflammatory syndrome

ABSTRACT

The introduction of antiretroviral therapy (ART) may lead to unusual paradoxical and unmasking presentations of opportunistic infections. Intra-abdominal cryptococcosis is a rare manifestation of *Cryptococcus*. We present the case of an HIV-infected patient on ART, with a history of cryptococcal meningitis who presented with subacute, worsening abdominal pain during immune recovery. This evolved into chronic abdominal pain, with thickened bowel, and abdominal lymphadenopathy, while receiving empiric tuberculosis treatment. At 6-months, he developed intestinal perforation due to a histologically confirmed cryptococcoma.

© 2015 The Authors. International Society for Human and Animal Mycology Published by Elsevier B.V.

This is an open access article under the CC BY-NC-ND license

(<http://creativecommons.org/licenses/by-nc-nd/4.0/>).

1. Introduction

Substantial improvement in survival of people living with HIV has been observed with the introduction of antiretroviral therapy (ART) in sub-Saharan Africa [1]. However, the introduction of ART has led to new immune-mediated complications from dysfunction of the recovering immune system, termed immune reconstitution inflammatory syndrome (IRIS) [2]. In patients with cryptococcal meningitis (CM), a very common opportunistic infection in sub-Saharan Africa, IRIS is a frequent complication that is most often associated with exaggerated inflammatory responses in the central nervous system. Although CM remains the most common cause of adult meningitis in the overall population in sub-Saharan Africa [3], there are only a few recognized, reported cases of gastrointestinal (GI) involvement with *Cryptococcus* in the literature [4]. The presentation of GI cryptococcosis is vague and often mistaken for other conditions [5]. Here, we describe intra-

abdominal cryptococcoma as an unusual manifestation of Cryptococcosis. An HIV-infected patient on ART with a history of recent CM presented with chronic abdominal pain, thickened ileum, and abdominal lymphadenopathy. He was initially treated for abdominal Tuberculosis (TB) but later, he was shown to have a histologically confirmed cryptococcoma in the ileum. The major objective of this case report is to highlight the challenges in diagnosis and management of intra-abdominal cryptococcosis, especially in the setting of recent initiation of ART.

2. Case report

A 37 year old HIV-positive male was initially diagnosed and treated for CM in May of 2009 with amphotericin induction therapy for 2 weeks followed by fluconazole 400 mg/day. The initial fungal burden was 300 colony forming units/10 µL. He had a protracted hospital course lasting 4 weeks because of persistently high intracranial hypertension despite sterilization of his cerebrospinal fluid, and he, required repeated therapeutic lumbar punctures. He started ART (zidovudine, lamivudine, and efavirenz)

* Correspondence to: Infectious Diseases Institute, Mulago Hospital Complex, P.O. Box 22418, Makerere University, Kampala, Uganda.

E-mail address: amusubire@yahoo.com (A.K. Musubire).

on the 11th June 2009 with a baseline CD4 count of 5 cells/ μ L. At day +21 of ART, he reported abdominal pain with hypogastric tenderness that was empirically treated as urinary tract infection with a 5 day course of ciprofloxacin, and he noted some improvement. His CD4 count at the time had risen to 29 cells/ μ L. At day +35 of ART, the abdominal pain recurred associated with low grade fevers and a dry cough. His general exam was unremarkable, except for a tachypnea of 28 breaths per minute. The abdominal exam revealed tenderness in the right iliac fossa without any mass. A complete blood count, chest radiograph, and abdominal ultrasound were all unremarkable. The patient was managed as a possible atypical pneumonia with doxycycline, and his respiratory symptoms improved. However, the abdominal pain persisted intermittently with occasional vomiting. At day +84 of ART and in view of the persistent abdominal pain and an occasional dry cough, another chest radiograph was performed to exclude TB, which was also unremarkable. At this time, his CD4 was only 14 cells/ μ L, and the HIV-1 viral load was 22,000 copies/mL. He reported 100% adherence to his ART, and pill counts verified his adherence. At day +112 of ART, the patient still had similar complaints of abdominal pain and occasional vomiting. An abdominal ultrasound revealed an appendicular mass and para-aortic lymphadenopathy. Repeat CD4 was 8 cells/ μ L, and the viral load was minimally decreased at 15,475 copies/mL. The patient initially declined an ultrasound-guided biopsy but consented to the procedure at day +140 of ART. This second ultrasound revealed a thickened ileum up to 6mm, with adjacent 1 cm lymph nodes. Two biopsy specimens from the lymph nodes demonstrated no abnormality at histology. At day +168, the patient still had the same complaints with almost unchanged CD4 of 24 cells/ μ L and viral load of 23,755 copies/mL. He was presumed to be failing ART, possibly due to poor absorptive surface because of the thickened gut wall. A decision was made to initiate empiric anti-TB treatment for possible gastrointestinal TB. After one week of TB empiric therapy, the patient presented with an acute abdomen, having signs of focal peritonitis in the right iliac fossa. An upright abdominal radiograph demonstrated evidence of perforation with free air visible under the right hemidiaphragm. An emergency laparotomy was performed, revealing fecal matter with purulent fluid, adhesions, pneumoperitonium, and intestinal perforation at 10 cm proximal to the ileocecal junction. Ten cm of thickened ileum was resected (Fig. 1). His post-operative course was unremarkable. The confirmatory histopathology report received 2 weeks later revealed a cryptococcoma in the ileal wall as the cause of the perforation with exuberant inflammation

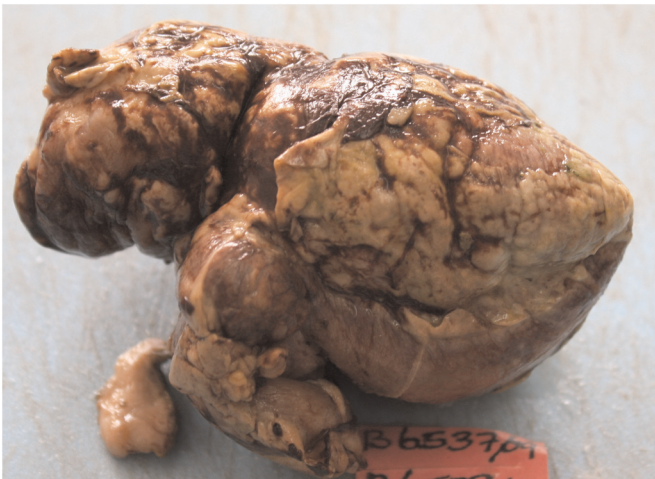

Fig. 1. This gross pathology photograph shows a matted ileum with a thick fibrinopurulent yellow suppurative exudate and fibrin covering the serosal surface.

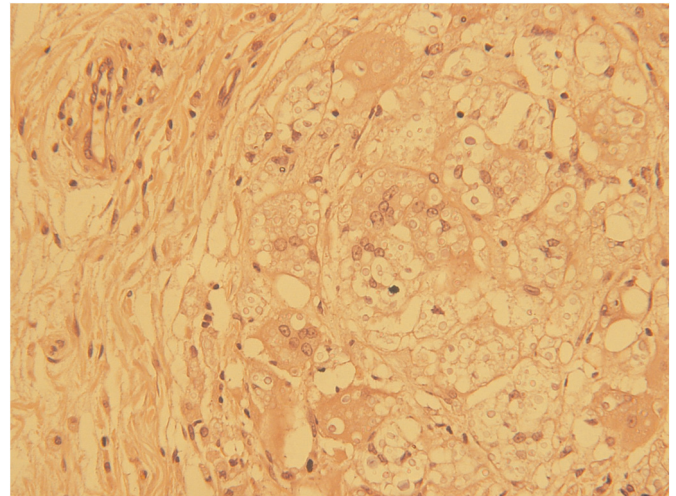


Fig. 2. This photomicrograph of a hematoxylin and eosin stained section of the ileum at magnification $\times 20$ objective shows *Cryptococcus neoformans* yeast seen in the cystic empty spaces. The yeasts appear as small round structures.

demonstrated by the multinucleated giant cell (Figs. 2 and 3 on hematoxylin and eosin stain and Figs. 4 and 5 on Periodic acid-Schiff stain). The patient's marked clinical improvement after surgery, the lack of any evidence of Cryptococcal infection elsewhere in the body especially in the central nervous system and a well formed granuloma formed the basis for the patient's continuation with maintenance dose of fluconazole 200 mg/day under observation. At this point, his TB medications were stopped and he was switched to second line ART with subsequent viral suppression. Through December 2014, he continues to remain in care on

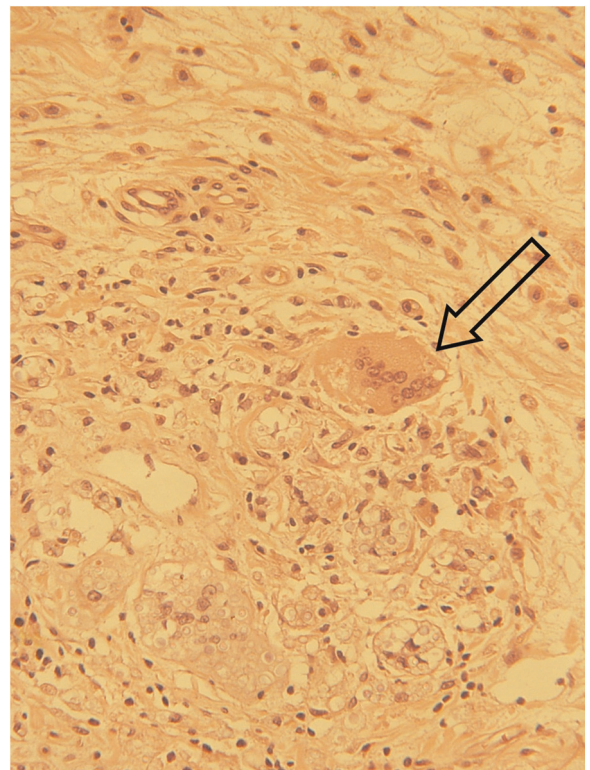


Fig. 3. This photomicrograph of a hematoxylin and eosin stained section of the ileum at magnification $\times 20$ objective also shows *Cryptococcus neoformans* yeasts seen in the cystic empty spaces. Take note of the giant cell with numerous yeast forms in its cytoplasm (arrow), representing intracellular parasitism by the *Cryptococcus*.

Download English Version:

<https://daneshyari.com/en/article/2400508>

Download Persian Version:

<https://daneshyari.com/article/2400508>

[Daneshyari.com](https://daneshyari.com)