Journal of Hand Therapy 28 (2015) 82–85

Contents lists available at ScienceDirect

Journal of Hand Therapy

journal homepage: www.jhandtherapy.org

JHT Read for Credit Article #343.

Practice Forum

Mobilization with movement and elastic tape application for the conservative management of carpometacarpal joint osteoarthritis

Jorge Hugo Villafañe PhD, MSc, PT[a], Kristin Valdes OTD, OT, CHT[b,c,*]

[a] IRCCS Don Gnocchi Foundation, Milan, Italy
[b] Hand Works Therapy, Sarasota, FL, USA
[c] Drexel University, Philadelphia, PA, USA

Carpometacarpal osteoarthritis can limit a person's ability to engage in desired activities. Many therapists utilize conservative approaches to assist these patients. These authors describe utilizing a combination of mobilization with movement and the use of elastic tape for patients with this arthritis. — Victoria Prigang, PhD, OTR, CHT, CLT, Practice Forum Editor.

Conservative therapy has been shown to relieve symptoms for patients with early stage carpometacarpal (CMC) osteoarthritis (OA) disease, and can stave off surgical interventions either temporarily or in the long term.[1,2] The predilection of CMC OA can be attributed to anatomic, hereditary and hormonal factors, all resulting in greater joint contact pressure.[3,4] There also exists a strong association between excessive joint laxity and the development of premature joint degenerative changes[5] and proprioceptive deficits of the ligaments of the CMC joint.[6]

A combined program of mobilization with movement (MWM) and kinesiology tape has been shown to reduce pain, increase range of motion, and increase tip pinch strength in a patient with severe functional impairment related to dominant CMC OA.[7] Obrien and Givens study demonstrated that joint mobilization and elastic taping was effective in reducing pain and increasing functional scores in individuals with CMC OA.[1] The specifics regarding the applied application of the mobilization technique and elastic tape may be clinically useful.

MWM as a manual therapy technique has been described as an effective modality for pain reduction and improved function in a number of studies for both traumatic and non-traumatic joint disorders.[8–14]

Interventions

Mobilization with movement

1. To perform the mobilization technique, the therapist positions the first metacarpal toward neutral.
2. The interphalangeal (IP) and the metacarpophalangeal (MP) joints of the thumb can be in flexion or relaxed.
3. The therapist manually reduces the subluxation of the 1st CMC joint. To find the position that best allows for pain-free motion, the therapist needs to experiment with and fine-tune the direction and pressure of the manual glide using feedback from the patient. After the therapist manually glides the first metacarpal into a position neutral to the previous resting position of the thumb, the patient should then be immediately able to move into previously painful ranges without discomfort. The therapist should note the arc of pain free range of motion. This position and the now active pain-free thumb motion serve as the MWM technique for these patients (Fig. 1a).
4. The therapist then asks the patient to move the CMC joint of the thumb in extension/flexion and abduction/adduction, 3 sets of

* Corresponding author. Hand Works Therapy, Sarasota, FL, USA.
E-mail address: hotglassgal@comcast.net (K. Valdes).

http://dx.doi.org/10.1016/j.jht.2014.08.001

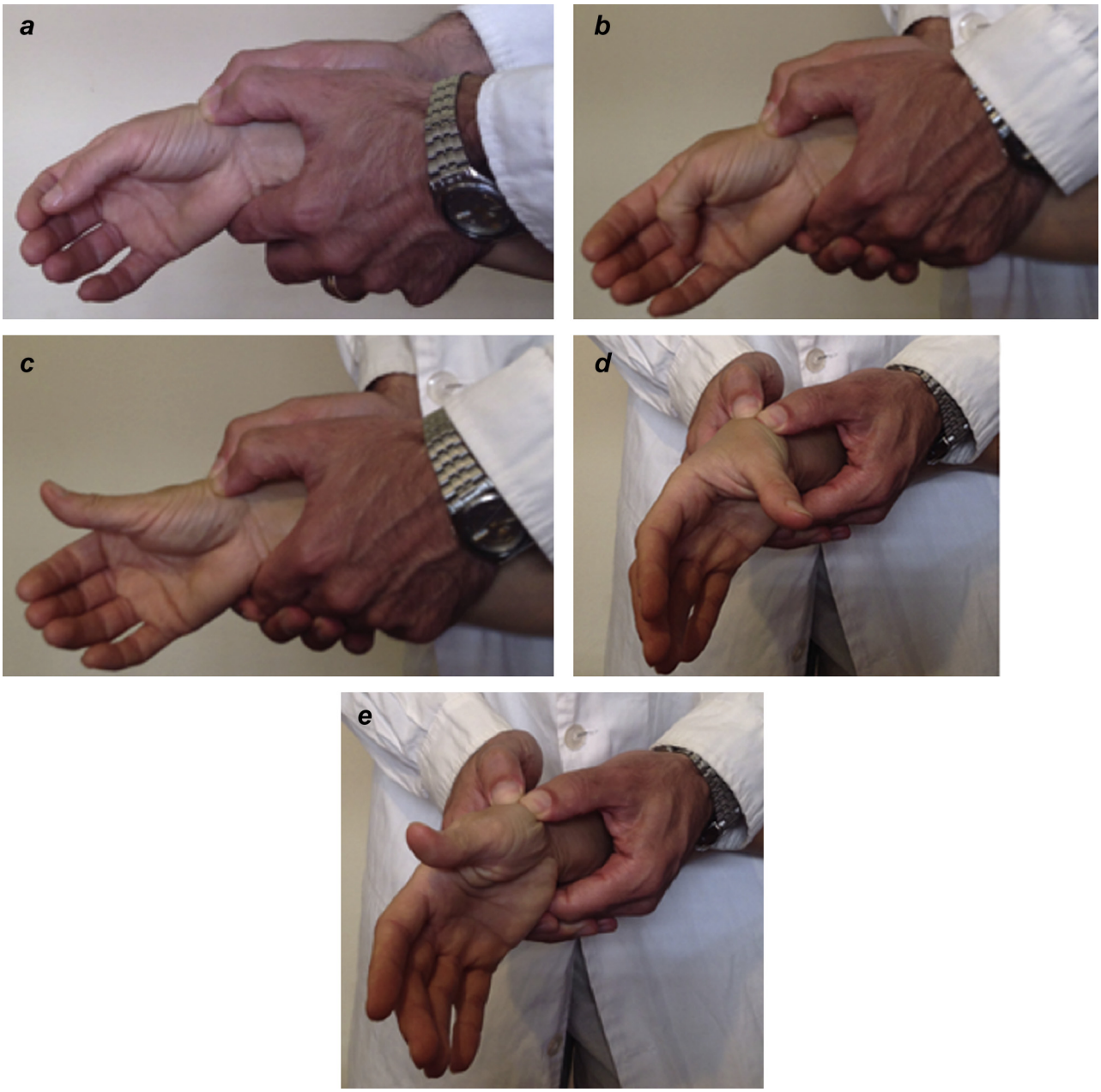

Fig. 1. Mobilization with movement technique.

10 repetitions of each, as long as there is no pain during the application of the technique (Fig. 1b–e).

Taping techniques

1. The inhibitory application uses standard 5 cm blue elastic tape. Depending on the subject's morphology, the length of the tape is determined by measuring the distance between the insertion and the origin of the extensor pollicis longus (with a direction of about 45 from a vertical line).
2. The subject is in a seated position with the shoulder adducted and neutrally rotated, the elbow flexed to 90°, and the forearm and wrist in a neutral position (Fig. 2a).
3. The therapist holds the insertion (I) of the tape, 0% of material tension is applied to the tape maintaining a direction of about 45° toward the origin (O). The tape is gently applied to the skin without inducing any tension (Fig. 2b–d).
4. A second small corrective strip is applied over the snuffbox and parallel to radial nerve (Fig. 2f, g). The goals of application of tape include facilitation of proprioceptive feedback to the involved joint,[15] to assist with circulation, and to diminish nocioceptive input to the nervous system to prolong the effects of manual interventions.[16]

A program of mobilization with movement (MWM) and elastic taping can improve thumb stabilization, decrease pain, and improve function with individuals with CMC OA and the techniques can be added to the hand therapist's "tool box" of efficacious interventions.