

Case Report

# Endogenous bacterial endophthalmitis masquerading as an intraocular tumor



Anna Paola Salvetti<sup>\*</sup>; Marco Pellegrini; Ferdinando Bottoni; Giovanni Staurenghi

## Abstract

A 40-year-old female patient referred for a possible intraocular tumor was found to have an endogenous bacterial endophthalmitis in her right eye. Fundus examination revealed an amelanotic dome shaped choroidal mass and an exudative retinal detachment. Enhanced Depth Imaging-Optical Coherence Tomography (EDI-OCT), fundus autofluorescence (FAF) and ultrasounds were suggestive of a possible choroidal melanoma. A multimodal imaging approach and a thorough anamnesis were instrumental in establishing the correct diagnosis.

**Keywords:** EDI-OCT, Endogenous endophthalmitis, Uveal melanoma, Choroidal granuloma, Intraocular tumor

© 2015 The Authors. Production and hosting by Elsevier B.V. on behalf of Saudi Ophthalmological Society, King Saud University. This is an open access article under the CC BY-NC-ND license (<http://creativecommons.org/licenses/by-nc-nd/4.0/>).  
<http://dx.doi.org/10.1016/j.sjopt.2015.11.003>

## Introduction

Enhanced Depth Imaging-Optical Coherence Tomography (EDI-OCT) is one of the most recent innovations for the visualization of the retina: it allows a deeper and cross-sectional analysis of the retina, choroid and scleral structures.<sup>1</sup> This adaptation has improved visualization of choroidal lesions including tumors and granulomas. Additionally, EDI-OCT can display accurately the effects of choroidal tumors on the overlying retina and the surrounding structures. Most of the EDI-OCT tumors features are so well depicted to allow clinicians making or excluding specific diagnostic hypotheses.<sup>2</sup> Nevertheless many choroidal tumors and granulomas share so many OCT, fundus autofluorescence (FAF) and fundoscopic patterns. Only a correct anamnesis and a multi-imaging approach support the clinician in achieving the correct diagnosis.

## Case report

A 40-year-old Caucasian female with a progressive visual loss in her right eye from 2 weeks was referred to our institution for a possible choroidal mass involving the macula. Previous ocular and systemic medical history was unremarkable. Upon referral, visual acuity was 20/125 in the right eye and 20/20 in the left eye and intraocular pressure was 16 mmHg bilaterally. No inflammatory cells were present in the either anterior or posterior chamber. Conjunctiva and sclera were quiet. Indirect ophthalmoscopy of the right eye showed an amelanotic, dome shaped lesion with a localized exudative retinal detachment in the macular area and no evidence of optic nerve edema or inflammation (Fig. 1A).

Enhanced Depth Imaging-Optical Coherence Tomography (EDI-OCT) and fundus autofluorescence (FAF) imaging were performed using a confocal scanning laser ophthalmoscope

Received 11 March 2014; received in revised form 19 May 2015; accepted 10 November 2015; available online 23 November 2015.

Eye Clinic, Department of Clinical Science "Luigi Sacco", Sacco Hospital, University of Milan, Italy

<sup>\*</sup> Corresponding author at: Eye Clinic, Department of Clinical Science "Luigi Sacco", Sacco Hospital, University of Milan, via G.B. Grassi 74, 20100 Milano, Italy. Tel.: +39 3397473737.

e-mail address: [paola.anna.salvetti@gmail.com](mailto:paola.anna.salvetti@gmail.com) (A.P. Salvetti).

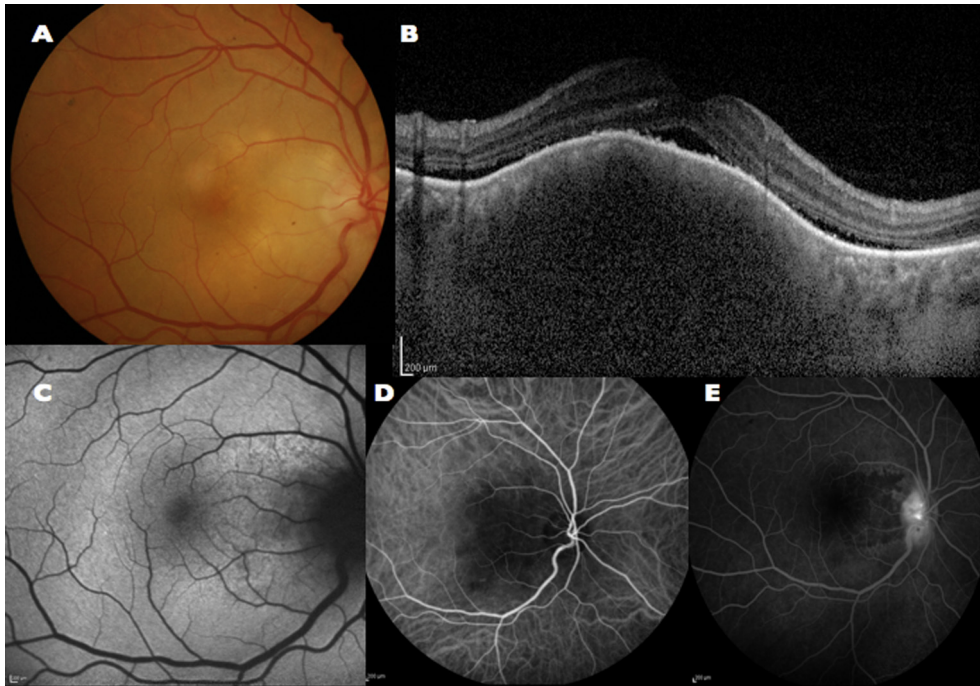


Peer review under responsibility of Saudi Ophthalmological Society, King Saud University



Production and hosting by Elsevier

Access this article online:  
[www.saudiophthaljournal.com](http://www.saudiophthaljournal.com)  
[www.sciencedirect.com](http://www.sciencedirect.com)



**Figure 1.** Baseline visit. (A) Fundus photography showing a yellow choroidal mass with imperceptible margins. (B) Enhanced Depth Imaging-Optical Coherence Tomography (EDI-OCT) displaying a choroidal mass with inward compression of the choroidal vascular structures, a smooth dome shaped appearance of the retina, subretinal fluid and no visible retinal infiltration. The mass shadowing precludes identification of the sclerochoroidal interface. (C) Fundus Autofluorescence (FAF) imaging showing a granular pattern with areas of hypo and hyper autofluorescence. (D–E) Indocyanine green and fluorescein angiography examinations (ICG and FA) confirming the presence of a choroidal mass obscuring the choroidal vascular network with no intrinsic vascularization. (D) FA confirmed non-perfusion of the choriocapillaris in the macular area and displayed late optic disk hyperfluorescence (E).

(HRA+OCT Spectralis, Heidelberg Engineering GmbH, Heidelberg, Germany). EDI-OCT examination of her right eye confirmed the presence of a choroidal mass with smooth dome-shaped surface and inward compression of the choroidal vascular structures (Fig. 1B). The overlying retina had no visible intraretinal infiltration. A serous retinal detachment and scattered retinal pigment epithelium (RPE) irregularities could be identified over the lesion. The choroidal infiltrate was unifocal with an intense shadowing precluding the identification of the sclerochoroidal interface.

FAF showed a granular pattern with irregular areas of hyper and hypo-fluorescence likely indicating a greater metabolic activity of the RPE cells occurring before cells death<sup>3</sup> (Fig. 1C). A and B-scan ultrasonography showed a dome shaped choroidal lesion acoustically hollow due to low-medium internal reflectivity.

On the basis of these imaging characteristics main differential diagnosis included a possible neoplastic etiology (amelanotic choroidal melanomas, choroidal metastasis, choroidal hemangiomas or choroidal lymphomas) or a granuloma.

EDI-OCT exam was instrumental in achieving the correct diagnosis. EDI-OCT in choroidal hemangiomas typically shows a diffuse choroidal thickening whereas our patient displays significant compression of the inner and outer choroid with no compression of the choriocapillaris. Moreover at fundus examination the lesion was yellow in color and characterized by imperceptible margins (Fig. 1A) whereas choroidal hemangiomas are typically orange or red with more defined boundaries.<sup>4</sup> The inner surface of the mass appeared smooth in its shape in contrast to the placid, rippled or seasick pattern of choroidal lymphomas<sup>5</sup> and the “lumpy-bumpy” appearance of choroidal metastasis.<sup>6</sup> Moreover choroidal

lymphomas are sometimes associated with ocular adnexal disease and patients tend to be older. Metastasis is often bilateral and multifocal and the patient often has a known history of primary malignancy.

Ultrasonography is helpful in differentiating this diagnosis with higher internal echogenicity such as choroidal hemangiomas compared to choroidal melanomas.

Fluorescein angiography (FA) and indocyanine green angiography (ICG) were contributory to rule out the hypothesis of a neoplastic etiology. ICG, in particular depicted a mass obscuring the choroidal vascular network with no intrinsic vascularization (Fig. 1D). FA showed no perfusion of the choriocapillaris likely due to a compression by the lesion itself and optic disk hyperfluorescence in late phases of the exam (Fig. 1E). No staining or pinpoint leakage at the level of the retinal pigment epithelium (RPE) was observed.<sup>7</sup>

A more comprehensive medical history was collected, revealing a dental extraction performed 10 days before the onset of symptoms, with subsequent fever and a moderate enlargement of the latero-cervical lymph nodes.

On the basis of the anamnesis and clinical features a diagnosis of stage 1 endogenous bacterial endophthalmitis with focal chorioretinal infiltration and no extension into the vitreous cavity<sup>8</sup> was made.

In agreement with our Infectious Diseases Department we immediately started an empirical aggressive treatment with Amoxicillin/Clavulanate 875 mg/125 mg 3 times/day for 10 days. Meanwhile, a complete blood workup, electrophoresis, study of erythrocyte sedimentation rate (ESR), C-reactive protein (CRP), antinuclear antibodies (ANA), extractable nuclear antigens (ENA), DNA antibody (anti-dsDNA),

Download English Version:

<https://daneshyari.com/en/article/2700639>

Download Persian Version:

<https://daneshyari.com/article/2700639>

[Daneshyari.com](https://daneshyari.com)