

Case Report

Good visual outcome in an immunocompromised patient with bilateral acute retinal necrosis syndrome A case report



Ricardo E. Marrocos de Aragão, PhD*; Ieda M.A. Barreira, MD; Barbara L.A. Arrais, MD; Leidiane A. Pereira, MD; Carine S. Ramos, MD

Abstract

Acute retinal necrosis (ARN) is an uncommon necrotizing, fulminant retinopathy caused by the *herpes simplex virus* types 1 or 2 or by the *varicella zoster virus* with visually devastating consequences. Generally it occurs in patients who are systemically healthy, but occasionally occurs in immunocompromised host. We report a case of bilateral ARN in a patient with AIDS with a good final visual outcome.

Keywords: Acquired immunodeficiency syndrome, Herpes simplex, Retinal necrosis syndrome, Acute, Retinal detachment, Uveitis

© 2013 Saudi Ophthalmological Society, King Saud University. Production and hosting by Elsevier B.V. All rights reserved.
<http://dx.doi.org/10.1016/j.sjopt.2013.11.005>

Introduction

Acute retinal necrosis (ARN) syndrome is an uncommon but devastating potentially blinding necrotizing retinitis. Characteristically presents as a peripheral retinal vasculitis. It can affect one or both eyes. It is observed most commonly in healthy patient but occasionally occurs in immunocompromised host.^{1,2} Most, if not all, cases of ARN syndrome are caused by infection with a member of the herpes virus family, usually *varicella zoster virus* (VZV) or *herpes simplex virus* (HSV) type 1 and more rarely by HSV-2 or *cytomegalovirus* (CMV).³

The disease is characterized by anterior uveitis, vitritis and patchy or confluent areas of white- or cream-colored areas of necrotizing retinitis that rapidly extend posteriorly from the peripheral retina. Retinal atrophy resulting from necrosis often leads to secondary rhegmatogenous retinal detachment (RD). Occlusive vasculitis involves the retinal and choroidal vasculature.⁴

Current treatment trends vary widely, including single agents or combination of oral, intravenous, and intravitreal agents. Differing strategies do not affect outcomes. The final visual acuity in ARN is generally poor. RD is common and can neither be predicted nor prevented.

Case report

A 30-year-old white male, previously immunocompromised with AIDS, presented with a 3-week history with blurred vision, floaters and decreased peripheral vision in both eyes. He has been under treatment for AIDS for 10 years. His medications included abacavir, lamivudina, lopinavir, ritonavir, itraconazole and ganciclovir. His CD4 cell count was 66/mm³ and viral load was 75.589/mm³.

On examination, the patient's best visual acuity (BVA) was 20/50 OU. The intraocular pressure was 14 mmHg and 15 mmHg in the right and left eye, respectively. Fine keratic precipitates, trace anterior chamber cells, 1+ anterior

Received 22 June 2013; received in revised form 12 October 2013; accepted 8 November 2013; available online 18 November 2013.

Universidade Federal do Ceará, Rua Porfirio Sampaio 1905, Rodolfo Teofilo, Fortaleza, CE CEP 60430-540, Brazil

* Corresponding author. Address: Rua Osvaldo Cruz, 2335 Bairro Dionísio Torres, Fortaleza, CE CEP 60125-151, Brazil. Tel.: +55 85 91379313.
e-mail address: ricardomarrocos@yahoo.com (R.E. Marrocos de Aragão).
URL: <http://www.huwc.ufc.br> (R.E. Marrocos de Aragão).



Peer review under responsibility of Saudi Ophthalmological Society, King Saud University



Production and hosting by Elsevier

Access this article online:
www.saudiophthaljournal.com
www.sciencedirect.com

vitreous cells was present in both eyes. Dilated fundus examination showed retinal arteriolar sheathings in all quadrants, extensive areas of whitening and retinal necrosis involving the retina periphery in both eyes (Fig. 1). A diagnosis of bilateral ARN was made, the ganciclovir was changed for intravenous aciclovir for 10 days, and he was prescribed topical corticosteroids and atropina. One week after the initial presentation prophylactic laser retinopexy was performed, completely demarcating involved areas in both eyes (Fig. 2). In the next two weeks, there was a dramatic resolution of retinal necrosis resulting in areas of retinal atrophy, his BVA has improved to 20/30 OU. Patient returned one week later with complaint about his vision, his BVA was 20/100 in the right eye and 20/80 in the left eye. On fundus examination retinal detachment with macula involvement was noted in both eyes. The patient underwent pars plana vitrectomy, endolaser treatment, and silicone oil tamponade. The left eye had a redetachment, which was surgically repaired in the same way two weeks later (Fig. 3).

After two months of the initial presentation his BVA was 20/30 in the right eye and 20/200 in the left. His medication was changed to oral aciclovir 800 mg 5 times daily for 14 weeks. 5 months after the last vitrectomy vision in both eyes remains stable.

Discussion

Acute retinal necrosis syndrome is an infectious uveitis usually caused by HSV-1 or -2 or VZV. Features of ARN syndrome include a vaso occlusive angiitis of both retinal and choroidal vessels, a necrotizing retinitis that

preferentially involves the peripheral retina, and significant intraocular inflammation. Rhegmatogenous retinal detachment is a major late sequela. Urayama et al. first described ARN syndrome in 1971.⁴ It has a bimodal age distribution peaking at approximately 20 and 50 years of age. There is no clear racial association.⁶ Although the syndrome was initially described in healthy patients, it subsequently has been reported in individuals with compromised systemic immunity, most notably in those with human immunodeficiency virus (HIV) infection.⁷ The ARN syndrome was seen at any level of HIV infection.⁸ The ARN syndrome can be insidious or present with floaters, blurred vision, or rarely decreased peripheral vision. External examination may reveal diffused episcleritis, scleritis, or orbital inflammatory disease. Mild to moderate anterior segment cellular reaction is common. ARN syndrome is characterized by a retinal vasculitis affecting both the arteries and veins in the fundus, which is manifested by sheathing of the major vessel. Peripheral retinal whitening is typically present, and the entire peripheral retina may be involved. Vitritis and optic disk swelling either hyperemic or pallid, are common features of the ARN syndrome. The retinitis may not progress posteriorly to the vascular arcades, sparing the macula and central vision. Without treatment, the inflammatory component of ARN syndrome typically burns out, leaving behind a thin atrophic retina with pigmentary changes. Rhegmatogenous retinal detachment is a major cause of visual loss and occurs in 50–75% of cases. Vitreous traction and proliferative vitreoretinopathy are complicating factors.⁷

The diagnosis of ARN syndrome is based on a clinical examination and a characteristic fundoscopic appearance.

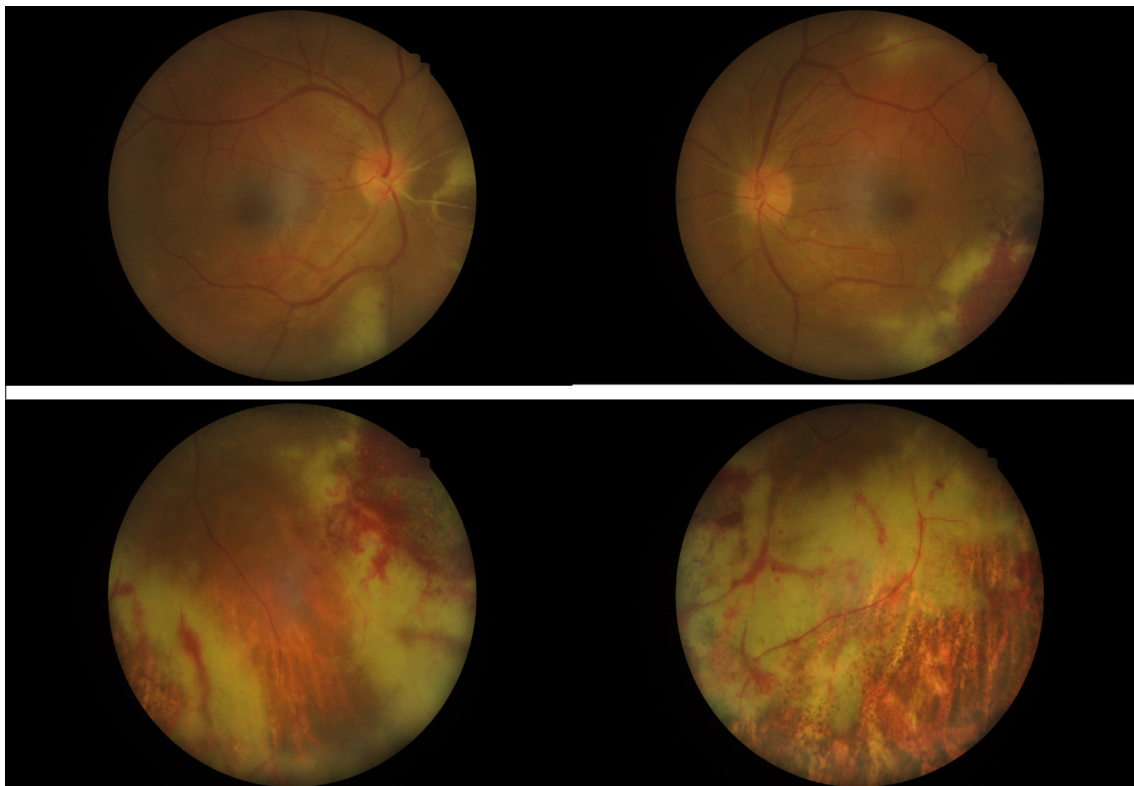


Figure 1. The arteriolar sheathings in all four quadrants, extensive areas of whitening and retinal necrosis involving the retina periphery for 360° in both eyes.

Download English Version:

<https://daneshyari.com/en/article/2700662>

Download Persian Version:

<https://daneshyari.com/article/2700662>

[Daneshyari.com](https://daneshyari.com)