The Journal of Foot & Ankle Surgery 55 (2016) 877–880

Contents lists available at ScienceDirect

The Journal of Foot & Ankle Surgery

journal homepage: www.jfas.org

Tips, Quips, and Pearls

"Tips, Quips, and Pearls" is a special section in The Journal of Foot & Ankle Surgery®, *which is devoted to the sharing of ideas to make the practice of foot and ankle surgery easier. We invite our readers to share ideas with us in the form of special tips regarding diagnostic or surgical procedures, new devices or modifications of devices for making a surgical procedure a little bit easier, or virtually any other "pearl" that the reader believes will assist the foot and ankle surgeon in providing better care.*

Femoral Head Allograft for First Metatarsal Phalangeal Joint Fusion Using a Reamer Technique to Limit Graft Length

Matt McCammon, DPM [1], Thomas A. Brosky II, DPM, FACFAS [2], Sofie L. Pinney, DPM, AACFAS [3]

[1] *Chief Resident Physician, Dekalb Medical, Decatur, GA*
[2] *Attending Physician, Dekalb Medical, Oakwood, GA*
[3] *Fellow, The Southeast Permanente Foot and Ankle Trauma and Reconstructive Surgical Fellowship, Atlanta, GA*

ARTICLE INFO

Keywords:
allograft
arthrodesis
bone
interpositional
surgery

ABSTRACT

The use of interpositional bone grafting for arthrodesis of the first metatarsophalangeal joint can be a technically challenging procedure. A fresh-frozen femoral head allograft can provide an appropriate graft for lengthening and ultimate fusion. It has been well-documented in published studies that larger grafts at this site increase the risk of complications. When the joint is resected in a "square" fashion, length is actually lost from the first metatarsal head. We present a technique using a reamer applied to 1 side of the graft and the first metatarsal head in a "cup-and-cone" fashion, thereby limiting the total length of the actual graft size. This technique allows for easy positioning and lengthening, increasing the chance of graft incorporation at the fusion sites.

© 2016 by the American College of Foot and Ankle Surgeons. All rights reserved.

Degenerative joint disease of the first metatarsophalangeal joint (MTPJ) is a common cause of pain and deformity in all population groups. Arthrodesis remains a definitive procedure for chronic pain and deformity of the first MTPJ after failed conservative and surgical treatment. When a bone deficit of the first ray is noted, bone grafting is often needed to restore the length and normal parabola to balance the forefoot. Interpositional bone grafting of the first MTPJ generally consists of an autograft or allograft to restore the length. The published data support the use of both autograft and allograft techniques for structural defects about the first MTPJ (1). Interpositional bone grafts can provide both the structural support and the lengthening needed for a proper arthrodesis technique. Traditionally, end-to-end resection is performed, and a "square" interpositional graft is then inserted. It is also possible to fashion the graft using conical reamers. However, the senior author (T.A.B.) believes that reaming both ends of the graft, especially the proximal phalanx side, is technically challenging and not as stable as a "square" configuration distally. Also, by reaming the base of the proximal phalanx, length is lost and the fixation application could be limited (Fig. 1). We present a technique using conical reamers, thereby limiting the amount of overall length needed at the graft site.

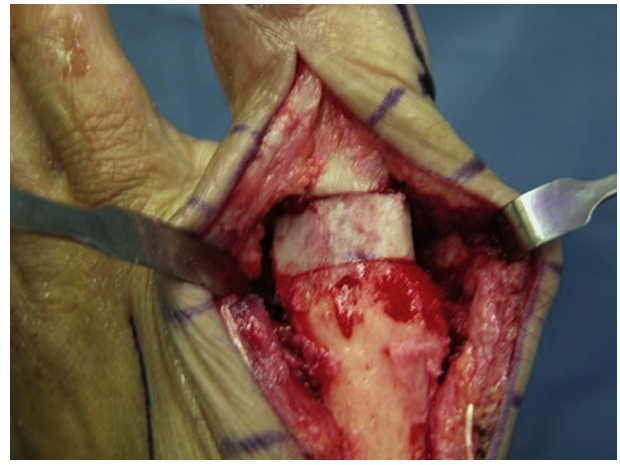

Fig. 1. Traditional structural graft.

Financial Disclosure: None reported.
Conflict of Interest: None reported.
Address correspondence to: Matt McCammon, DPM, Dekalb Medical, 2701 North Decatur Road, Decatur, GA 30033.
E-mail address: mccammondpm@gmail.com (M. McCammon).

1067-2516/$ - see front matter © 2016 by the American College of Foot and Ankle Surgeons. All rights reserved.
http://dx.doi.org/10.1053/j.jfas.2015.12.014

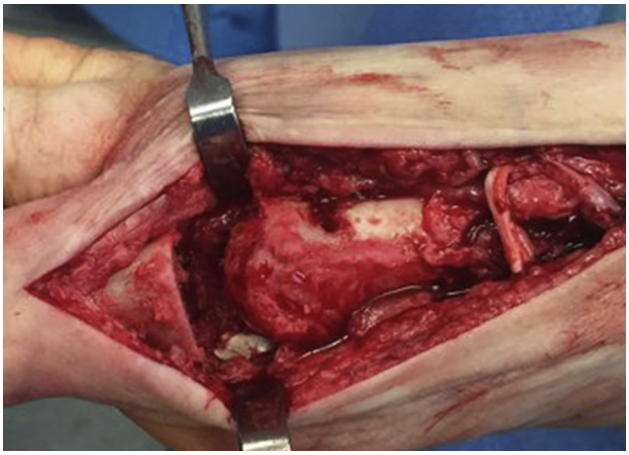

Fig. 2. The prepared fusion site with removal of the subchondral plate and fenestration exposing good bleeding cancellous bone.

Fig. 4. The graft is marked to the appropriate size.

Surgical Technique

The application of structural grafts to the first MTPJ for arthrodesis requires appropriate preoperative planning. Considerations should include both the clinical and the radiographic evaluation findings. Radiographic evaluation alone should never be used as the sole determination for the use of interpositional bone grafting. The physician performing the clinical examination should also consider any lesser MTPJ pathology, including metatarsalgia, capsulitis, and digital deformity. Of particular importance is the presence of second MTPJ capsulitis or predislocation syndrome. The radiographic evaluation should determine the first ray length, metatarsal parabola, and the presence of degenerative changes. It is also important to recognize that not all first MTPJ fusions will need the addition of interpositional bone grafting. Occasionally, intraoperative debridement of the first MTPJ will lead to a length deficit, and a structural graft will be needed to obtain the normal length pattern to balance the forefoot.

Once the determination has been made for first MTPJ arthrodesis with an interpositional allograft, attention should be directed toward proper joint exposure. We prefer manual resection of the degenerative cartilage to the first metatarsal head and the base of the proximal phalanx using a bone rongeur and curette, respectively. A reamer is then used to remove the subchondral plate of the first metatarsal head and shape it into a round shape. The base of the proximal phalanx is resected with a sagittal saw to create a "square," thereby removing the subchondral plate. The base is then fenestrated to expose good bleeding cancellous bone (Fig. 2).

Attention is then directed toward shaping the femoral head allograft. The fresh-frozen femoral head allograft is first prepared by thawing in normal saline for approximately 15 minutes. Using a ruler, the allograft size can be determined from the bone deficit remaining after joint exposure and preparation. A Kirschner wire (K-wire) is driven into the allograft. This serves as a guide for the conical reamer (Fig. 3). The allograft is then reamed with the concave reamer, which creates a "cup" appearance. The surrounding edges are marked, and the K-wire is left within the graft to be used as a guide for the sagittal saw cuts (Fig. 4). This allows for creation of a "square" graft. Once each side has been cut into the graft, a final cut is made at the far end of the graft. The final graft will include a "square" side and a "cup" side (Fig. 5).

A 0.062-in. K-wire is then placed retrogradely through the base of the proximal phalanx and out the tip of the hallux. The formed allograft is then placed into the fusion site, and a flat plate is then

Fig. 3. Reaming of the femoral head graft.

Fig. 5. The graft is cut to the correct length needed.

Download English Version:

https://daneshyari.com/en/article/2712864

Download Persian Version:

https://daneshyari.com/article/2712864

Daneshyari.com