The Journal of Foot & Ankle Surgery 55 (2016) 310–313

Contents lists available at ScienceDirect

The Journal of Foot & Ankle Surgery

journal homepage: www.jfas.org

Avulsion Fracture of the Calcaneus Treated With a Soft Anchor Bridge and Lag Screw Technique: A Report of Two Cases

Kazushige Yoshida, MD [1], Kentaro Kasama, MD [2], Tsutomu Akahane, MD [3]

[1] Orthopedist, Department of Orthopedic Surgery, Shinshu Ueda Medical Center, Ueda City, Nagano, Japan
[2] Orthopedist, Shinonoi General Hospital, Nagano City, Nagano, Japan
[3] Orthopedist, Shinshu Ueda Medical Center, Ueda City, Nagano, Japan

ARTICLE INFO

Level of Clinical Evidence: 4

Keywords:
anchor suture
calcaneal tuberosity
calcaneus
fracture
open reduction internal fixation

ABSTRACT

The displaced extra-articular avulsion fracture of the calcaneus has been classified as a Böhler type 1c calcaneal fracture, and most cases will require surgical repair. In the present report, we describe 2 patients in whom we performed the soft anchor bridge technique using single loaded suture anchors with lag screws for the repair of Böhler type 1c avulsion fractures of the calcaneus. In one of these patients, clinically relevant osteoporosis complicated the injury. In both cases, bone union was achieved, and by 1.5 months after surgery satisfactory recovery was observed. To our knowledge, the soft anchor bridge technique was first used for the treatment of rotator cuff tears, and the greatest merit of this technique is the ability to generate vertical compression force to the pulled out rotator cuff through the use of knotting sutures. In recent years, the soft anchor bridge technique using 4 suture anchors has also been used for fractures of the greater tuberosity of the humerus, an injury that poses operative difficulties similar to those encountered with an avulsion fracture of the calcaneus owing to the traction force of the rotator cuff and relative weakness of adjacent bone. The outcomes of our patients suggest that the soft anchor bridge technique combined with adjunct lag screws is useful in the fixation of avulsion fractures of the calcaneus. In addition, the result in the elderly patient indicates the possibility of using this technique for patients with osteoporosis.

© 2016 by the American College of Foot and Ankle Surgeons. All rights reserved.

Avulsion fracture of the calcaneus is a relatively rare injury that accounts for approximately 3% of all calcaneal fractures (1). This fracture occurs more frequently in patients with osteoporosis, diabetes mellitus, and autoimmune disorders (2,3). Classification of this fracture has usually been based on the classification system proposed by Böhler (4) in 1931, or, more commonly currently, the classification system proposed by Beavis et al (5) in 2008. The simple (non-comminuted), extra-articular avulsion fracture with displacement has been classified as a Böhler type 1c or Beavis type 1 calcaneal fracture, and most cases will require surgery to satisfactorily realign the fragment and maintain stability during the healing phase. Although operative techniques using various fixators such as lag screws (1), soft wires (1,2), anchor devices (6), locking plates (3), and Ilizarov external fixators have been reported (7), limitations exist regarding the use of any of these forms of fixation. In the present report, we have described our use of the soft tissue anchor (JuggerKnot™ Biomet, Inc., Warsaw, IN), composed of no. 5 polyester suture and loaded with a MaxBraid™ (Biomet, Inc.) suture and technique of open reduction internal fixation using single loaded suture anchors with concomitant lag screw fixation for 2 cases of Böhler type 1c avulsion fracture of the calcaneus with satisfactory results.

Case Reports

Two female patients diagnosed with avulsion fracture of the calcaneus caused by minor trauma were treated. To perform the procedure, general anesthesia was used, with the patient in the prone position. The calcaneus was exposed using a direct dorsal approach after exsanguinating the extremity and elevating a thigh tourniquet for hemostasis. After identifying the avulsed bone fragment and Achilles tendon, the surface of the bone adjacent to the avulsed fragment was exposed using a periosteal elevator. Two proximal row anchors (JuggerKnot™, 1.4 mm, Biomet, Inc.) were inserted 5 mm proximal to the proximal edge of the avulsion fracture line just anterior to the Achilles tendon. The anchors were placed 2 cm apart. The avulsion bone fragment attached to the Achilles tendon was then restored to its original, anatomic position and temporarily stabilized using a Kirschner wire and bone clamp.

Financial Disclosure: None reported.
Conflict of Interest: None reported.
Address correspondence to: Kazushige Yoshida, MD, Department of Orthopedic Surgery, Shinshu Ueda Medical Center, 1-27-21 Midorigaoka, Ueda City, Nagano 386-0022 Japan.
E-mail address: kyoshida-sin@umin.ac.jp (K. Yoshida).

1067-2516/$ - see front matter © 2016 by the American College of Foot and Ankle Surgeons. All rights reserved.
http://dx.doi.org/10.1053/j.jfas.2014.09.038

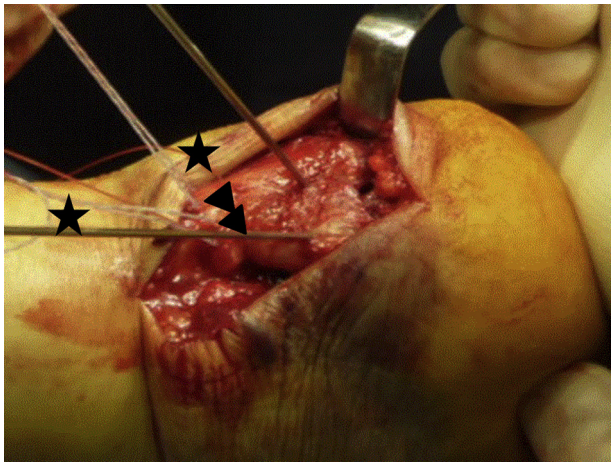

Fig. 1. Avulsed fragment fixed by Kirschner wires were the center of this figure. The *arrowheads* show the inserted proximal-row anchors. The *stars* show the sutures of the proximal anchors passed into the Achilles tendon.

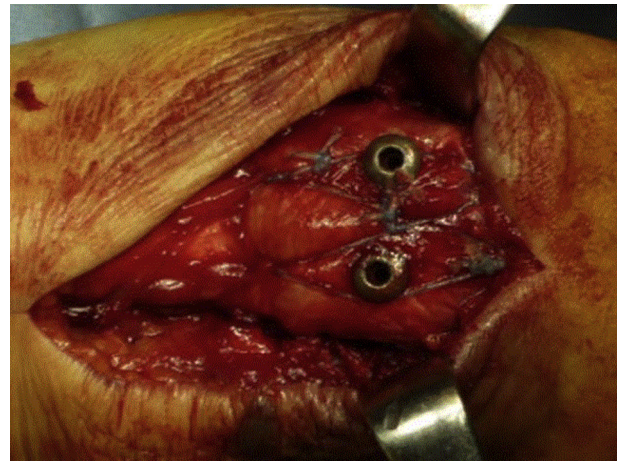

Fig. 3. The sutures were tied, and the vertical force generated by the soft anchor bridge compressed the fragment.

To fix the bone fragment to the proximal anchors, the sutures of the proximal anchors were passed into the Achilles tendon just proximal to its insertion (Fig. 1) and tied, each suture to itself. Two single loaded distal row soft anchors were then inserted directly in line with the medial anchors and 5 mm distal to the distal edge of the avulsed bone fragment (Fig. 2). In addition to the soft anchor bridge, the fixation was reinforced with two lag screws inserted through the avulsion fragment in order to increase interfragmental compression and to resist shear and rotational forces. Because of the possibility of suture cutting by drilling for the lag screw, lag screws were inserted before the suture bind. Subsequently, the sutures of the diagonal anchors were tied together, and the suture of the proximal anchor was tied to one of the neighboring distal row anchors to bridge the avulsed fragment and secure it with vertical compression force generated by the plane of knotting sutures (Fig. 3).

Case 1

A 55-year-old female presented to us with an injury to her right heel after planting her foot hard on the ground while playing volleyball. She was unable to walk unaided because of heel pain. She was not taking any medications and had no allergies. She had family history and no surgical history. On physical examination, swelling and subcutaneous bleeding were observed at the posterior aspect of her heel, and the result of the Thompson-Simmonds test (8,9) was positive. Radiographs showed a Böhler type 1c avulsion fracture of the calcaneus (Fig. 4). The patient was splinted in a below-the-knee brace and maintained non-weightbearing on her injured right heel with the use of crutches. Operative fixation, as described, was performed 5 days after the injury. The bone quality was deemed good, but 2 lag screws were inserted in order to increase interfragmental compression and to resist shear and rotational forces (Fig. 5). The patient was not permitted to bear weight on the operated extremity for the first 4 postoperative weeks, using a plaster splint and crutches for ambulation. Thereafter, partial weightbearing was started with use of a short leg brace that makes it possible for the patient to bear weight with the ankle being kept in plantarflexion. Bone union was achieved without complications. By 1.5 months postoperatively surgery, she had made a good recovery with resumption of her normal activities without pain. The patient was followed up from June 2013 to April 2014 (10 months) and progressed well.

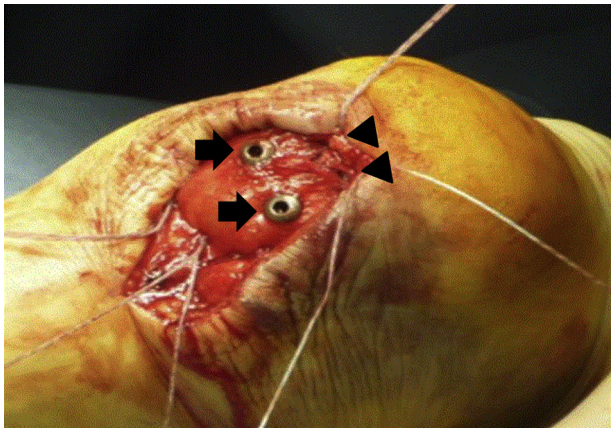

Fig. 2. The *arrows* show inserted lag screws. The *arrowheads* show distal-row anchors. The suture loaded with proximal-row anchor is tied with Achilles tendon.

Fig. 4. The preoperative radiograph of case 1.

Download English Version:

https://daneshyari.com/en/article/2712900

Download Persian Version:

https://daneshyari.com/article/2712900

Daneshyari.com