

# Operative Outcomes with Myxomatous Mitral Valve Repair: Experience with 586 Patients



L. Bassin, FRACS, PhD <sup>a\*</sup>, B. Weiss, FRACS <sup>b,d</sup>, G. Cranney, FRACP <sup>c</sup>,  
D. Gimpel, MBBS <sup>d</sup>, P. Gilhooly, MBBS <sup>d</sup>, R. Smith, MBBS <sup>d</sup>,  
Z. Akhunji, FRACS <sup>b</sup>, P. Grant, FRACS <sup>b</sup>, H. Wolfenden, FRACS <sup>b</sup>

<sup>a</sup>Division of Cardiac Surgery, Brigham and Women's Hospital, Harvard Medical School, Boston, MA, USA

<sup>b</sup>Department of Cardiothoracic Surgery, The Prince of Wales Hospital, Sydney, NSW, Australia

<sup>c</sup>Department of Cardiology, The Prince of Wales Hospital, Sydney, NSW, Australia

<sup>d</sup>School of Medicine, University of Notre Dame Sydney, Sydney, NSW, Australia

Received 7 November 2015; accepted 5 February 2016; online published-ahead-of-print 9 March 2016

## Introduction

American Heart Association (AHA) guidelines recommend mitral valve repair for myxomatous mitral regurgitation whenever possible to prevent LV dysfunction and early mortality. Here we review our early operative outcomes with mitral valve repair for myxomatous mitral regurgitation.

## Methods

We collected data from 586 consecutive patients that underwent mitral repair for myxomatous disease at the Prince Henry and Prince of Wales Hospitals Sydney between 1997 and 2012. All patients had pre- and postoperative transthoracic echocardiograms.

## Results

In the first 30 days postoperatively there were five deaths (0.9%), four strokes (0.7%) and five transient ischaemic attacks (TIAs) (0.9%). Repair involved resection in 55.5%, neochordal reconstruction in 41.6%, and in 2.9% a combination of both. There was increasing use of neochordae since 2006. At discharge 99% had mitral regurgitation (MR)  $\leq$  mild and  $\leq$  trivial in 79.5%. For posterior leaflet disease neochordae had improved MR at discharge compared with resection (85% vs 78%,  $P < 0.05$ ). Preoperative tricuspid regurgitation (TR) and pulmonary hypertension  $>$  mild were associated with a greater degree of MR at discharge ( $P < 0.05$ ) for reasons that are unclear.

## Conclusion

We have shown excellent early results for mitral repair with very low operative mortality and excellent freedom from significant MR. Successful mitral repairs with low morbidity have resulted in a pattern of early referral in keeping with the current guidelines.

## Keywords

Mitral valve • Valve repair • Cardiac Surgery

## Introduction

Myxomatous or degenerative mitral valve disease is the leading cause of leaflet prolapse and surgically correctable mitral regurgitation (MR) in the developed world [1,2]. The aetiology of this disease can be acquired, or congenital with inheritable

connective tissues disorders (Marfans, Ehlers-Danlos IV, Osteogenesis Imperfecta). The surgical description of the myxomatous valve describes a continuum of leaflet and chordal disease from Fibroelastic Deficiency, with thin leaflets and chordal rupture, to Barlow's Disease with grossly excessive and large leaflets causing bileaflet prolapse.

\*Corresponding author at: Division of Cardiac Surgery, Brigham and Women's Hospital, Harvard Medical School, 75 Francis St, Boston, MA, USA 02445.

Tel.: +617 834 0054, Email: [levi.bassin@gmail.com](mailto:levi.bassin@gmail.com)

© 2016 Published by Elsevier B.V. on behalf of Australian and New Zealand Society of Cardiac and Thoracic Surgeons (ANZSCTS) and the Cardiac Society of Australia and New Zealand (CSANZ).

Chronic severe MR causes volume overload of the left ventricle (LV) and if uncorrected results in LV dilatation and eventually systolic dysfunction. The regurgitant flow causes left atrial (LA) dilatation, atrial fibrillation (AF), and eventually pulmonary hypertension and right heart failure. If severe MR is left untreated it results in significant morbidity and early mortality [3].

Mitral valve repair techniques were pioneered by Alain Carpentier with a rigid annuloplasty ring in his publication the 'French Correction' [4], as well as the work by Carlos Duran [5]. The fundamental concepts of repair include: thorough valve analysis, leaflet reconstruction, remodelling annuloplasty, and assessment of repair. There are many techniques to correct the prolapsing leaflet, and in the last 10 years there has been a move away from the traditional posterior leaflet resection (quadrangular/slide) to leaflet preservation techniques with Gore-Tex neochordae.

Early referral for surgery has been associated with better outcomes for severe MR. The 2014 American Heart Association recommended mitral surgery for asymptomatic severe MR if the LV ejection fraction (LVEF) is less than 60% or the LV end-systolic diameter (LVESD) is over 40 mm (Class I recommendation) [6].

Mitral valve repair has been performed at the Prince Henry and now Prince of Wales Hospitals since the 1980's, initially by Dr David Newman using techniques pioneered by Carlos Duran. With reliable results obtained from repair, patients were then referred earlier, before the onset of LV dysfunction. The surgical team was supported by a busy echocardiography department, with early use of routine preoperative transoesophageal echocardiography (TOE) to ascertain the aetiology and reparability of the lesion.

We reviewed our early results with mitral valve repair over the last 15 years during the transition from resection to leaflet sparing techniques.

## Methods

Following institutional ethics board approval we conducted a retrospective review of prospectively collected data using the Prince of Wales database, as well as operation reports, and echocardiograms. This review included all patients that underwent mitral valve repair for myxomatous disease at the Prince Henry and Prince of Wales Public and Private Hospitals from January 1997 to March 2012. All patients had a preoperative and pre-discharge transthoracic echocardiogram (TTE).

## Statistics

Results are presented as the mean  $\pm$  standard deviation. Comparison between two groups of non-parametric data was obtained using the Chi-square test. Significance was set at  $P < 0.05$ .

## Results

There were 586 consecutive patients that underwent mitral valve repair for myxomatous degeneration between 1997 and

2012 by five surgeons. Mean age was  $65.9 \pm 12.5$  years and 422 were male (72%). Sternotomy was used in 97.1% and a small right anterior thoracotomy with femoral-femoral bypass in 2.9%. Mean cardiopulmonary bypass (CPB) and aortic cross clamp times were  $121.1 \pm 36.9$  and  $92.6 \pm 0.1$  minutes respectively. For isolated mitral valve surgery, CPB and aortic cross clamp times were  $105.9 \pm 31.5$  and  $82.1 \pm 25.1$  minutes respectively. Concomitant operations performed were: coronary artery bypass grafting (CABG) in 133 (22.7%), aortic valve replacement (AVR) in 30 (5.1%), AF ablation in 78 (13.3%), tricuspid valve repair (TVr) in 44 (7.5%), and mitral annular calcification (MAC) resection in 14 (2.4%). Forty patients (6.8%) had previously undergone cardiac surgery via sternotomy of which 20 (3.4%) had a previous failed mitral valve repair.

Preoperative TOE, as reported by an echocardiologist, identified the prolapse to be isolated to the posterior mitral leaflet (PML) in 69.1%, to the anterior mitral leaflet (AML) in 10.1% and bileaflet prolapse in 20.8%. The leaflet repair involved resection in 55.5%, neochordal reconstruction in 41.6% with some patients having a combination of both leaflet resection and neochords implanted. Figure 1 describes the predominant repair technique for isolated PML disease during the study timeframe with a shift from resection to neochords starting in 2006. In the last three years of the study neochordal reconstruction was the predominant technique. Other repair techniques used included commissural suture in 2% and cleft closure in 2.2%. An annuloplasty alone was used in 5.4% to correct the MR of which 50% were for PML prolapse and 47% for bileaflet prolapse.

Overall, 92.2% of patients had an annuloplasty performed and in the last five years this has reached 99% of all mitral repairs. Partial bands were used in 95.4% of which 87% were flexible and 13% semi-rigid, and complete rings were used in 4.6%. In the last three years there has been a trend towards the use of semi-rigid bands.

## Adverse Outcomes

In the first 30 days postoperatively there were five deaths (0.9%): two had concomitant AVR and one had extensive MAC with debridement and pericardial patch reconstruction. The other two deaths were isolated mitral valve repairs in

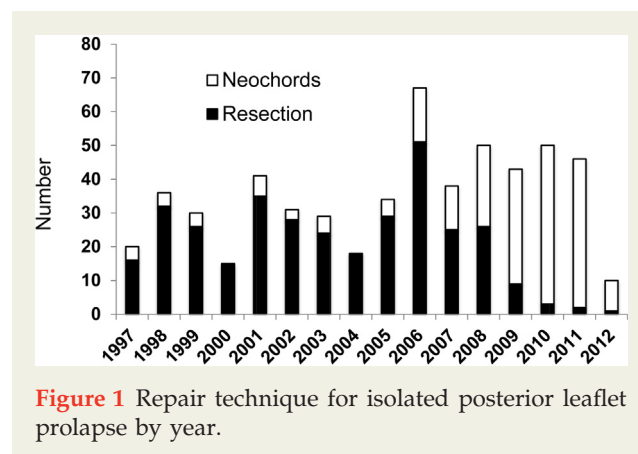


Figure 1 Repair technique for isolated posterior leaflet prolapse by year.

Download English Version:

<https://daneshyari.com/en/article/2916636>

Download Persian Version:

<https://daneshyari.com/article/2916636>

[Daneshyari.com](https://daneshyari.com)