




Contents lists available at ScienceDirect

# Interdisciplinary Neurosurgery: Advanced Techniques and Case Management

journal homepage: [www.inat-journal.com](http://www.inat-journal.com)

## Case report

# Endovascular management of a complex intracranial internal carotid artery dissection in an adolescent



Mohamed Somji, Frederick Adam Zeiler, Patrick Joseph McDonald, Zulfiqar Kaderali

University of Manitoba, Section of Neurosurgery, GB129-820 Sherbrook Street, Health Sciences Centre, Winnipeg, MB R3A 1R9, Canada

## ARTICLE INFO

### Article history:

Received 16 February 2016

Revised 3 April 2016

Accepted 9 April 2016

Available online xxxx

## ABSTRACT

**Background:** Blunt cerebrovascular injury is an important cause of morbidity and mortality following head trauma. Intracranial vessel dissections, carotid-cavernous fistulae, and pseudo-aneurysms are uncommon traumatic vascular lesions with limited evidence to guide endovascular management.

**Case description:** We describe the case of a sixteen year old male patient suffering a traumatic paraclinoidal internal carotid artery (ICA) dissection with carotid-cavernous fistula and ophthalmic artery pseudo-aneurysm. Repeat angiography demonstrated worsening dissection prompting an endovascular parent vessel sacrifice following a passed balloon test occlusion. Relevant imaging is included.

**Conclusions:** Amongst new and developing stenting technologies as well as complex surgical solutions, utilizing a modern endovascular adaptation of simple Hunterian ligation to treat a complex multi-pronged pathology may in some cases represent the best available option. Given the limited published literature, our diagnostic and treatment approach may be informative to clinicians as well as inform an evidence based management approach in similar complex intracranial vascular injuries.

© 2016 Published by Elsevier B.V.

## 1. Introduction

Injuries to the intracranial cerebral vasculature harbor the potential for significant morbidity and mortality secondary to thromboembolism as well as hemorrhage. Potential consequences of blunt cerebrovascular injury include vessel dissection, arteriovenous fistulae, and pseudo-aneurysm formation. ICA dissections and carotid cavernous fistulae are rare events, thought to occur following blunt trauma at a rate of 0.86% [1] and 0.17–0.27% [2] respectively. There is no reliable data on the incidence of pseudo-aneurysm formation however rupture is often catastrophic, with estimates of mortality often greater than 50% [3]. These three types of vessel injuries can be thought of as occurring on the same pathophysiological spectrum. Intimal tears resulting in an intramural hematoma represent a vessel dissection. In the ICA, extension of such tears through the media and adventitia can cause bleeding into the cavernous sinus resulting in the phenomenon of carotid-cavernous fistula. Finally, such a tear extending past the cavernous sinus into the intradural ICA may result in the phenomenon of subarachnoid hemorrhage and injury to branching vessels. A pseudoaneurysm occurs due to trauma disrupting all but the adventitia of the vessel wall, creating a communication between the vessel lumen and a local extraluminal

dilatation referred to as the “pseudoaneurysm”. The occurrence of all of these events simultaneously in a largely asymptomatic patient is extraordinarily rare.

We describe the case of a sixteen year old male patient suffering a post-traumatic internal carotid artery (ICA) dissection with carotid cavernous fistula and ophthalmic artery pseudo-aneurysm. Repeat angiography demonstrated worsening dissection prompting an endovascular vessel sacrifice procedure. Relevant imaging is included. We discuss the evidence regarding the diagnosis, natural history, and treatment of traumatic intracranial ICA dissections. We focus on the available treatment modalities and our rationale for the selection of endovascular parent vessel occlusion in this case.

## 2. Case report

A 16 year old male patient presented to our institution after suffering a head injury as a passenger in a motor vehicle accident. He was awake, alert, and speaking full sentences at admission with a Glasgow Coma Score of 15. His clinical exam revealed right eye blindness, a right relative afferent pupillary defect (RAPD), and significant orbital trauma. An emergent lateral canthotomy was performed which failed to improve his eyesight. A computerized tomography (CT) scan of the head and orbits was performed in order to further assess the bony integrity of the orbits and optic canal. In addition to a depressed right orbital roof fracture, basal subarachnoid hemorrhage (SAH) was noted in the suprasellar cistern with extension bilaterally into the Sylvian fissures (Fig. 1). The pediatric neurosurgery service was consulted for assistance

**Abbreviations:** CCF, carotid cavernous fistula; CT, computerized tomography; CTA, CT angiogram; DSA, digital subtraction angiogram; ICA, internal carotid artery; MRI, magnetic resonance image; RAPD, relative afferent pupillary defect; SAH, subarachnoid hemorrhage.

E-mail address: [somjim3@myumanitoba.ca](mailto:somjim3@myumanitoba.ca) (M. Somji).

with management of his intracranial injury. On examination of the imaging, we noted extensive basal SAH with no convexity SAH or intraventricular hemorrhage. This was felt to represent an unusual pattern of blood in the setting of trauma, and concerning for a traumatic injury to the circle of Willis structures. A contrast based CT angiogram (CTA) was therefore performed in order to assess the cerebral vasculature. No obvious fracture of the optic canal was found on the CT scan.

The CTA demonstrated asymmetry of the cavernous segment of the right internal carotid artery (ICA) in the region of the cavernous sinus (Fig. 2) concerning for possible carotid cavernous fistula (CCF). The patient remained well with a stable neurological exam. In order to better assess the abnormalities of the right ICA noted on the CTA, a diagnostic digital subtraction angiogram (DSA) was performed. The DSA revealed decreased caliber of the right ICA extending from the cavernous segment to just proximal to the anterior choroidal artery. In addition there was contrast opacification of the cavernous sinus with no reflux into cortical veins. We also noted an ophthalmic artery pseudoaneurysm which we suspected was the point of intracranial subarachnoid hemorrhage (Fig. 3). Thus the overall diagnosis was traumatic dissection of the right ICA with an accompanying carotid-cavernous fistula and ophthalmic artery pseudoaneurysm. As the patient was considered clinically stable and with limited immediate treatment options, it was felt reasonable to conservatively manage the patient while we put into place preparations for endovascular treatment of the ICA lesion including options for a balloon test occlusion, a flow diverting or conventional stent procedure, and coiling for an embolization or vessel sacrifice procedure. In the interim a magnetic resonance image (MRI) was ordered to assess for any subclinical evidence of thromboembolism. The MRI demonstrated no diffusion restriction and the patient demonstrated no clinical features of ischemic thromboembolism. Furthermore no compressive hematoma or other mass lesion was found to account for his optic neuropathy.

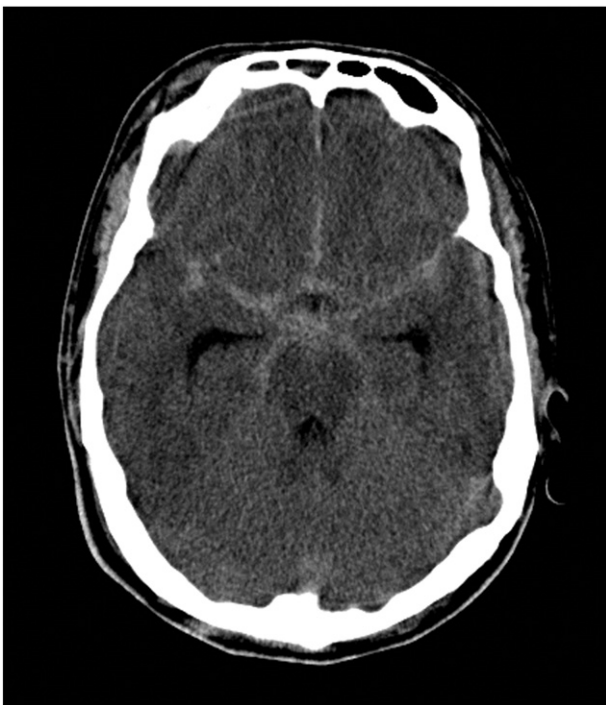The patient was returned to the angiography suite on the sixth day after the injury, where progressive narrowing of the ICA and increasing prominence of the ophthalmic artery pseudoaneurysm was noted (Fig. 4). Our considerations regarding the various modalities of endovascular

treatment are found in the discussion section of this paper. Ultimately we decided that a balloon test occlusion with a view to vessel sacrifice was the optimal modality for a safe and durable solution to the complex lesion described. The patient was placed under conscious sedation while the mean arterial pressure was lowered by approximately 20% for thirty minutes. The patient was monitored clinically for the duration of the hypotensive challenge for any signs of motor or sensory impairment. Likewise speech and level of consciousness were monitored throughout. He remained asymptomatic throughout the balloon test occlusion. Furthermore, angiography suggested adequate collateral circulation through the left anterior communicating artery (Fig. 5). We then utilized a vertebral artery catheter injection to landmark the location of the posterior communicating artery origin from the affected ICA. A balloon catheter was then placed in the affected ICA proximal to the dissection for proximal flow control. Platinum based coils were then used to occlude the right ICA along the length of the dissection, from just proximal to the posterior communicating artery landmark, through to the cavernous segment of the ICA. A post procedural angiogram demonstrated absence of right ICA flow and no further contrast spillover into the cavernous sinus (Fig. 6). The left ICA continued to demonstrate adequate angiographic collateral circulation. Following the procedure the patient remained well with no signs of unilateral cerebral hypoperfusion. An MRI with perfusion based studies also showed symmetrical cerebral perfusion. Postoperatively the patient was started on acetylsalicylic acid therapy at 81 mg daily. At two months follow up the patient remained well with the exception of persistent right eye blindness attributed to a traumatic optic neuropathy.

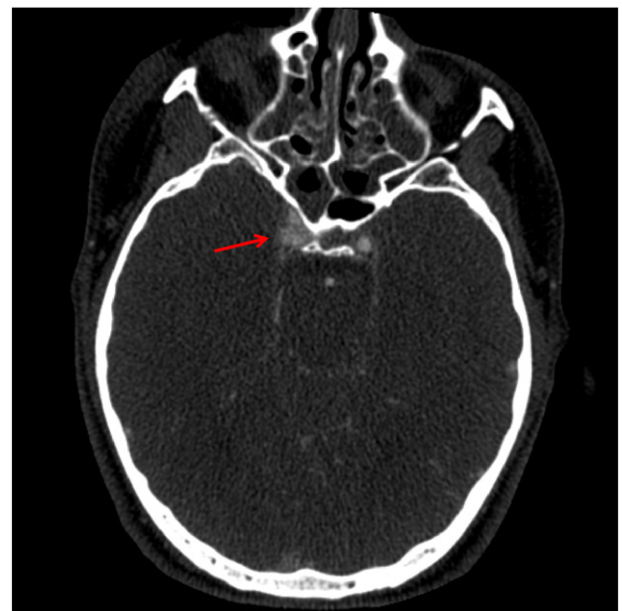
### 3. Discussion

This is an uncommon case of a progressive traumatic intracranial ICA dissection associated with carotid cavernous fistula and ophthalmic artery pseudoaneurysm treated by endovascular parent vessel sacrifice due to contraindications to antiplatelet and anticoagulation therapy, as well as worsening dissection.

The natural history of traumatic ICA dissection is not well understood with no level I and very few level II studies examining outcomes of ICA dissection in the setting of known major trauma. If spontaneous (non-traumatic) vertebral and ICA dissections are used as an



**Fig. 1.** A diffuse pattern of subarachnoid hemorrhage in the context of trauma. Basal cisterns and Sylvian fissures demonstrate hyperdensity with no cortical hemorrhage. This raises the suspicion for injury to proximal intracranial vasculature.



**Fig. 2.** Asymmetry of contrast enhancement in the cavernous segment of the right internal carotid artery (red arrow) suggesting possible carotid-cavernous fistula. (For interpretation of the references to colour in this figure legend, the reader is referred to the web version of this article.)

Download English Version:

<https://daneshyari.com/en/article/3057688>

Download Persian Version:

<https://daneshyari.com/article/3057688>

[Daneshyari.com](https://daneshyari.com)