



Development and evaluation of an automatic tumor segmentation tool: A comparison between automatic, semi-automatic and manual segmentation of mandibular odontogenic cysts and tumors



Majeed Rana ^{a,*}, Daniel Modrow ^b, Jens Keuchel ^b, Christopher Chui ^a, Madiha Rana ^c, Maximilian Wagner ^a, Nils-Claudius Gellrich ^a

^a Department of Craniomaxillofacial Surgery, Hannover Medical School, Hannover, Germany

^b Brainlab AG, Feldkirchen, Germany

^c Department of Differential Psychology and Psychological Assessment, Hamburg, Germany

ARTICLE INFO

Article history:

Paper received 23 November 2014

Accepted 9 December 2014

Available online 20 December 2014

Keywords:

Brainlab

Computer-assisted surgery

Segmentation

Tumor surgery

ABSTRACT

Introduction: In the treatment of cancer in the head and neck region, computer-assisted surgery can be used to estimate location and extent by segmentation of the tumor. This article presents a new tool (Smartbrush), which allows for faster automated segmentation of the tumor.

Methods: This new method was compared with other well-known techniques of segmentation. Thirty-eight patients with keratocystic odontogenic tumors were included in this study. The tumors were segmented using manual segmentation, threshold-based segmentation and segmentation using Smartbrush. All three methods were compared concerning usability, time expenditure and accuracy.

Results: The results suggest that segmentation using Smartbrush is significantly faster with comparable accuracy.

Conclusions: After a period of adjustment to the program, one can comfortably get reliable results that, compared with other methods, are not as dependent on the user's experience. Smartbrush segmentation is a reliable and fast method of segmentation in tumor surgery.

© 2014 European Association for Cranio-Maxillo-Facial Surgery. Published by Elsevier Ltd. All rights reserved.

1. Introduction

Segmentation is one of the main components in computer-assisted surgery (Essig et al., 2011a). The Smartbrush method allows individual segmentation in a shorter time. In its original form the method uses classical region growing mechanisms. This article presents an innovative type of Smartbrush (Smartbrush 2.0, Brainlab AG, Feldkirchen, Germany), which adds automated region of interest determination as well as intelligent 3D-interpolation features to the original Smartbrush. Also, this new Smartbrush

gives the user more control over the segmentation by influencing the final configuration according to the user's experience.

2. Materials and methods

This study was approved by the local ethics committee at the Hannover Medical School, Germany. Different methods of segmentation were compared using 3D data sets of 38 patients with histologically identified keratocystic odontogenic tumors.

2.1. Study inclusion criteria and protocol

Segmentation of certain structures can be performed by different methods. We compared manual segmentation with threshold-based segmentation using the software iPlan (Brainlab AG, Feldkirchen, Germany) as well as with segmentation using the new Smartbrush. These three methods were compared regarding usability, time expenditure and accuracy.

* Corresponding author. Department of Craniomaxillofacial Surgery, Hannover Medical School, Carl-Neuberg-Street 1, D-30625 Hannover, Germany. Tel.: +49 511 5324748; fax: +49 511 5324740.

E-mail address: rana.majeed@mh-hannover.de (M. Rana).

2.2. Manual segmentation

In manual segmentation, the user decides the extent of the desired structure mainly based on the grey scale of MRI scans or the Hounsfield units used in CT scans (Fig. 1). The computer represents the tool to mark the structure's margins. This method is simple from a technical point of view, but segmenting the structures of interest in each slice is very time consuming and thus expensive. In addition, the accuracy of manual segmentation greatly depends on the experience of the user, which results in a high variability of outcomes. Poor contrast, for example, causes difficulty in defining tumor margins and decreases the quality of the segmentation and most importantly the objectiveness of the result. For these reasons, this technique is not commonly used routinely.

2.3. Threshold segmentation

Segmentation can be achieved using a set of Hounsfield units in CT or grey scale in other imaging modalities. To limit segmentation to a certain area, a region of interest (ROI) can be used e.g. by sampling the area that is altered in exposure because of the tumor. After that the ROI can be adapted, so that segmentation is limited to the tumor matching voxels. The main disadvantage of this method is false segmentation of tissue with the same Hounsfield unit or grey scale in the vicinity of the desired object. These false segmentations have to be deleted by hand which is time consuming and error-prone (Fig. 2).

2.4. 3D-Smartbrush

Segmentation with the new Smartbrush is started by marking some points inside the desired area. Within an automatically determined ROI around these points, a region-growing algorithm is performed which computes the final 2D-segmentation.

This method of segmentation can then either be conducted for each slice or by the 3D-interpolation of the program itself. For the

interpolation method the user segments the tumor in one slice, which is ideally as central as possible. After that, segmentation of the desired structure in a plane perpendicular to the segmented slice is performed. The 3D-interpolation automatically detects the three-dimensional ROI and segments the area three-dimensionally with a region-growing algorithm. For final segmentation of the tumor, smoothing is applied to the created object. If necessary, the result of the 3D-interpolation can quickly be adjusted manually. The change to one slice is then interpolated to the complete object to improve the result of the whole segmented structure.

This method can be used not only to segment hard tissue, but also to segment other anatomical regions like the orbit and use this data to plan reconstruction.

Additionally, already segmented structures can be modified using the conventional smart shaper by elastic deformation of the selected object in a selected range (Fig. 3).

2.5. Statistical analysis

The statistical analysis was conducted using SPSS for Windows version 20.0 (SPSS Inc., Chicago, IL, USA). Mean values of 'manual segmentation', 'threshold segmentation' and 'Smartbrush segmentation' were evaluated using a two-sample *t*-test. For all tests, *p* values <0.05 were considered statistically significant.

3. Results

Table 1 summarizes the segmentation times of each method presented. Segmentation with Smartbrush took 4.01 min (SD = 2.16 min), with manual segmentation 6.11 min (SD = 3.12 min) and threshold segmentation 7.31 min (SD = 3.74 min). Segmentation with Smartbrush was significantly faster than manual segmentation ($df = 63$; $t = 2.559$; $p = .013$) and threshold segmentation ($df = 63$; $t = 3.431$; $p = .001$). There was no significant difference between manual segmentation and

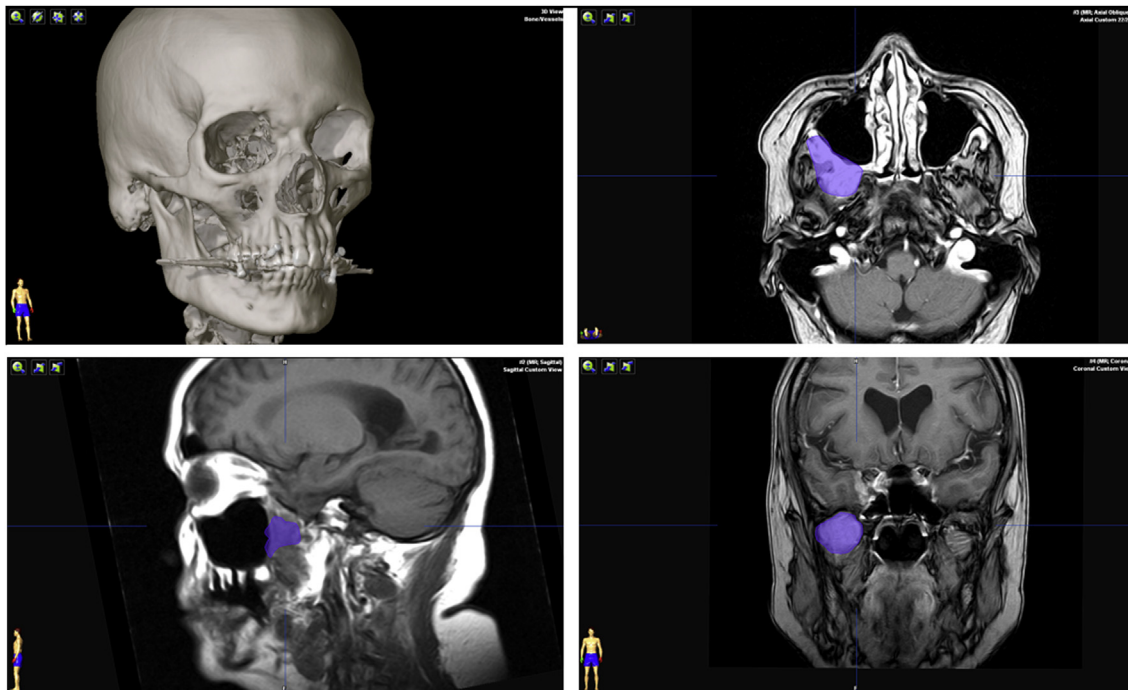


Fig. 1. Multiplanar view after manual segmentation of a tumor in the sphenoid fossa (violet) of the right maxilla (3D, axial, sagittal und coronal).

Download English Version:

<https://daneshyari.com/en/article/3142508>

Download Persian Version:

<https://daneshyari.com/article/3142508>

[Daneshyari.com](https://daneshyari.com)