

# Mandibular Canal Location: Cone-beam Computed Tomography Examination

Tyler Koivisto, DDS,\* Daphne Chiona, DDS, MS,<sup>†</sup> Laura L. Milroy, DDS, MS,<sup>‡</sup> Scott B. McClanahan, DDS, MS,<sup>§</sup> Mansur Ahmad, PhD, BDS,<sup>||</sup> and Walter R. Bowles, PhD, DDS, MS, BPharm<sup>¶</sup>

## Abstract

**Introduction:** The increased use of implants and potential endodontic misadventures can lead to nerve damage. The purpose of this study was to use cone-beam computed tomography (CBCT) measurements to investigate mandibular canal (MC) location in relation to mandibular posterior teeth, the dimension of the buccal and lingual bone over the MC, the diameter of the MC, and the anterior loop location near the mental foramen. **Methods:** CBCT scans from 106 patients (age, 18–69 years) were used to evaluate measurements from 636 teeth and respective MC areas. **Results:** Respective locations of MC to teeth (buccal, inferior, or lingual) were as follows: second molar (57% buccal, 40% inferior, and 3% lingual), first molar (18% buccal, 55% inferior, and 27% lingual), and second premolar (33% buccal, 55% inferior, and 11% lingual). Buccal bone thickness over the MC was thickest at mesial root of second molars and thinnest over the second premolar (5.4 versus 2.6 mm). The lingual bone next to the MC was thickest over the second premolar and thinnest at distal root of first molars (3.8 versus 1.7 mm). The average diameter of the MC along the length of the canal from second molar to second premolar was 3.03 mm on left and 2.91 mm on right. The anterior loop was present in 10.4% of patients, with the average depth below bone of 13.43 mm. The anterior loop was more often seen on the left side than right and occurred bilaterally 50% of the time. **Conclusions:** Mandibular bone thickness, nerve location, and dimension data all contribute to a useful knowledge base for practitioners. The application of CBCT imaging techniques aids in the surgical treatment, while offering advantages over conventional periapical and panoramic films. (*J Endod* 2016;42:1018–1021)

## Key Words

Anatomy, endodontics, implants, mandibular canal, nerve, oral surgery

Invasive procedures are the etiologic factor in 63% of dental cases with neuropathy (1). When performed incorrectly, implant surgery and endodontic procedures can lead to neurologic deficits such as pain, paresthesia, or anesthesia (2–4). The inferior alveolar nerve (IAN) is one area particularly at risk of damage. Before surgical correction of damaged areas such as these can be performed, it is imperative for the surgeon to be familiar with the anatomic landmarks and structures adjacent to the area. Use of cone-beam computed tomography (CBCT) can provide accurate measurements, but CBCT may not always be available.

Three mechanisms of IAN damage from implants and endodontic procedures have been identified: mechanical, chemical, and thermal (5, 6). Mechanical trauma to the IAN may occur from an injection, drilling technique, implant placement on or near the nerve (5), overextension and overinstrumentation, or an iatrogenic error such as severance of the nerve (5, 7, 8). An irrigation solution or an endodontic intracanal medicament or sealer can chemically damage the IAN (5, 8). Thermal injuries to the IAN include overheating the implant drill, extended ultrasonic use, or placing overheated gutta-percha in an overprepared canal (9).

The IAN is enclosed within the mandibular canal (MC) and branches at the mental foramen into the mental and incisive nerves. This most often occurs near the apex of the second premolar or between the 2 premolars (10). Liu et al (11) categorized the course and shape of the MC from the mandibular foramen to the mental foramen into 4 categories and showed that nearly half had an elliptical arc curve. The MC is usually bilaterally symmetrical (12), but variations such as a bifid canal have been reported in the literature.

Before performing an invasive apical surgical procedure in the posterior mandible, it is imperative to know the relative position of the IAN. Studies have shown CBCT to be reliable and accurate for clinical measurements (13–19), including buccal bone height and thickness (17). Recent CBCT studies have evaluated the relationship between root apices and the MC (20–22), and buccal bone thickness (21–24). The purpose of the present study was to perform measurements by using existing CBCT scans to investigate the MC location below mandibular posterior root apices, the thickness of the buccal and lingual bone over the MC, the diameter of the MC, and the anterior loop (AL) location (if present) and size near the mental foramen, all of which add to a knowledge base for dental practitioners.

## Materials and Methods

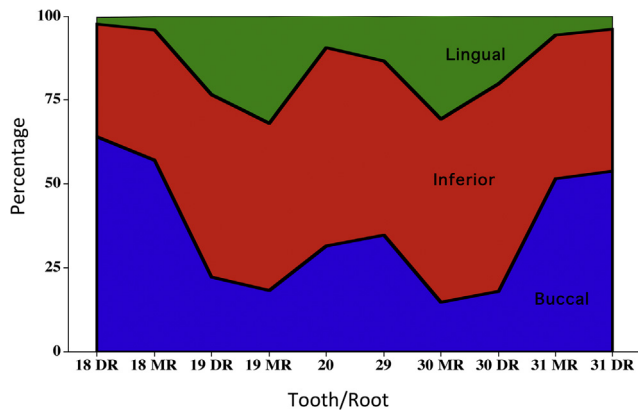
The University Institutional Review Board approved this study. Previous CBCT scans from 2012–2013 were examined from patients aged 18–69 years. Exclusion criteria included the following:

From the \*US Navy Dental Corps, Camp Lejeune, Jacksonville, North Carolina; <sup>†</sup>Private Practice, Athens, Greece; <sup>‡</sup>Private Practice, Colorado Springs, Colorado; and <sup>§</sup>Division of Endodontics and <sup>||</sup>Division of Oral Medicine and Diagnosis, University of Minnesota School of Dentistry, Minneapolis, Minnesota.

Address requests for reprints to Dr Walter R. Bowles, Division of Endodontics, University of Minnesota School of Dentistry, 8-166 Moos Tower, 515 Delaware Street SE, Minneapolis, MN 55455. E-mail address: bowle001@umn.edu  
0099-2399/\$ - see front matter

Published by Elsevier Inc. on behalf of American Association of Endodontists.

<http://dx.doi.org/10.1016/j.joen.2016.03.004>



**Figure 1.** Respective location of mandibular canal (buccal, inferior, or lingual) to tooth roots. The mandibular canal was directly below the root approximately 50% of the time. *N* = 98–106/group. DR, distal root; MR, mesial root.

1. Missing >1 posterior mandibular tooth (excluding third molars)
2. Nonvisible MC from the sagittal view
3. Presence of severe bone loss in the posterior mandible
4. Artifacts that affected diagnostic quality

The first 106 patient CBCT scans that met the criteria were used, which included 636 teeth to be evaluated. These scans were from 34 male and 72 female patients and were previously obtained by using a Next Generation i-CAT (Imaging Sciences International, Hatfield, PA) with 14-bit grayscale resolution and voxel size 0.125–0.3 mm.

Three examiners were calibrated for radiographic interpretation of the scans. Examiners viewed the scans on a Dell 24-inch non-glossy monitor with a Dell Optiplex 9010 WorkStation (Dell Inc, Round Rock, TX). All measurements were taken in a magnified view for better visualization. For ease of locating the MC, examiners traced the MC from the mandibular foramen and mental foramen in an orientation such that the canal was perpendicular to the coronal plane. Measurements were taken from cross-sectional slices at levels of root apices

to evaluate location of MC, bone thickness, and MC dimensions as well as AL location and dimensions.

After all measurements were taken, grouping of data by side of mandible, tooth root, age (<40 or ≥40), and sex was completed. A random intercept model was used to account for multiple CT scan measurements within a subject. Sex, age, and tooth type were included as fixed effects in the model. *P* values < .05 were considered significant. Right and left symmetry was evaluated by using Pearson correlation coefficients (*r*) with paired *t* tests. SAS V9.1.3 software (SAS Institute, Inc, Cary, NC) was used for the analyses.

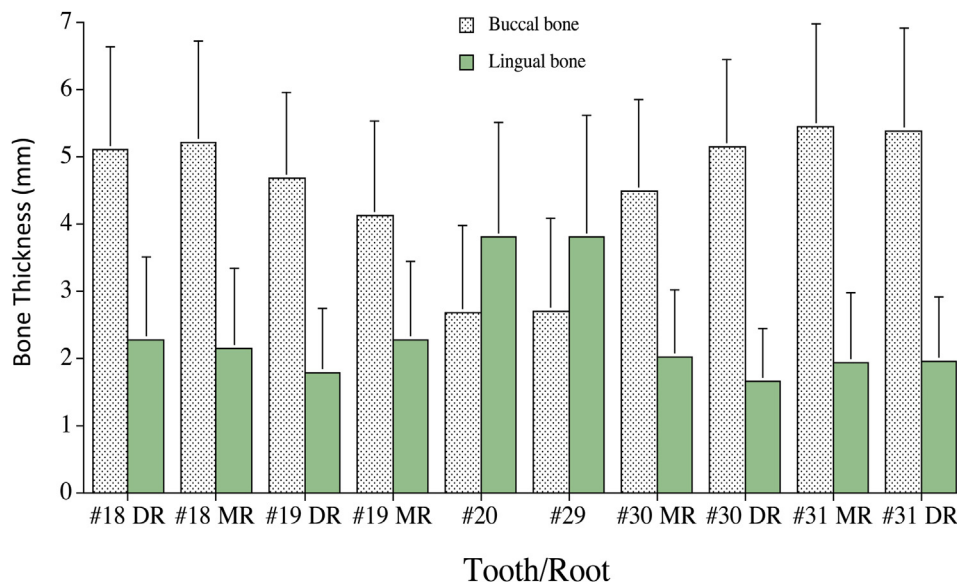
## Results

Respective locations of the MC below teeth (buccal, inferior, or lingual) were as follows: second molar: 57% buccal, 40% inferior, and 3% lingual; first molar: 18% buccal, 55% inferior, and 27% lingual; and second premolar: 33% buccal, 56% inferior, and 11% lingual (Fig. 1). No significant sex difference was noted for MC location by age or sex.

Buccal bone thickness over the MC was found to be thickest at the vertical level of the mesial root of second molars, averaging 5.4 mm. Buccal bone over the MC was thinnest at the vertical level of second premolars, with an average thickness of only 2.6 mm (Fig. 2). This difference in thickness between buccal bone at the mesial root of the second molars and the second premolars was significant, *P* < .05. The lingual bone over the MC was thickest at the second premolars (3.8 mm) and thinnest over the distal root of first molar (1.7 mm) (Fig. 2). In tracing the course of the MC anteriorly from the mesial root of the second molar, the buccal bone thickness over the MC generally decreased, and the lingual bone thickness increased. No significant sex differences were noted for bone thickness in women or men aged ≥40 or <40.

The average diameter of the MC from second molar to second premolar was measured below each tooth root. The average diameter of the left MC was 3.03 mm, and the right MC average was 2.91 mm.

The AL was present in 10.4% of patients (11 patients with 15 instances of AL, right or left), with an average depth below bone crest of 13.43 mm (Fig. 3). The majority of instances where the AL was present were in female patients (9 female versus 2 male). The AL was more often seen on left side than right and was seen bilaterally 36% of the time (in 3



**Figure 2.** Buccal and lingual bone thickness over the mandibular canal. DR, distal root; MR, mesial root. *N* = 98–106/group. Error bars = standard deviation.

Download English Version:

<https://daneshyari.com/en/article/3147635>

Download Persian Version:

<https://daneshyari.com/article/3147635>

[Daneshyari.com](https://daneshyari.com)