



Contents lists available at ScienceDirect

## American Journal of Ophthalmology Case Reports

journal homepage: <http://www.ajocasereports.com/>

## Case report

## Utility of anterior segment swept-source optical coherence tomography for imaging eyes with antecedent ocular trauma

Handan Akil <sup>b, \*</sup>, Lilit Minasyan <sup>a</sup>, Brian A. Francis <sup>a, b</sup>, Vikas Chopra <sup>a, b</sup><sup>a</sup> Department of Ophthalmology, David Geffen School of Medicine at UCLA, Los Angeles, CA, USA<sup>b</sup> Doheny Eye Institute, Doheny Image Reading Center, Los Angeles, CA, 90033, USA

## ARTICLE INFO

## Article history:

Received 14 December 2015

Received in revised form

14 March 2016

Accepted 26 March 2016

Available online 30 March 2016

## Keywords:

Traumatic eye injuries

Ocular trauma

Swept source anterior segment optical coherence tomography

## ABSTRACT

*Purpose:* To evaluate the utility of swept source optical coherence tomography (SS-OCT) for the analysis of anterior segment structures in cases with previous traumatic eye injuries.*Observations:* We report three eyes of three patients with anterior segment traumatic eye injury and highlight the role of SS-OCT in their evaluation and management. This technology enabled us to visualize the structural details of anterior segment of the eye and augment the clinical examination in our patients. Given that it is non-invasive and that there is no contact involved, it may be an ideal imaging modality for traumatic eye injuries for viewing the details before and after any clinical intervention especially in the sub-acute setting.*Conclusions:* The anterior segment SS-OCT is a useful device allowing non-invasive, non-contact, real-time, cross-sectional anterior segment images of eyes with previous ocular trauma.© 2016 The Authors. Published by Elsevier Inc. This is an open access article under the CC BY-NC-ND license (<http://creativecommons.org/licenses/by-nc-nd/4.0/>).

## 1. Introduction

Anterior segment optical coherence tomography (ASOCT) has been shown to be a valuable tool for the evaluation and management of ocular conditions such as narrow angles and primary angle closure [1,2]. The utility of ASOCT for the assessment and management of ocular trauma has not fully been explored. Classically, ocular assessments in the setting of antecedent trauma has been performed using traditional slit lamp examination, gonioscopy and ultrasound biomicroscopy. However, traumatized ocular tissue can be fragile especially in the acute and sub-acute setting, and hence, using contact methods to assess the anterior segment may not be desired [3].

The disadvantages of contact methods, such as risk of corneal abrasions, infections due to corneal contact, and discomfort experienced by the patient, have made the noncontact ASOCT imaging devices popular [4].

In all our cases, we used the Casia SS-1000 OCT (Tomey, Nagoya, Japan), which is a commercially available swept-source OCT

specifically designed for imaging the anterior segment. The device uses 1310 nm wavelength with a scan speed of 30,000 A-scans per second, with an axial resolution of less than 10 μm. The anterior chamber angle can be imaged in 128 cross-sections (each with 512 A-scans) 360° around the anterior segment in 2.4 seconds [5].

We describe three eyes of three patients with antecedent anterior segment traumatic eye injury and highlight the role of anterior-segment SS-OCT in their evaluation and management.

## 2. Findings

All patients provided written consent for publication of personal information including medical record details and photographs.

## 2.1. Case report 1

A 76-year-old male presented to the emergency room complaining of severe pain in his left eye and headache. Patient's ocular history was significant for a traumatic eye injury that required subsequent cataract removal with no intraocular lens implantation in his left eye at 16 years of age. On examination, the patient's visual acuity was 20/20 in the right eye and light perception in the left eye. The intraocular pressure (IOP) measured 18 mm Hg in the right eye and 46 mm Hg in the left eye. Slit lamp examination of the right eye was unremarkable. Slit-lamp examination of the left eye was

\* Corresponding author. Doheny Eye Institute, Doheny Image Reading Center, 1450 San Pablo Street, Los Angeles, CA, 90033, USA.

E-mail addresses: [HAkil@doheny.org](mailto:HAkil@doheny.org) (H. Akil), [Minasyan@jsei.ucla.edu](mailto:Minasyan@jsei.ucla.edu) (L. Minasyan), [BFrancis@doheny.org](mailto:BFrancis@doheny.org) (B.A. Francis), [VChopra@doheny.org](mailto:VChopra@doheny.org) (V. Chopra).

hampered by corneal edema, as well as, band keratopathy of the cornea, but appeared to have a relatively flat anterior chamber with significant peripheral iris-cornea touch and 360° peripheral anterior synechiae (PAS) (Fig. 1A). Retro-iris dense material likely from residual cortex/capsule and mild neovascularization at pupillary margin were seen. Gonioscopy was challenging due to inadequate visualization and the patient was sent for additional imaging including anterior segment SS-OCT and ultrasound biomicroscopy (UBM). Ten MHz B-scan ultrasound revealed no mass or tumor of the posterior segment. UBM showed iridocorneal contact and shallowing of the anterior chamber (Fig. 1B). The SS-OCT added value to the exam as it displayed a full 360° visualization of all iris corneal adhesions, confirmed synechial angle closure, but additionally revealed seclusio pupilla (Fig. 1C, Video 1). The patient was diagnosed with pupillary block angle closure glaucoma in the left eye with iris-lenticular adhesions revealed only by the anterior-segment SS-OCT. After treatment with topical and systemic ocular hypertensive medications, the patient underwent successful laser peripheral iridotomy (LPI) in the left eye. At one week follow-up after LPI, the patient was now asymptomatic, and repeat anterior segment SS-OCT demonstrated the formation of anterior chamber with significant reduction in iridocorneal touch (Fig. 1D).

Supplementary video related to this article can be found at <http://dx.doi.org/10.1016/j.ajoc.2016.03.004>.

## 2.2. Case report 2

A 48-year-old male presented to the ER complaining of a pain in his left eye after having blunt ocular trauma to that eye and was then referred to ophthalmology clinic. The history revealed that the patient had had a LASIK surgery in 2009. On exam, the patient's best corrected visual acuity was 20/20 in the right eye and 20/30 in the left eye. Left pupil was unreactive to direct and indirect

pupillary light reflex. IOP was 19 mm Hg in the right eye and 5 mm Hg in the left eye. Slit lamp examination revealed central corneal opacity throughout the stroma, 2 (+) shallow anterior chamber, iridodialysis extending from 6:30 to 9:30 o'clock, mid dilated pupil and nuclear sclerotic cataract (Fig. 2). Choroidal folds and cystoid macular edema were seen in fundus examination. Due to corneal edema and the shallow anterior chamber, gonioscopy did not afford a clear view of the anterior chamber angle recess. Anterior segment SS-OCT was performed and confirmed a large iridodialysis in 4 clock hours, and revealed a very-large area of cyclodialysis in 7 clock hours (extending from 5:30 to 12:30) (Fig. 3, Video 2). The SS-OCT results allowed a more thorough evaluation of the anterior segment and proper planning for surgical repair of the iridodialysis, as well as, the cyclodialysis.

Supplementary video related to this article can be found at <http://dx.doi.org/10.1016/j.ajoc.2016.03.004>.



Fig. 2. Case 2: Slit lamp examination revealing iridodialysis extending from 6.30 to 9.30 o'clock.

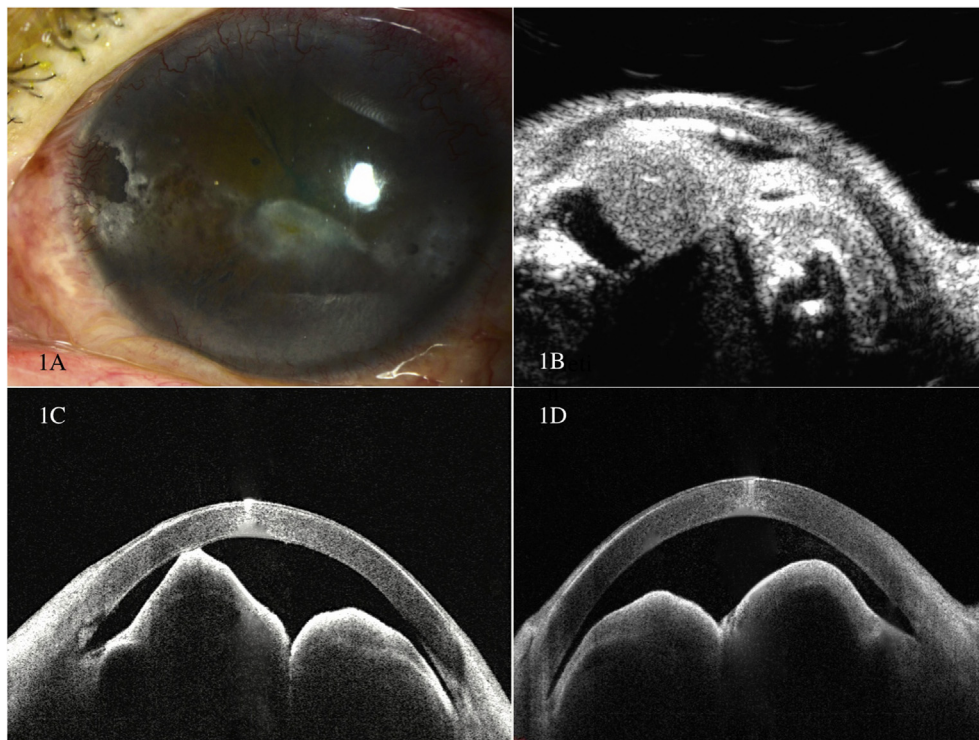


Fig. 1. Case 1: Slit lamp examination (1A), Ultrasound biomicroscopy showing iris bulge and shallow anterior chamber (1B), Swept source AS-OCT imaging before laser peripheral iridotomy showing iris corneal touch (1C), Swept source AS-OCT imaging after laser peripheral iridotomy with the iris falling away from the cornea and deepening the anterior chamber (1D).

Download English Version:

<https://daneshyari.com/en/article/4006562>

Download Persian Version:

<https://daneshyari.com/article/4006562>

[Daneshyari.com](https://daneshyari.com)