Available online at www.sciencedirect.com

ScienceDirect

journal homepage: www.elsevier.com/locate/survophthal

Clinical pathologic reviews

Primary adenocarcinoma of pigmented ciliary epithelium in a phthisical eye

Jaya B. Kumar, MD[a], *Alan D. Proia, MD, PhD*[b], *Prithvi Mruthyunjaya, MD*[a], *Sumit Sharma, MD*[a,*]

[a] *Department of Ophthalmology, Duke Eye Center, Duke University, Durham, North Carolina, USA*
[b] *Department of Pathology, Duke University, Durham, North Carolina, USA*

ARTICLE INFO

Article history:
Received 13 August 2015
Received in revised form 1 November 2015
Accepted 6 November 2015
Available online 17 November 2015
Stefan Seregard and **Hans Grossniklaus**, Editors

Keywords:
primary adenocarcinoma of pigmented ciliary epithelium
phthisis
malignant transformation

ABSTRACT

We report a case of adenocarcinoma of the pigmented ciliary epithelium arising in a phthisical eye. A 92-year-old man who initially presented with severe ocular pain had calcification extending from the posterior pole to ciliary body on B-scan ultrasonography to a degree not previously reported. We highlight the importance of screening for intraocular neoplasms in adults with a long-standing phthisical eye.

© 2015 Elsevier Inc. All rights reserved.

1. Clinical presentation

A 92-year-old white man was presented with acute onset of right eye pain. His ocular history was significant for a metallic foreign body injury to the right eye over 50 years ago leaving him with no light perception vision. Slit-lamp examination revealed 360° of neovascularization of the iris, 30% hyphema, diffuse anterior chamber cell and flare, brunescent cataract with no view to the posterior pole (Fig. 1). B-scan ultrasonography showed a possible mass with diffuse calcification and hyperechogenicity extending from the posterior pole anteriorly to the ciliary body with retinal detachment (Fig. 2 A and B). The anterior segment changes were attributed to chronic phthisis bulbi or an intraocular mass of unclear etiology. The patient was placed on prednisolone drops every 2 hours and atropine every 12 hours, but his symptoms and exam were unchanged 6 weeks later.

2. Imaging

A review was made of ultrasound imaging from 9 months prior, and the questionable hyperechogenic mass appeared to have grown (Fig. 2C). Computed axial tomography scans of the head, chest, abdomen, and pelvis were negative for metastatic

* Corresponding author: Sumit Sharma, MD, Department of Ophthalmology, Duke Eye Center, Duke University, 2351 Erwin Road, Box 3802, Durham, NC 27710, USA.
E-mail address: sharmas@ccf.org (S. Sharma).
0039-6257/$ – see front matter © 2015 Elsevier Inc. All rights reserved.
http://dx.doi.org/10.1016/j.survophthal.2015.11.001

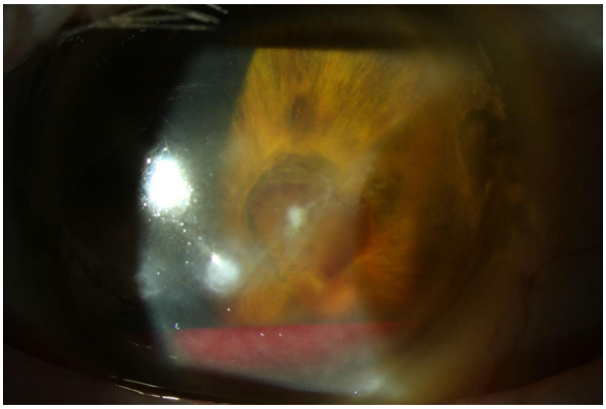

Fig. 1 – Slit-lamp photo of right eye revealing diffuse corneal edema, corneal scars, 360° of neovascularization of the iris, 30% hyphema, diffuse anterior chamber cell and flare, and brunescent cataract.

disease but showed a circular compact heterogeneous hyperdense lesion in the globe (Fig. 2D). Magnetic resonance imaging could not be obtained because of the history of a metallic object in the orbit. Given the concern for malignancy and lack of clinical improvement, a decision was made to enucleate the right eye.

3. Pathology

Gross examination revealed a 2.0 × 1.5 × 0.1 cm tan-brown mass with areas of hemorrhage in the posterior half of the globe that microscopically was composed of organizing hemorrhage, gliotic retina, and choroidal ossification. Inferiorly, there was a tumor centered in the region of the ciliary body with invasion posteriorly into the choroid. The maximum anterior-posterior dimension of the tumor in histologic sections was 8 mm, and the maximum thickness was 3 mm.

The tumor was composed of cells with moderate amounts of cytoplasm having variable melanin pigmentation and round to oval nuclei with stippled chromatin. The tumor cells formed sheets, cords, and glands with an eosinophilic basement membrane. Basement membrane was occasionally prominent and was highlighted using periodic acid-Schiff stain (Fig. 3 A–D). Small foci of ossification were in the tumor. Choroidal invasion of the tumor cells provided the key in differentiating adenoma from adenocarcinoma (Fig. 4). A diagnosis of adenocarcinoma arising from the pigmented ciliary epithelium (CE) was made based on the cytologic features of the tumor cells, invasion of the choroid, and the presence of a basement membrane surrounding tumor cells.[5,9] The metastatic workup has been negative, and he has otherwise been clinically stable.

4. Discussion

Tumors of the CE can be classified as benign from reactive hyperplasia, age-related hyperplasia (Fuchs adenoma), malignant—either congenital (medulloepithelioma) or acquired—or metastatic to the ciliary body.[6,8] True acquired

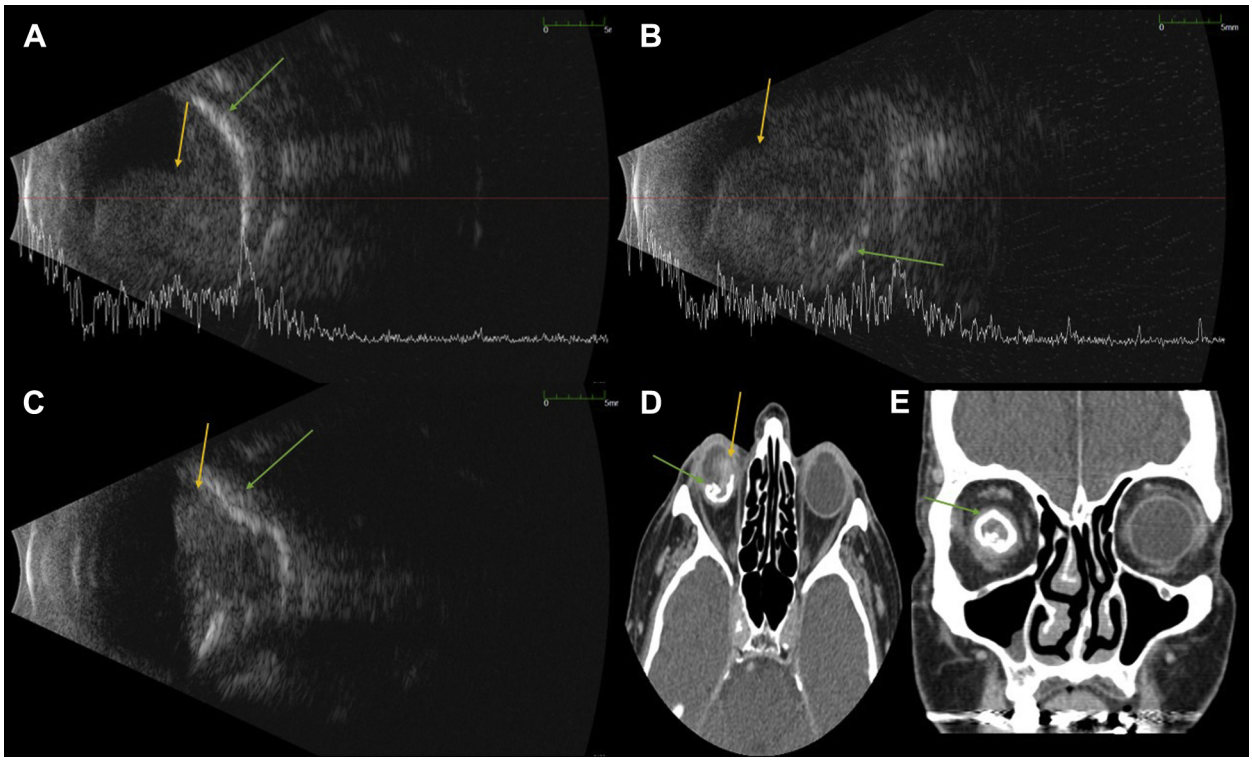

Fig. 2 – B-scan ultrasonographs showing *A* and *B*: diffuse calcification (*green arrows*) and homogenous hyperechogenic mass (*yellow arrows*) extending from posterior pole anteriorly to ciliary body *C*: larger compared to 9 months prior. *D*: sagittal and *E*: coronal CT sections showing corresponding hyperdense mass and posterior calcification. CT, computed tomography.

Download English Version:

https://daneshyari.com/en/article/4032429

Download Persian Version:

https://daneshyari.com/article/4032429

Daneshyari.com