Journal of Orthopaedics, Trauma and Rehabilitation 22 (2017) 18–21

Contents lists available at ScienceDirect

Journal of Orthopaedics, Trauma and Rehabilitation

Journal homepages: www.e-jotr.com & www.ejotr.org

Research Paper

Dorsalis Pedis Artery-based Flap to Cover Nonhealing Wounds Over the Tendo Achillis—A Case Series
用足背動脈蒂皮瓣來覆蓋非癒合的跟腱手術傷口—系列病例報告

Chandra Varun*, Singh Raj Kumar

Joint Replacement and Reconstructive Orthopaedics, Tata Main Hospital, Jamshedpur, India

ARTICLE INFO

Article history:
Received 1 September 2015
Received in revised form
29 October 2015
Accepted 17 December 2015

Keywords:
dorsalis pedis artery-based flap
open repair
tendo Achillis

ABSTRACT

Background/Purpose: Soft tissue necrosis after the repair of a ruptured tendo Achillis is a difficult problem commonly encountered by orthopaedic surgeons. Such wounds are difficult to manage because of the tenuous blood supply and the characteristic anatomical features of the area. Flaps such as the reverse sural flap, medial plantar flap, gastrocnemius flap and free flaps cover such wounds with a good success rate. The aim of our study was to investigate the use of a dorsalis pedis artery (DPA)-based flap to cover a wound over the tendo Achillis insertion area.
Methods: We report a series of 11 patients in whom wounds over the tendo Achillis insertion area were covered with a DPA-based flap. Between 1995 and 2012, 11 patients (nine men and two women), who were referred to us with a nonhealing wound over the tendo Achillis because of soft tissue necrosis after the open repair of a ruptured tendon, were selected for soft tissue coverage of the wound by using a DPA-based flap.
Results: The average follow-up period was 2.4 years (range, 1–6 years). The mean operative time was 1.7 hours (range, 1.5–2.0 hours). At the latest follow-up examination, the flaps had survived in all patients.
Conclusion: A DPA-based flap is a good and relatively less complex procedure to use to cover defects over the tendo Achillis with minimum donor site morbidity.

中 文 摘 要

背景: 跟腱修補手術的傷口出現軟組織壞死,是骨科醫生常見到但很難處理的併發症。由於該區域的脆弱的血液供應和解剖特徵,使傷口難以處理。文獻中已經描述了許多不同的皮瓣,例如反向腓腸皮瓣,內踝側皮瓣,腓腸肌皮瓣以及一些游離皮瓣來覆蓋這些傷口,都有良好的成功率。我們本研究的目的,是調查用足背動脈蒂皮瓣(Dorsalis Pedis artery based flap, DPA flap)來覆蓋這些跟腱手術傷口的成效。
方法: 從1995 年到2012 年,一系列共11 病例(9 男2 女)接受了DPA flap 來覆蓋跟腱修補手術後不能愈合的傷口。
結果: 隨訪時間平均為2.4 年(範圍由1-6 年)。手術時間平均為1.7 小時(範圍由1.5 至 2 小時)。在最後的隨訪,所有的病例的皮瓣都存活。
結論: 用DPA flap 來覆蓋跟腱傷口有很好的果效,步驟簡單而且對供皮區的傷害很少。

Introduction

An open repair of a ruptured tendo Achillis is associated with the common complication of wound dehiscence. Soft tissue reconstruction of the tendo Achillis insertion region because of its anatomical peculiarities is challenging for the treating reconstructive surgeon.[1,2] Such wounds have been covered by various types of local and free flaps. A commonly used flap is the neurosensory distally based island sural flap.[3,4] Other flaps are the medial plantar flap and the muscle or musculocutaneous flap using the gastrocnemius, peroneus brevis or abductor hallucis.[5–9] The dorsalis pedis artery (DPA)-based flap has been used to cover ankle and foot defects.[1,10] To cover a heel wound, a DPA-based flap may have to be lengthened by a graft or the whole flap may have to pass through the interosseous membrane between the tibia and fibula to

* Corresponding author. *E-mail:* varunaqua7@yahoo.co.in.

http://dx.doi.org/10.1016/j.jotr.2015.12.004
2210-4917/Copyright © 2016, The Hong Kong Orthopaedic Association and Hong Kong College of Orthopaedic Surgeons. Published by Elsevier (Singapore) Pte Ltd. This is an open access article under the CC BY-NC-ND license (http://creativecommons.org/licenses/by-nc-nd/4.0/).

short-circuit the pedicle or to enable the flap to reach the site without tension.[11,12] In this series, we have used the DPA-based flap to cover wounds over the tendo Achillis without any lengthening of the artery by using a venous graft because this technique has less need for an excursion length to the tendo Achillis insertion site. This flap has a wide arc of rotation, reliable vascularity, and can also be used as a sensory flap.[1]

Patients and methods

Between 1995 and 2014, 11 patients were referred to us with defects over the tendo Achillis, after its open repair (Figure 1). The size of the defects ranged from 1.5 cm × 2 cm to 2 cm × 3 cm. The flap size was mapped by the wound size. The wounds were caused by tissue breakdown and skin necrosis after an open surgical repair of a ruptured tendo Achillis that had been performed elsewhere. The open wounds were contaminated, although we could not isolate any positive bacterial culture in any patient. One reason for this finding could be the prolonged use of antibiotics that the patients were already receiving before coming to us. The patients were selected for a DPA-based flap to cover the wound over the tendo Achillis. The selection criteria included (1) the clinical presence of dorsalis pedis and posterior tibial arterial pulses, (2) healthy skin over the dorsum of the foot, and (3) no history of longstanding diabetes mellitus or peripheral vascular disease. The 11 patients comprised nine men and two women. The mean age of the patients was 41 years (range, 30–52 years). The wound was healthy in all patients, except one patient in whom the infection subsided after 1 week of regular dressings and antibiotic therapy. After wound healing, the patients were followed up at 6 weeks, 6 months, 1 year, and 3 years. In two patients, we obtained a magnetic resonance (MR) angiogram at the 3-month follow up examination to demonstrate the presence of a vascular pedicle extending to the flap site (Figure 2).

Surgical technique

With the patient supine, the operation was performed under tourniquet control. First, the surface was marked. The size of the flap was determined by mapping the wound with sterile paper and using it as the template. The boundary of the skin available for the flap extended proximally from the ankle joint to the metatarsophalangeal joint distally. The mediolateral borders of the flap extended from the tendon of the extensor hallucis longus medially to the tendon of the extensor digitorum longus. A distal incision was first created at the first web space, and the first dorsal metatarsal artery was then identified, ligated, and divided. The branches of the superficial peroneal nerve were similarly identified and divided laterally. The flap was dissected distoproximally deep to the first dorsal metatarsal artery. The paratenon of the extensor tendons were preserved. The dissection of the flap was continued proximally. As the dissection proceeded from the medial to the lateral side, the DPA was further dissected from the underlying tarsal bones and the maximum amount of tissue was preserved between the extensor hallucis longus and extensor digitorum longus tendons. With the proximal incision completed, the extensor retinaculum was opened and the DPA and its venae comitantes and nerves were identified. The extensor digitorum longus was retracted laterally, thereby exposing the extensor digitorum brevis. The first head of the muscle remained connected to the superficial tissues but separated from the rest of the muscle. The lateral tarsal artery was ligated deep to the muscle. The flap was finally isolated on the vascular pedicle. We dissected the pedicle proximally and continued assessing the length of the pedicle required to reach the recipient site. The average length of the pedicle was 18.1 cm (range, 16–20 cm). However, we believe that discussing any mean length or its measurement does not impact the performance of the procedure.

The dissection continued until the desired length was achieved (Figure 3). The tourniquet was deflated to assess circulation in the flap. The first head of the extensor digitorum brevis must be included to preserve the blood supply of the overlying skin. The extensor digitorum brevis dissected out will naturally maintain the

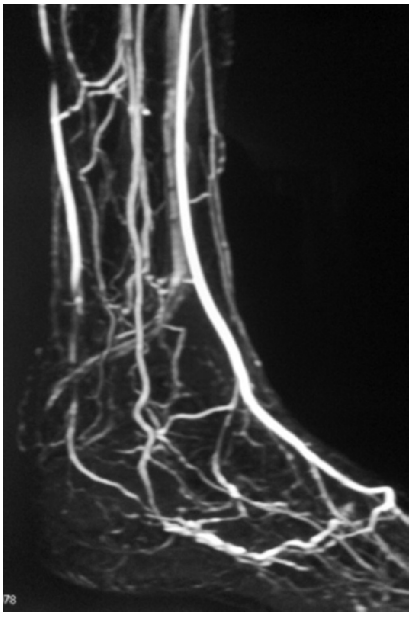

Figure 2. The magnetic resonance angiogram of a patient at the 3-month follow up shows that the diverted route of the dorsalis pedis artery extends to the base of the flap.

Figure 1. The wound over the tendo Achillis before surgery.

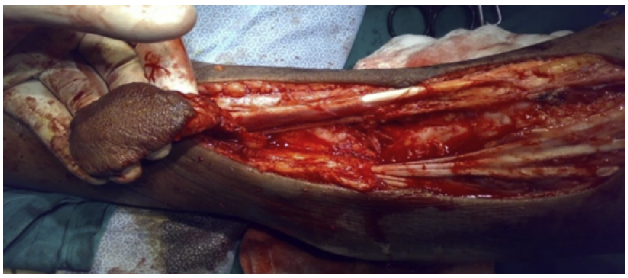

Figure 3. The intraoperative image shows the flap with the vascular pedicle of dorsalis pedis artery.

Download English Version:

https://daneshyari.com/en/article/4072513

Download Persian Version:

https://daneshyari.com/article/4072513

Daneshyari.com