



Contents lists available at ScienceDirect

Trauma Case Reports

journal homepage: www.elsevier.com/locate/tcr

Case Report

Delayed chest wall hematoma caused by progressive displacement of rib fractures after blunt trauma

Nobuhiro Sato^{a,*}, Hiroshi Sekiguchi^b, Yasuo Hirose^a, Satoru Yoshida^a^a Department of Emergency and Critical Care Medicine, Niigata City General Hospital, 463-7, Shumoku, Chuo-ku, Niigata 950-1197, Japan^b Department of Emergency and Critical Care Medicine, Uonuma Kikan Hospital, 4132, Urasa, Minamiuonuma, Niigata 949-7302, Japan

ARTICLE INFO

Article history:

Accepted 28 May 2016

Available online 14 June 2016

Keywords:

Angiography

Chest wall

Delayed complication

Rib fracture

Thoracic injury

ABSTRACT

Rib fracture is a common injury resulting from blunt thoracic trauma. Although hemothorax and pneumothorax are known delayed complications of rib fracture, delayed chest wall hematoma has rarely been reported. We discuss the case of an 81-year-old woman who was not undergoing antiplatelet or anticoagulant therapy who presented to our emergency department after a traffic injury. This patient had a nondisplaced rib fracture that went undetected on the initial computed tomography scan; the development of progressive displacement led to hemorrhagic shock due to delayed chest wall hematoma. The chest wall hematoma was effectively diagnosed and treated via contrast-enhanced computed tomography and angiographic embolization. This case highlights the possibility of this potential delayed complication from a common injury such as a rib fracture.

© 2016 The Authors. Published by Elsevier Ltd. This is an open access article under the CC BY-NC-ND license (<http://creativecommons.org/licenses/by-nc-nd/4.0/>).

Introduction

Rib fractures are a common injury associated with blunt thoracic trauma. Although hemothorax and pneumothorax are well-known delayed complications of rib fractures, delayed chest wall hematomas have rarely been reported [1,2]. We present a unique case of hemorrhagic shock caused by a delayed chest wall hematoma caused by progressively displaced rib fractures. We have defined a delayed complication as a complication appearing 24 h or more after an injury [3].

* Corresponding author at: Department of Emergency and Critical Care Medicine, Niigata City General Hospital, 463-7 Shumoku, Chuo-ku, Niigata, Japan. Tel.: +81 25 281 5151; fax: +81 25 281 5187.

E-mail address: s_nobuhiro@hosp.niigata.niigata.jp (N. Sato).

Case report

An 81-year-old female with a medical history of hypertension presented to the emergency department in a tertiary care hospital with retrograde amnesia, headache, and chest pain after a motor vehicle accident. Vital signs on arrival were blood pressure 172/112 mmHg, pulse rate 80 beats/min, and respiratory rate 31 breaths/min. She had an occipital contusion and tenderness on her left precordium but no back pain or chest contusion. Glasgow coma score was 15 with retrograde amnesia. There was no history of antiplatelet or anticoagulant therapy. Computed tomography (CT) revealed a mild brain contusion, traumatic subarachnoid hemorrhage, and occipital bone fracture, but no signs of chest injury such as rib fracture (Fig. 1). The patient was admitted with a diagnosis of mild brain contusion, traumatic subarachnoid hemorrhage, and occipital bone fracture. Surgery was not required.

The patient complained of left chest pain with motion that started 3 days after admission. On day 14, radiographs revealed posterior fractures of the left 6th and 7th ribs; because there were no fracture-related complications, conservative treatment was applied. On day 22, the patient experienced acute back pain of unknown cause. A mass was detected on the left side of her back. Chest radiographs revealed rib fractures of the left 6th, 7th, and 8th ribs. CT showed posterior fractures of the left 6th, 7th, and 8th ribs, and a small chest wall hematoma around these fractures without extravasation. As the patient was hemodynamically stable, she was kept rested under close observation.

On day 26, the patient again experienced sudden severe back pain at rest. Her condition became unstable and the mass on her back enlarged. CT showed posterior fractures of the left 4th, 5th, 6th, 7th, and 8th ribs, and enlargement of the chest wall hematoma with extravasation (Fig. 2). We diagnosed chest wall hematoma with hemorrhagic shock. After consulting an interventional radiologist, a blood transfusion with emergency angiographic embolization was arranged. There was contrast extravasation in the branch of the suprascapular artery around the rib fracture (Fig. 3); embolization was performed using a sterile absorbable gelatin sponge. There was no further bleeding from the chest wall, and the patient was discharged on day 37.

Discussion

Chest wall hematoma is often caused by trauma, although nontraumatic causes include anticoagulant use and tumors [4,5]. Chest wall hematoma usually occurs immediately after trauma, and active bleeding is managed by surgery or embolization [6,7]. We present a case of trauma causing delayed chest wall hematoma and hemorrhagic shock.

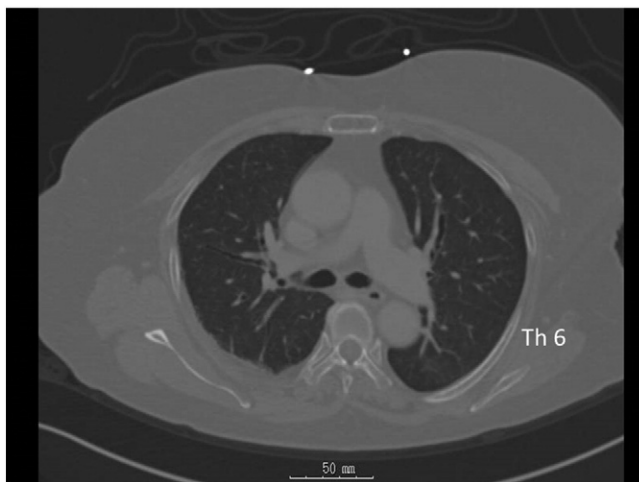


Fig. 1. Computed tomography on day 1 revealed no signs of chest injury such as a rib fracture.

Download English Version:

<https://daneshyari.com/en/article/4100507>

Download Persian Version:

<https://daneshyari.com/article/4100507>

[Daneshyari.com](https://daneshyari.com)