



CASE REPORT

Shattered thyroid gland in a young boy after a blunt neck trauma



Khim Soon Vong^{a,*}, Irfan Mohamad^a, Hazama Mohamad^a, Zaidi Zakaria^b

^a Department of Otorhinolaryngology-Head & Neck Surgery, 16150 Kota Bharu, Kelantan, Malaysia

^b Department of Surgery, Universiti Sains Malaysia Health Campus, 16150 Kota Bharu, Kelantan, Malaysia

Received 22 April 2016; accepted 18 May 2016

Available online 17 June 2016

KEYWORDS

Neck injury;
Thyroid;
Blunt;
Rupture;
Intubation

Abstract Blunt thyroid injury in motor vehicle accident in paediatric patient is relatively rare. The symptoms are often barely anterior neck swelling which gradually increases in size and may or may not compromise the airway, and it can be fatal if missed to be identified. We described the case of a 15-year-old boy who involved in an accident and sustained a shattered thyroid gland despite no open wound in the neck. The management issues were outlined.

© 2016 Egyptian Society of Ear, Nose, Throat and Allied Sciences. Production and hosting by Elsevier B.V. This is an open access article under the CC BY-NC-ND license (<http://creativecommons.org/licenses/by-nc-nd/4.0/>).

1. Introduction

Injuries of the neck can be caused by blunt or penetrating trauma. Blunt neck trauma can cause injury to many structures in the neck region, such as larynx, trachea, oesophagus, neurovascular, bone and muscles. Nevertheless injury to thyroid gland either normal or pathological is not uncommonly reported, and majority of the cases involved adults^{1,2}. However the involvement of paediatric case, such as in this patient with isolated injury to a normal thyroid gland, is relatively rare and the injury did not cause active bleeding or haematoma formation.

2. Case summary

A 15-year-old boy with no known medical illness was brought to the emergency department (ED) of a district hospital after

involving in a motor vehicle accident. He was an unhelmeted motorbike rider hit by a motorcar from the side. He was thrown forward and landed on the road and sustained anterior neck swelling and left parietal region haematoma.

On arrival, his Glasgow Coma Scale (GCS) score was 7 (E2V1M4). Clinically he was not dyspneic and haemodynamically stable. In view of poor GCS score with highly suspected intracranial bleeding, therefore he was intubated without any difficulties with endotracheal tube sized 7.0 for airway protection. Cervical spine radiography demonstrated soft tissue swelling anterior to the trachea but no compression on the laryngeal region, there was no subcutaneous emphysema. He was then immediately transferred to the tertiary hospital for further management.

On arrival at the tertiary hospital ED, the patient's clinical findings showed stable blood pressure with normal and regular heart rate. His capillary oxygen saturation was maintained at 100% on ventilator. His GCS score was 6 + T. Examination of his neck revealed a strip of bruise and abrasion over the anterior neck at the level of thyroid cartilage. There was a diffuse, non-pulsatile, non-fluctuant swelling noted at the left side of the neck. The trachea was slightly displaced to the right

* Corresponding author. Tel.: +60168885186.

E-mail address: ahsoonv@yahoo.com (K.S. Vong).

Peer review under responsibility of Egyptian Society of Ear, Nose, Throat and Allied Sciences.

<http://dx.doi.org/10.1016/j.ejenta.2016.05.007>

2090-0740 © 2016 Egyptian Society of Ear, Nose, Throat and Allied Sciences. Production and hosting by Elsevier B.V.

This is an open access article under the CC BY-NC-ND license (<http://creativecommons.org/licenses/by-nc-nd/4.0/>).

(Fig. 1). The carotid pulse was palpable bilaterally. The laryngeal crepitus was absent, however there was no subcutaneous emphysema or open wound noted.

Neck circumference (NC) was measured as 38 cm upon arrival using a non-stretchable plastic measuring tape placed over the largest swollen part of the neck circumferentially. Needle aspiration over the anterior neck swelling revealed no fluid or blood. Besides flexible nasopharyngolaryngoscopy (FNPLS) was performed but the oedematous soft tissue at the nasopharyngeal region gave limited access. The computed tomography (CT) scan was done twice with 12 h apart that showed shattered left thyroid lobe and isthmus with no haematoma seen (Fig 2). However the anterior neck space appeared full on the left side with swelling extended anterolaterally from C6 till T2 vertebral level (Fig. 3). No laryngeal cartilage injury or compression was noted. The trachea was deviated to the right but no pneumothorax. No haematoma or subcutaneous emphysema was seen. The internal jugular vein and carotid vessels bilaterally were normal in calibre and patent. There were tentorial and subdural haemorrhages with no midline shift.

The blood investigation results for full blood count and coagulation profile showed normal parameters. Thyroid profile results demonstrated TSH 0.2 mIU/L, free T3 2.5 pmol/L and free T4 20.3 pmol/L, intact PTH 4.1 pmol/L which were all shown within the normal level. He was admitted to intensive care unit and managed conservatively by the multidisciplinary team. The shattered thyroid was managed conservatively by monitoring the NC and colour changes over the neck skin.

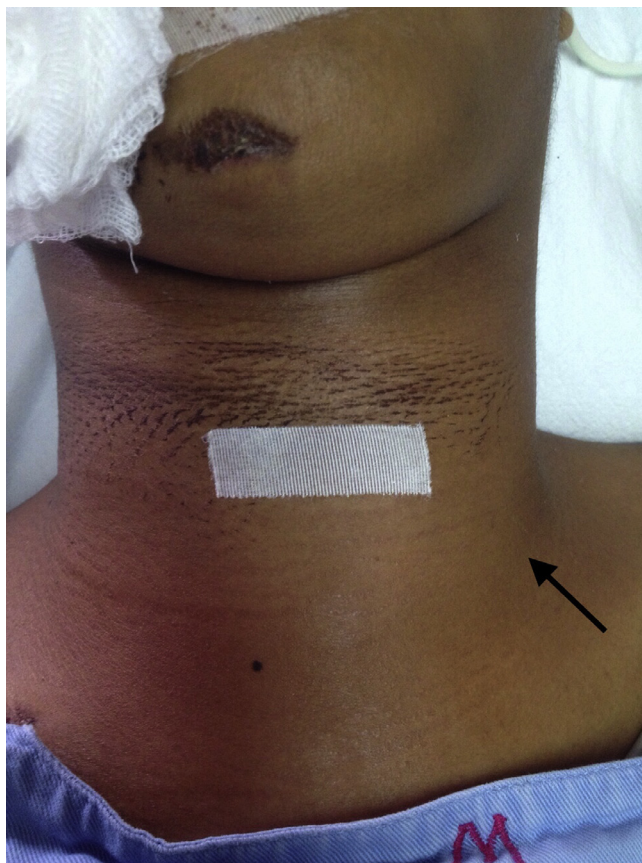

Figure 1 Anterior neck swelling, more obvious on the left side.

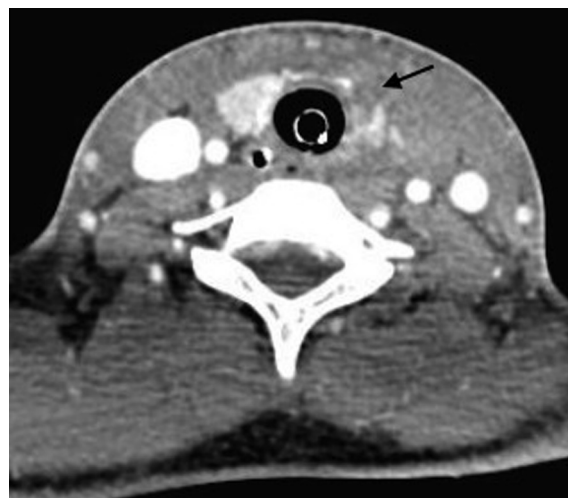


Figure 2 Discontinuity of the margin of the right thyroid lobe with shattered left thyroid lobe and isthmus and has lost its normal architecture.

Signs and symptoms of thyroid storm were also included in the clinical assessment. Anaesthetist team managed the airway and monitored the systemic parameters accordingly. Neurosurgical team managed the intracranial bleed conservatively.

Intravenous dexamethasone 8 mg three times daily was instituted to prevent further soft tissue swelling in the airway. FNPLS was repeated on day 5 of intubation revealed oedematous oropharynx and hypopharynx but able to pass through to reach the supraglottic region but the airway lumen is still narrowed until day 6 of intubation, NC was reduced to 35 cm and the leak test showed positive sign. The patient was successfully extubated without complications.

Repeated FNPLS post extubation showed bilateral vocal cords were symmetrical and mobile with no other laryngeal injury. His neck swelling eventually reduced to normal size without surgical intervention and discharged without respiratory complications.

3. Discussion

This patient was intubated early for the airway protection in view of poor conscious level with highly suspected intracranial bleeding. The physical examinations and further detailed investigations were done with combined fiberoptic laryngoscopy and CT scan. In this case, CT scan can accurately identify the exact kind and extent of injury of thyroid gland, and directly visualize the airway structures and other neck structures. The lungs are clear and no pneumothorax was detected. CT scan can show formation of haematoma within the injured thyroid gland and adjacent to the gland. Increasing size of haematoma on serial CT scan may indicate active bleeding which needs to correlate with the clinical findings. Contrast media extravasation to the surrounding tissues could be a sign of active bleeding. This finding was not present in our case.

In our case, the anterior neck swelling was more prominent on the left side, but did not show increment in size after the initial measurement and subsequent recordings. This indicates there is no major vessel rupture or active bleeding from the ruptured left thyroid gland and its isthmus. Therefore arterial

Download English Version:

<https://daneshyari.com/en/article/4108813>

Download Persian Version:

<https://daneshyari.com/article/4108813>

[Daneshyari.com](https://daneshyari.com)