



ELSEVIER

Contents lists available at ScienceDirect

## Neurocomputing

journal homepage: [www.elsevier.com/locate/neucom](http://www.elsevier.com/locate/neucom)

# In-body ultrasound image processing for cardiovascular interventions: A review



Fei Zuo

Philips Research Eindhoven, 5656AE Eindhoven, The Netherlands

## ARTICLE INFO

*Article history:*

Received 19 September 2013

Received in revised form

6 January 2014

Accepted 21 February 2014

Available online 13 June 2014

*Keywords:*

Minimally invasive intervention

Ultrasound

Tissue characterization

Tissue classification

Device tracking

Image segmentation

## ABSTRACT

In this paper we have surveyed the recent developments in the area of in-body ultrasound imaging for cardiovascular interventions. With miniaturized ultrasound sensors integrated at the tip of the instruments (catheters, needles, endoscopes), the local anatomical sites can be imaged with high accuracy. We have covered the applications of TEE (Transesophageal echocardiography), ICE (intracardiac echocardiography) and IVUS (intravascular ultrasound) and the newly emerging therapy monitoring ultrasound. We particularly focus on advanced signal/image processing technologies and related topics such as tissue characterization, image segmentation, device tracking and multi-modality registration. In the context of in-body imaging, we are faced with more challenges than with the traditional external ultrasound imaging, particularly due to the cardiac dynamics. We need to strive for new solutions that provide more consistent, reliable and accurate analysis results for better clinical decision support.

© 2014 Elsevier B.V. All rights reserved.

## 1. Introduction

In recent years, more and more minimally or non-invasive interventional procedures have been replacing traditional open surgeries. Surgical instrumentation is being substituted by intelligent and miniaturized tools that navigate in the human body for the diagnosis and/or treatment. Examples of such devices are catheters, guide wires, needles and endoscopes. The advantages of using minimally invasive procedures are shorter patient recovery time, greater patient comfort, lower risks of complications and faster patient throughput [1,2].

Imaging is very crucial for image-guided interventions as it provides important information for the diagnosis and treatment. Mostly used imaging modalities include X-ray/fluoroscopy, computed tomography (CT), magnetic resonance imaging (MRI), ultrasound, nuclear imaging and optical imaging. They are used extensively during various steps in an interventional procedure, as illustrated below [1,3].

- Pre-operative imaging: prior to the intervention, usually CT/MRI images are acquired which are later used as references during the interventional procedure.
- Intra-operative imaging: The surgical instruments are inserted into the body and navigated to the target location. Usually X-ray or ultrasound is used to offer real-time navigation and monitoring. In many cases the real-time acquired images have to be registered and mapped to the pre-operative data to provide a clear view of the device relative to the patient anatomy. In some cases, the intra-operative imaging can offer

on-the-spot therapy monitoring and provide real-time feedback to the physicians. During this stage, both external and internal imaging technologies can be used to track and monitor the interventional process.

- Post-operative verification and validation: after the intervention a confirming image is obtained to verify the successful completion of the procedure.

Intra-operative imaging plays a very important role in a complete interventional procedure. It provides a vision to the physicians during the procedure and gives real-time feedback that is of vital importance for the final outcome. Ultrasound is a promising modality to use nowadays for intra-operative imaging, largely because it is nonionizing and safe to use for both the patients and the physicians. Additional benefits are lower-cost and its ability to penetrate through the tissue structures. It is the only imaging modality that is capable of imaging soft tissue deformations quickly enough for interventional procedure guidance – information that fluoroscopy, CT or MRI cannot provide easily [4]. A disadvantage of using ultrasound is the lower signal quality which makes the image interpretation more difficult.

In addition to imaging, the instrument development has enabled the miniaturization of build-in ultrasound sensors that are safe to be used inside the human body. These sensors can be integrated into the catheters or guide wires and directly placed into the body of the patients. They provide a local anatomical view for the diagnosis and treatment, acquiring information that is not easily accessible by traditional external imaging modalities. A few examples in the area of cardiovascular interventions are ICE

(IntraCardiac Echocardiography), TEE (Transesophageal echocardiography) and IVUS (IntraVascular Ultrasound). Recently we are exploring the possibilities to integrate the tissue imaging with therapeutic functions, e.g. radio-frequency tissue ablations for the treatment of atrial fibrillation [5].

In the rest of the paper, we first present a brief overview of the clinical use of the in-body ultrasound imaging and related challenges in the area of cardiovascular interventions. We particularly focus on the signal/image processing aspects and present a few promising research areas that could have significant impact on the current practice of minimally invasive cardiovascular interventions.

## 2. In-body ultrasound imaging

### 2.1. In-body echocardiography

The traditional transthoracic echocardiography (TTE) has been widely available and portable which offers excellent image quality. It has been used mainly in guiding percutaneous noncoronary interventional and electrophysiological procedures [6]. Different from the traditional use of TTE, in-body cardiovascular imaging employs small ultrasound transducers or transducer arrays that are positioned within (or near) the heart/vessels inside the human body. By doing so, the imaging device is closer to the targeted imaging area and provides better view of local anatomical sites. In addition, it offers great flexibility and can be manipulated for more complicated procedures.

#### 2.1.1. TEE (transesophageal echocardiography)

TEE has a small transducer array integrated into the probe, which is inserted into the patient's oesophagus to get a closer and more detailed view at the back of the heart. TEE has been widely used as an alternative to TTE in guiding complex procedures [4,7]. It can be used to image interventional catheters and offers clearer images at the back of the heart, especially of structures that are difficult to view transthoracically. It has been used to monitor a number of interventions such as percutaneous transcatheter closure (PTC) of septal defects, transseptal catheterization, etc.

#### 2.1.2. ICE (Intracardiac echocardiography)

Although relatively new, ICE imaging catheters have gained wide usage for monitoring and guiding interventions such as ventricular septal defect (VSD) device closure, pulmonary valvuloplasty and biopsy of cardiac masses. Recently, ICE is also widely used for the guidance of electrophysiological (EP) procedures in combination with electroanatomical mapping for imaging internal structures [8,9]. The ICE catheters are positioned inside the heart

chamber and provide both near and far field views. The near-field view provides sufficient details of endocardial structures and the intracardiac tools themselves, and the far-field view provides perspective and orientation information. They are made either with a rotational shaft or with phased-array. In Fig. 1, an example is given to illustrate the imaging capabilities of an ICE catheter.

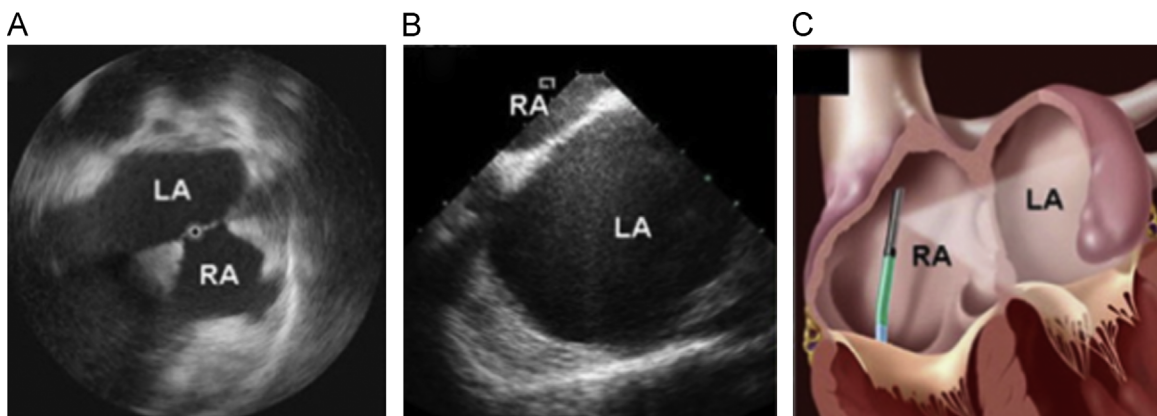
#### 2.1.3. IVUS (intravascular ultrasound)

Similar to the ICE catheters, IVUS catheters employ a rotational single-element ultrasound transducer or phased array to image from inside of the blood vessels. It allows the applications of ultrasound technology to see from inside the blood vessels out through the surrounding blood, visualizing the endothelium of blood vessels, particularly for coronary arteries. It can help to assess the free lumen and plaque area, estimate the volume and provide guidance for the stent placement. Fig. 2 shows an IVUS grayscale image in polar and Cartesian coordinates along with an example of a cut in the longitudinal pullback direction [11].

Another interesting aspect about IVUS is that this is an application where the ultrasound tissue characterization is extensively studied, including the pioneer application for pattern classification and machine learning technologies. For example, automatic segmentation algorithms are needed to delineate the vessel wall and lumen borders. Various classification methods are invented to be able to differentiate plaques. In Section 3.1 we will give a more detailed overview of related image interpretation and classification methods. Fig. 3 shows an example where the IVUS echo-diagram is colour-coded based on the classification results.

#### 2.1.4. Therapy monitoring ultrasound

In addition to the more established clinical applications, we can also envision new emerging applications using the in-body ultrasound imaging tailored for specific application needs. In [5], we have combined imaging ultrasound transducers and therapeutic functions in a single RF ablation catheter, as shown at the left of Fig. 4. The catheter is designed for treating atrial fibrillation in minimally invasive electrophysiological procedures [13–16]. The aim of the imaging is to provide an internal endocardial view for the physicians to monitor the tissue structural change during the ablation procedure. At the right of Fig. 4, we have shown an example M-Mode ultrasound image which visualizes in real-time a right ventricle endocardial lesion. The red line indicates the change in ultrasound tissue contrast upon the energy delivery.



**Fig. 1.** (A) Rotational view of the right atrium (RA), left atrium (LA), and interatrial septum using a rotational ICE catheter. (B) 2D view of the interatrial septum using a phased-array ICE catheter. (C) Schematic drawing of a phased-array ICE catheter in the RA in the optimal position to image the interatrial septum [10].

Download English Version:

<https://daneshyari.com/en/article/412181>

Download Persian Version:

<https://daneshyari.com/article/412181>

[Daneshyari.com](https://daneshyari.com)