



Arab Journal of Urology  
(Official Journal of the Arab Association of Urology)

www.sciencedirect.com



STONES/ENDOUROLOGY  
ORIGINAL ARTICLE

# Holmium laser cystolithotripsy under local anaesthesia: Our experience



Nischith D'Souza, Ashish Verma \*

Department of Urology, Yenepoya Medical College and Hospital, Derlakatte, Mangalore, Karnataka, India

Received 9 February 2016, Received in revised form 31 May 2016, Accepted 9 June 2016

Available online 11 July 2016

## KEYWORDS

Holmium laser;  
Laser cystolithotripsy;  
Local anaesthesia;  
Transurethral

## ABBREVIATIONS

HLC, holmium laser  
cystolithotripsy;  
KUB, plain abdominal  
radiograph of the  
kidneys, ureters and  
bladder;  
US, ultrasonography

**Abstract Objective:** To investigate the feasibility and effectiveness of transurethral holmium laser cystolithotripsy (HLC) under local anaesthesia using a flexible cystoscope.

**Patients and methods:** A prospective study was undertaken from January 2013 to June 2015. In all, 37 men with bladder calculi underwent HLC under local anaesthesia, preferably in a lithotomy position using a flexible cystoscope, followed by per urethral Foley catheter placement postoperatively.

**Results:** The mean (SD; range) patient age was 46.6 (5.6; 32–76) years. All patients were rendered stone-free, regardless of stone size. The mean (SD; range) stone size was 2.1 (1.2; 1.4–4.1) cm and operative time was 35 (6; 26–52) min. The whole procedure was well tolerated and there were no major intraoperative complications. The mean (SD; range) hospital stay was 2.4 (1.5; 1–5) days. After a mean follow-up of 6 months, no recurrent stones, urinary retention or urethral strictures had developed.

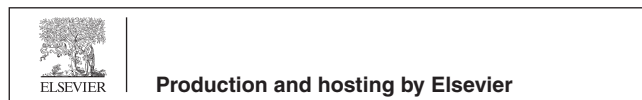
**Conclusions:** Transurethral HLC using a flexible cystoscope under local anaesthesia is a safe and effective technique for the treatment of bladder calculi and can be used as an alternative treatment option.

© 2016 Arab Association of Urology. Production and hosting by Elsevier B.V. This is an open access article under the CC BY-NC-ND license (<http://creativecommons.org/licenses/by-nc-nd/4.0/>).

\* Corresponding author. Fax: +91 8242204690.

E-mail address: [doctorashishverma@gmail.com](mailto:doctorashishverma@gmail.com) (A. Verma).

Peer review under responsibility of Arab Association of Urology.



## Introduction

Bladder calculi management has developed greatly in recent years. Methods currently available include pneumatic or laser transurethral cystolithotripsy, percutaneous cystolithotripsy, cystolitholapaxy, extracorporeal shockwave lithotripsy (ESWL), and open surgery.

The holmium laser has revolutionised urinary lithiasis management, with several trials demonstrating its superiority over other methods for stone clearance with dusting and minimal mucosal damage [1–5].

Generally, transurethral cystolithotripsy is performed under general or spinal anaesthesia. But some patients, especially elderly patients with cardiac and/or pulmonary co-morbidities, are not fit to be administered general or regional anaesthesia. Similarly, patients with spinal deformities, pelvic implants or hip joint pathologies are difficult to position in the lithotomy position, making transurethral procedures difficult. With the above background, the present study was performed to evaluate the feasibility of holmium laser cystolithotripsy (HLC) under local anaesthesia using a flexible cystoscope.

### Patients and methods

A prospective study was undertaken from January 2013 to June 2015. In all, 37 men with bladder calculi of various sizes, regardless of aetiology, were included in the study. All patients were counselled about the potential benefits of undergoing transurethral HLC under local anaesthesia, and written consent was obtained.

Elderly patients with prostate enlargement and vesical calculi, who were not fit or refused to undergo TURP, were included, but patients with urethral stricture and those who consented for simultaneous TURP and those with stones of >4 cm were excluded from the study.

Preoperatively, patients were evaluated with history and physical examination, routine laboratory investigations including: complete blood count, urine routine, renal function test, coagulation profile, serology, and urine culture. Radiological investigations included plain abdominal radiograph of the kidneys, ureters and bladder (KUB) and ultrasonography (US). Patients with a UTI were treated with antibiotics and all patients had a sterile urine culture before the procedure.

Patients were placed in the lithotomy position, except for five patients who had pelvic or spine conditions and thus were operated upon in the supine position. Lignocaine 2% gel was used as the local anaesthetic agent, which was instilled and a penile clamp was applied for 10 min. A flexible cystoscope (Richard Wolf) was introduced and stones were visualised and dusted with a 100-W holmium laser (VersaPulse Power Suite, Lumenis), using a 365- $\mu$ m laser fibre with an energy setting of 0.5–0.8 J at 30–40 Hz. The bladder was regularly emptied by connecting the cystoscope to an aspirator, to prevent excessive bladder distension during the procedure and to clear the stone dust. The flexible cystoscope has a conical irrigation channel; the distal tip is narrowest, measuring 2.5 mm, and becomes broader proximally. Hence, stone dust entering the channel

during suction, will never block the lumen. At the end of the procedure, a three-way 18-F Foley catheter was placed and the bladder irrigated to clear the residual fragments.

Stone clearance was assessed by US on the first postoperative day. Complete clearance was defined as absence of any significant stone fragments on US.

Pain intensity was recorded using a visual analogue scale (VAS) from 0 to 10 (0, no pain; 10, worst possible pain). The catheter was removed after 3–4 h of irrigation. The patients were discharged when they were able to void normally without the catheter. They were followed-up with US and KUB at 6 months.

### Results

In all, 37 patients were enrolled in the study. The mean (SD; range) patient age was 46.6 (5.6; 32–76) years. The mean (SD; range) stone size was 2.1 (1.2; 1.4–4.1) cm. Six patients had multiple stones and three patients (8.1%) had radiolucent stones. All patients underwent HLC under local anaesthesia and complete stone clearance was achieved in all (100%). Eight patients had an American Society of Anesthesiologists (ASA) grade of  $\geq$ III. In five patients, where the lithotomy position was difficult due to various conditions of the hip joint and spine, the procedure was done in the supine position.

The mean (SD; range) operative time was 35 (6; 26–52) min. There were no major complications during the surgery and patient's vital parameters remained within normal ranges. Slight haematuria was seen due to minor mucosal injuries that resolved by irrigation, without any episode of clot retention in any patient. None of the patients received any blood transfusion as a result of the procedure. Three patients had an episode of mild fever that resolved with conservative management.

The Foley catheter was removed after 3–4 h of irrigation. Most of the patients (26, 70.3%) reported passage of stone fragments for the first few voids after removal of the Foley catheter. Postoperative oral analgesics (tramadol 50 mg) were offered, on demand, but rarely required.

All patients tolerated the procedure well with a mean (SD; range) VAS score of 2.8 (1.1; 2–4). None of the patients required an additional dose of analgesia during the procedure. The mean (SD; range) hospital stay was 2.4 (1.5; 1–5) days. Seven patients with benign prostatomegaly needed to be re-catheterised after removing the Foley catheter on the first postoperative day, which was then removed after 72 h of the initiation of  $\alpha$ -blockers.

The mean (SD; range) follow-up was 6 (0.3; 5–7) months. During this period, none of the patients had urethral strictures, stone recurrence or retention of urine.

Download English Version:

<https://daneshyari.com/en/article/4267904>

Download Persian Version:

<https://daneshyari.com/article/4267904>

[Daneshyari.com](https://daneshyari.com)