

## Penile Traumatic Neuroma: A Late Complication of Penile Dorsal Neurotomy to Treat Premature Ejaculation



Hyun Jun Park,<sup>1</sup> Tae Nam Kim,<sup>1</sup> Seung Ryong Baek,<sup>1</sup> Kyung Min Lee,<sup>1</sup> Kyung-Un Choi,<sup>2</sup> and Nam Cheol Park, MD, PhD<sup>1</sup>

### ABSTRACT

**Introduction:** Traumatic neuroma is a reactive process caused by the regeneration of an injured nerve that usually forms a nodular proliferation of small nerve bundles. Penile traumatic neuroma is rare; only a few cases related to circumcision have been reported.

**Aim:** To report on a case of traumatic neuroma in the penis after selective dorsal neurotomy (SDN) to treat premature ejaculation.

**Methods:** The penile traumatic neuroma was successfully removed by excision and confirmed by histopathology.

**Results:** A 55-year-old man who had had several painless, slow-growing nodules on his penis for 2 years presented to our hospital. He had no history of genital trauma, urinary tract infection, or penile surgery, except SDN to treat premature ejaculation. The nodules were excised and the final diagnosis was traumatic neuroma. No recurrence has been detected during 1 year of follow-up.

**Conclusion:** The main complications of SDN are recurrence of premature ejaculation, pain or paresthesia on the glans penis, and erectile dysfunction. However, no traumatic neuroma has been reported as a complication. We report that a traumatic neuroma can occur after SDN.

*Sex Med* 2016;4:e221–e224. Copyright © 2016, The Authors. Published by Elsevier Inc. on behalf of the International Society for Sexual Medicine. This is an open access article under the CC BY-NC-ND license (<http://creativecommons.org/licenses/by-nc-nd/4.0/>).

**Key Words:** Neuroma; Penis; Premature Ejaculation; Trauma

### INTRODUCTION

Traumatic neuroma is a reactive and regenerative process caused by nerve injury. It forms a nodular proliferation arising from the hyperplasia of axons and nerve sheaths after nerve injury or resection.<sup>1–3</sup> Traumatic neuroma is a disorganized growth of the proximal portion of an injured or resected nerve; it can occur in any lesion, but few have been reported in the penis.<sup>2</sup> Most reported cases of traumatic neuroma in the penis have been associated with unintended trauma to the nerve during circumcision.<sup>3</sup> However, no reports have been published on traumatic neuroma from nerve resection in the penis to treat premature ejaculation

(PE). PE is a common male sexual dysfunction that can be treated with psychological counseling, selective serotonin reuptake inhibitors, topical anesthetic creams (TAs), tramadol, or phosphodiesterase type 5 inhibitors. Until recently, surgical management of PE (eg, selective dorsal neurotomy [SDN]) has not been recommended because it can cause permanent sexual dysfunction, and related data about SDN are sparse.<sup>4</sup> SDN is the second most popular treatment performed by Korean urologists in private clinics for patients who show no effect from TAs or who exhibit hypersensitivity of the penile glans.<sup>5</sup> The most common complications of SDN of the penis are recurrence of PE, pain or paresthesia of the glans, ejaculatory dysfunction, erectile dysfunction (ED), wound dehiscence, scarring, and penile curvature.<sup>5</sup> However, there have been no reports of traumatic neuroma forming after SDN. We present the first case of traumatic neuroma of the penis, which occurred after SDN to treat PE.

### CASE PRESENTATION

A 55-year-old man with a 2-year history of several painless, slow-growing nodules on his penis presented to our hospital. Several nodules (5 mm in diameter) were detected on the body of

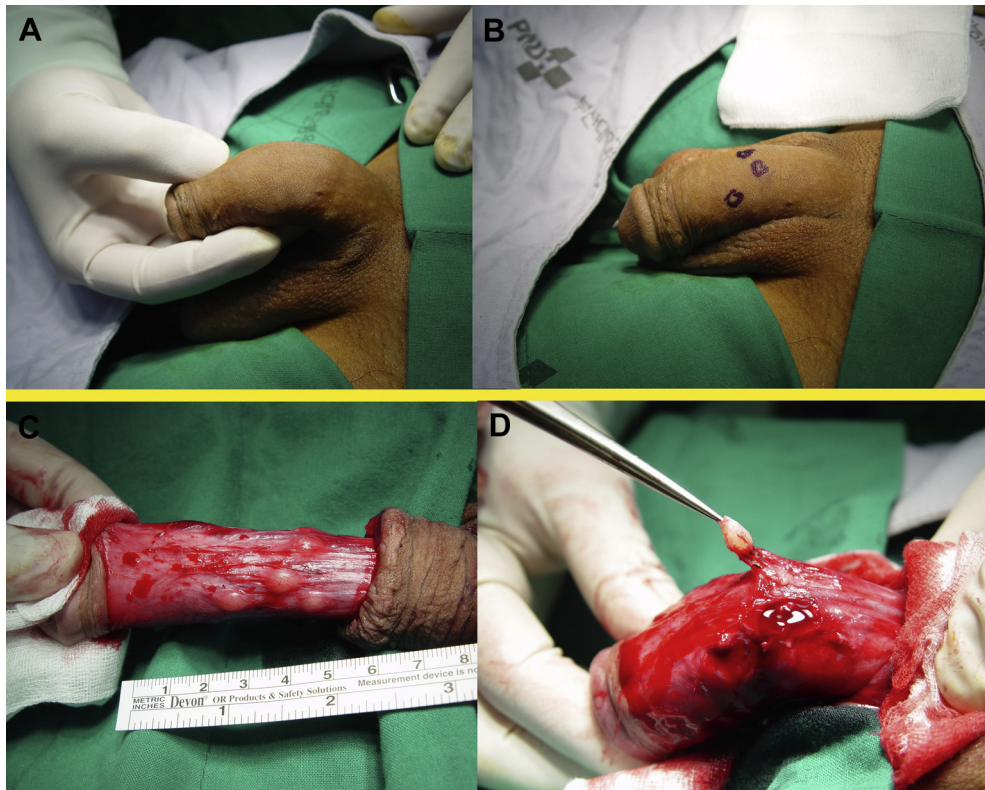
Received February 27, 2016. Accepted April 14, 2016.

<sup>1</sup>Department of Urology, Pusan National University School of Medicine, Busan, Korea;

<sup>2</sup>Department of Pathology, Pusan National University School of Medicine, Busan, Korea

Copyright © 2016, The Authors. Published by Elsevier Inc. on behalf of the International Society for Sexual Medicine. This is an open access article under the CC BY-NC-ND license (<http://creativecommons.org/licenses/by-nc-nd/4.0/>).

<http://dx.doi.org/10.1016/j.esxm.2016.04.003>



**Figure 1.** Panels A and B depict small nodules on the dorsal side of the penile shaft. Panels C and D show intraoperative photographs of the nodules after retraction of the penile skin overlying the lesions.

the penis during a physical examination. The patient had no history of genital trauma, urinary tract infection, or invasive procedures or surgery except for SDN to treat PE. Several branches of the 2 sides of the dorsal nerve were cut during the SDN performed at a private clinic 3 years previously. The nodules were recognized 1 year after SDN, but they were small and no pain or symptoms had occurred; thus, the patient did not visit the hospital. The nodules on the dorsal surface of the penile shaft had increased slowly in size and number during the past 2 years, so the patient presented to the hospital because of fear of malignancy and esthetic concerns.

Before visiting our hospital, penile condyloma acuminatum was suspected in a general practice clinic, but the nodules differed from typically appearing condyloma acuminatum, and the patient was transferred to our hospital for further evaluation. A physical examination at our hospital showed several solid, mobile nodules on the dorsal side of the penile shaft with no inflammation. The lesions were completely asymptomatic. The results of blood tests, urinalysis, and a urine culture were within normal ranges. The nodules were located beneath the deep fascia of the penis (Buck fascia), and all were excised under regional anesthesia (Figure 1).

Histologic examination of a section stained with hematoxylin and eosin showed an epidermis with no sign of acanthosis or papillomatosis and a well-circumscribed lesion composed of small nerve fascicles enveloped in a myxoid stroma (Figure 2).

The final diagnosis was traumatic neuroma. No recurrence was detected during 1 year of follow-up.

## DISCUSSION

The neuroma is a proliferation of Schwann cells and axonal components of nerve tissue. Neuromas can be categorized as traumatic, amputation, or palisade-encapsulated neuromas. Traumatic neuroma involves the regenerative proliferation of injured or traumatized nerve fibers. A palisade-encapsulated neuroma is a hamartomatous proliferation of nerve tissue with no apparent preceding injury.<sup>2</sup> Traumatic neuromas are characterized clinically as solid papules or nodules, and the surgical scars or amputated lesions are skin colored or erythematous-purplish in appearance.<sup>2</sup> The initial lesions usually begin with no specific symptoms, but pain or paresthesia can develop during the course of months to years after onset. The patient in this case did not present any symptoms related to the lesions.

The first report of penile traumatic neuroma was in 1990 by Montgomery et al<sup>6</sup> Since then, three cases, by Brehmer-Anderson<sup>7</sup> in 1999 and one case by Rossi and Franchella<sup>1</sup> in 2005, have been reported. A case series study in 2009 by Salcedo et al<sup>3</sup> reported that traumatic neuromas are caused by circumcision or biopsies. The case of a 23-year-old man reported in 2009 by Marinho and Bouscarat<sup>8</sup> also was a traumatic neuroma secondary to circumcision.

Download English Version:

<https://daneshyari.com/en/article/4274489>

Download Persian Version:

<https://daneshyari.com/article/4274489>

[Daneshyari.com](https://daneshyari.com)