



Endourology

Laparoscopic Nephron-sparing Treatment of Upper Pole Infundibular Obstruction due to Fraley's Syndrome



Joseph M. Armstrong, Samit D. Soni, Richard E. Link*

Scott Department of Urology, Baylor College of Medicine, 7200 Cambridge St., 10th Floor Urology Suite B, Houston, TX 77030, USA

ARTICLE INFO

Article history:

Received 10 September 2015

Accepted 16 September 2015

Available online 21 October 2015

Keywords:

Laparoscopy

Kidney reconstruction

Obstruction

Fraley's syndrome

ABSTRACT

Fraley's syndrome results from a rare anatomic variant of the renal vasculature leading to compression of the upper pole infundibulum, caliectasis, hematuria, and flank pain. To date there have been few reported cases in which this condition was treated using a minimally invasive approach. Here, we report a case in which a patient with Fraley's syndrome was successfully treated by performing a laparoscopic YV-infundibulo-pyeloplasty with vasculopexy of a posterior segmental renal artery. Minimally invasive collecting system reconstruction without vascular clamping is feasible, potentially less destructive and offers significant advantages in terms of intraoperative visualization and perioperative patient morbidity.

© 2016 The Authors. Published by Elsevier Inc. This is an open access article under the CC BY-NC-ND license (<http://creativecommons.org/licenses/by-nc-nd/4.0/>).

Introduction

Fraley's syndrome results from a rare anatomic variant of the renal vasculature that compresses the upper pole infundibulum resulting in calyceal obstruction and symptoms of flank pain and hematuria. In 1966, Elwin Fraley described four patients who presented with symptoms of unexplainable nephralgia. Imaging studies showed upper pole caliectasis and infundibular filling defects suggestive of infundibular obstruction. Surgical exploration confirmed that compression of the upper pole infundibulum by a branch of the renal vasculature was responsible. Various surgical options were employed to resolve these symptoms. In one case, re-anastomosis of the infundibulum ventral to the obstructing vessels immediately resolved the symptoms. In a second case, vasculopexy to reposition the offending artery was successful. The remaining two cases required upper pole partial nephrectomy.¹ Later authors have described a variety of open surgical techniques for addressing infundibular obstruction in the setting of Fraley's syndrome. Several authors have described open nephron-sparing approaches including infundibulo-infundibulostomy, infundibulo-pyelostomy, infundibuloplasty with vasculopexy, vasculopexy with nephropexy, and ligation of a branch of the posterior segmentary artery.^{2,3} One author described a less invasive novel approach through insertion of a percutaneous Palmaz prosthesis into the infundibulum as a nephrostomy.⁴

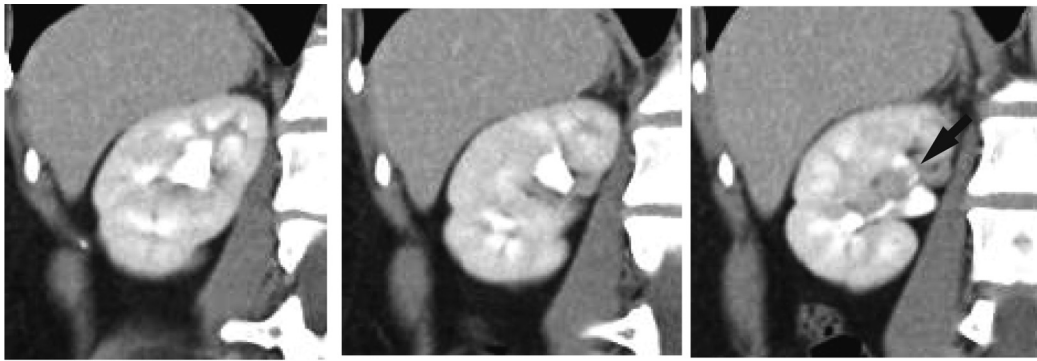
To date, however, there have been no descriptions of nephron-sparing laparoscopic or robotic-assisted laparoscopic correction of Fraley's syndrome.

Case description

A 34-year old Hispanic woman initially presented after a screening urinalysis detected microscopic hematuria. Work-up with cystoscopy revealed no abnormalities and voided cytology was negative. Abdominal CT suggested the possibility of a crossing vessel at the right upper pole infundibulum (Fig. 1). The patient reported intermittent mild right-sided flank pain, which was initially managed conservatively. However, over the following 2 years, her flank pain became more pronounced and she returned complaining of constant pain that interfered with daily activities. A nuclear renal scan demonstrated persistent tracer trapped in the right upper pole calyx although the remainder of the kidney drained promptly. Given her worsening symptoms, she was taken for cystoscopy and ureteral stent placement into the right upper pole calyx. Her symptoms immediately resolved with stent insertion. A plan was therefore made for definitive renal reconstruction. At the time of surgery, the stent was removed and a retrograde pyelogram demonstrated upper pole caliectasis with a filling defect corresponding to a vascular impression on the infundibulum (Fig. 2). Ureteroscopy demonstrated a compressed infundibulum with arterial pulsation over the anterior and posterior aspects. Renal exploration was then undertaken laparoscopically and the patient was found to have anterior and posterior crossing arterial branches obstructing

* Corresponding author. Tel.: +1 713 798 7670; fax: +1 713 798 5553.

E-mail address: link@bcm.edu (R.E. Link).



Posterior ————— Anterior

Figure 1. Contrast enhanced CT scan showing crossing vessel (black arrow) at upper pole infundibulum.

the upper pole infundibulum. With the visualization advantages of the laparoscope, it was not necessary to perform a nephrotomy and clamp the renal artery in this case. A laparoscopic YV-infundibulo-pyeloplasty was initially carried out using 4-0 absorbable sutures in order to expand the diameter of the infundibulum and pull it away from the offending artery (Fig. 3). We felt that performing a transection of the infundibulum and a spatulated anastomosis transposed in front of the anterior renal artery branch was not technically feasible in this case. Next,

vasculopexy of the right posterior segmental renal artery was completed using 4-0 absorbable sutures. The vessel was pulled inferiorly to eliminate the scissor-like mechanism that was obstructing the infundibulum between the anterior and posterior arteries. A 7-French \times 30 cm double-J ureteral stent was placed into the upper pole calyx, and was removed at 6 weeks post-operatively. The patient remains completely pain-free 8 months after the procedure.

Discussion

Fraley's syndrome is a rare cause of hematuria and nephralgia resulting from compression of the upper pole infundibulum by a branch of the renal vessels. The mechanism appears similar to that causing ureteropelvic junction obstruction in the setting of a lower pole crossing vessel. Various treatment methods have been employed successfully to eliminate symptoms, usually requiring open surgical exploration. One technique involves transection of the compressed infundibulum and reanastomosis to itself or to the renal pelvis after repositioning in a manner that relieves vascular compression. Another specifically targets the offending vessel and attempts to reposition it via attachment to a non-obstructing location or manipulation of the kidney to alter the angle of the vessel on the infundibulum. As in the case described above, multiple techniques may be employed to free compression of the upper pole infundibulum, based on the anatomy found at the time of surgical exploration.

Traditional open surgical techniques to treat Fraley's syndrome often involve a nephrotomy, which may require vascular clamping to control bleeding and maintain visualization. Some successful surgical approaches required upper pole nephrectomy with resulting loss of functional kidney parenchyma. The only previously published report of laparoscopic management of Fraley's syndrome involved ligation of the infundibulum and exclusion of the upper pole calyx.⁵ Here we present a case in which a minimally invasive technique was applied that required no renal ischemia or resection of normal kidney parenchyma.

A laparoscopic approach offers significant advantages over open surgery for visualizing the renal pelvis and upper pole infundibulum. Standard or robotic-assisted laparoscopy affords the surgeon the ability to look directly into the renal hilum between structures under magnification. Thus, a complex reconstruction of the collecting system can be performed in some cases without renal ischemia or a nephrotomy. Pneumoperitoneum also minimizes bleeding and improves visualization during

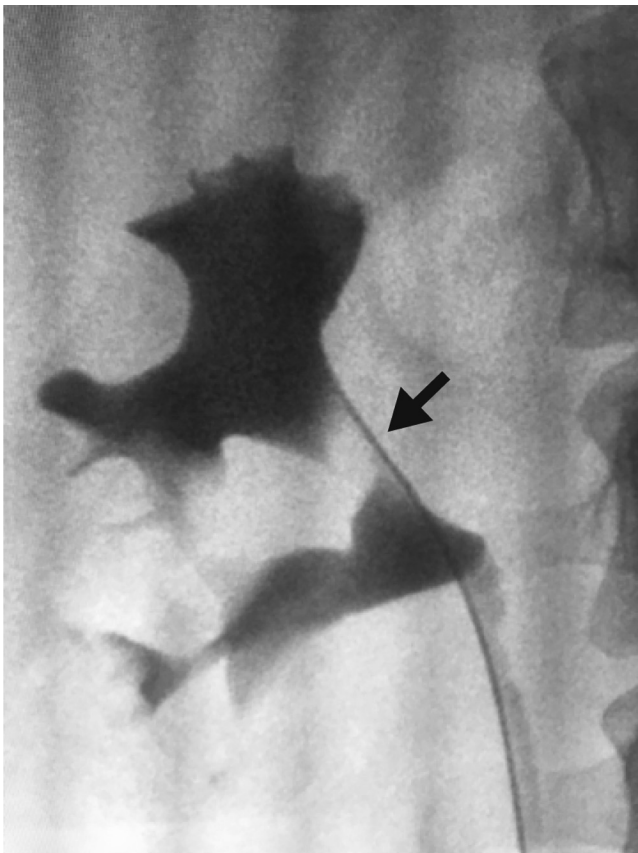


Figure 2. Retrograde pyelogram of the right kidney demonstrating caliectasis and obstruction of the upper pole infundibulum. Note the vascular impression overlying the infundibulum (black arrow).

Download English Version:

<https://daneshyari.com/en/article/4276653>

Download Persian Version:

<https://daneshyari.com/article/4276653>

[Daneshyari.com](https://daneshyari.com)