



Death by heroin intoxication in a body pusher with an innovative packaging technique: case report and review of the literature



Sindi Visentin^{a,*}, Greta Bevilacqua^a, Chiara Giraudo^b, Caterina Dengo^b,
Alessandro Nalesso^a, Massimo Montisci^a

^a Department of Legal and Occupational Medicine, Toxicology and Public Health, University-Hospital of Padova, Via Falloppio 50, 35128, Padova, Italy

^b Institute of Radiology, University-Hospital of Padova, Via Giustiniani 2, 35128, Padova, Italy

ARTICLE INFO

Article history:

Received 7 July 2017

Accepted 29 August 2017

Available online 8 September 2017

Keywords:

Body pushing

Body packing

PMCT

Heroin

Death

ABSTRACT

Death due to mechanical or chemical intoxication of heroin body packers, thanks to the continuous improvement in packaging techniques, are increasingly rare, and almost all the cases reported in the literature refer to drug swallowers. A case of fatal acute heroin intoxication in a body pusher with an unreported packaging technique is presented, and previous deaths due to heroin body packing are reviewed, taking into consideration imaging techniques performed, cause of death, toxicological analysis on biological and non-biological samples, as well as number, position and type of drug packages identified at the dissection of the body.

The innovative packaging technique found in the present case, constituted by an external multilayer cellophane casing containing 16 smaller packages of hardened heroin powder, each one covered with cigarette paper and multiple layers of heat-sealed cellophane, was probably used to avoid both chemical complications of package rupture and to create a package with morphological and radiological features different from those reported by previous studies.

Drug dealers, in fact, are continually looking for packaging methods that, besides being safer, minimize the risk of detection at the radiological examinations performed, thus increasing the number of false negative findings. The identification of new types of package is therefore important, in order to identify packages that do not have the typical radiological signs, both in order to protect the patient's health and to avoid the non-recognition of a drug carrier.

Despite the presence of multilayer composition of both the smaller and the bigger external coverage, these new types of package did not guarantee the greater safety of the drug dealer.

© 2017 Elsevier B.V. All rights reserved.

1. Introduction

Body packing refers to the internal concealment of illicit drugs by swallowing (*body stuffer*) or insertion into the body cavities, such as the anus or vagina (*body pusher*), for transportation across international borders [1–3]. Heroin, after cocaine, is the second most frequently trafficked drug worldwide. However, death due to package rupture and subsequent heroin intoxication [4–13] or from mechanical complications [10,11,14] are rare, and almost all the cases reported in the literature refer to drug swallowers (i.e. body stuffer) [10].

Despite the spread of the phenomenon, the majority of heroin body packing cases have a benign clinical course [15], and to the best of our knowledge, deaths due to heroin body pushing have not been reported; probably because of the relatively easier retrieval of packets in these locations and the absence of the stresses of peristalsis [10]. Furthermore, the continuous improvement in packaging techniques, the main types of which are defined in the literature [16,17], has greatly reduced the mortality rate of body packers [1,18].

A case of fatal acute heroin intoxication in a body pusher with an innovative packaging technique is presented, and previously reported deaths due to heroin body packing are reviewed, considering imaging techniques performed, cause of death, toxicological analysis on biological and non-biological samples, and number, position and type of broken and intact drug packages.

* Corresponding author.

E-mail address: sindi.visentin@gmail.com (S. Visentin).

2. Case report

The case involves a 32-year-old Nigerian man who was found dead in his room by his roommate.

2.1. On site inspection and external examination

The corpse, 173 cm in height and 75 kg in weight with an average body size, was found naked on his bed in a prone position.

The external examination of the body revealed foamy whitish material partially solidified in the mouth and nostrils, with abundant leakage of reddish liquid and soiling of the sheet and the underlying floor. Hypostasis was fixed and abundant, fitting with the position in which the corpse was found. Temperature was in equilibrium with the environment (28 °C) and rigor mortis was present and pronounced.

During the on-site inspection, 16 small (12 × 8 mm) and 3 big (40 × 20 mm) packages were found in the room, above a cabinet. Testimonial data suggested that the deceased used to push drug packages into the anus in order to carry illicit substances over the border, but no travel had been reported in the previous weeks.

2.2. Radiological examination

An unenhanced whole body PMCT was performed 23 h after the discovery of the body using a 64 multi-detector scanner, and subsequent multiplanar reconstructions (MPR) were performed. The images were assessed for the presence, number and characteristics of the suspected drug packages in the alimentary tract.

During the abdominal scan, two drug packages were detected at the recto-sigmoid junction, which were further composed by multiple spherical or hyperdense oval packages (Fig. 1), fitting the dimensions of the packages identified during the on-site inspection.

2.3. Autopsy findings

The dissection of the body revealed congested and edematous brain and lungs (weights: brain 1200 g, right lung 700 g, left lung 600 g), and whitish foam mixed with pinkish fluid in the airways.

At the dissection of the gastro-intestinal tract two packages, with the external casing partially ruptured but without any drug leakage, were found trapped at the recto-sigmoid junction (Fig. 2a–c) and another completely disrupted and empty package was found in the rectal ampulla (Fig. 2d).

2.4. Packing techniques

The type of packaging detected in the present case consisted of a larger package (dimension: 20 × 40 mm; weight: 5,5 gr),

containing 16 smaller packages inside (dimension: 12 × 8 mm; weight: 0,3 gr). The external casing was composed of four layers of cellophane, heat-sealed at one end, and each smaller package was made of hardened brown powder covered with a first layer of cellophane, a second layer of cigarette paper, and another two layers of heat-sealed cellophane (Fig. 3).

2.5. Toxicological findings on biological and non-biological samples

Samples of peripheral blood and urine taken during the autopsy were screened for the main classes of drugs of abuse. Confirmation was performed using the procedures routinely applied in the laboratory based on a solid phase extraction of the sample followed by a liquid chromatography tandem mass spectrometry analysis.

The results revealed the presence of high level of 6-monoacetylmorphine (6-MAM), morphine and codeine both in blood and urine samples, the results of the quantitative analyses are reported in Table 1.

The powder inside the packages, analyzed by gas chromatography mass spectrometry, contained heroin (15.5%) and 6-MAM (9.0%).

2.6. Cause of death

The integrated analysis of data derived from the on-site inspection, with autopsy findings and radiological and toxicological results, identified the cause of death in acute heroin intoxication with pulmonary edema, secondary to package rupture and subsequent drug leakage in the rectum. Due to the testimonial and circumstantial data and the position and features of the packets in the gastro-intestinal track, the case was referred to body pushing.

3. Review of the literature

A systematic literature search of articles published until January 2017 was performed using the PubMed database, ScienceDirect Scopus and Easyweb of Science. Search terms were [(“body packer” OR “body stuffer” OR “body pusher” OR “drug carrier” OR “swallower” OR “mule” OR “courier”) AND (“death” OR “fatal”) AND (“heroin” OR “opioids”)]. An analytical evaluation of the studies collected was performed, and references from relevant articles were also reviewed for potential cases. Only cases of death in consequence of mechanical or chemical complication of heroin body packing were included.

Ten articles reporting cases of death due to heroin body packing were identified, for a total of 23 cases, as reported in Table 2. An article reporting a case series of death due to body packing over the course of 10 years [10], reported 36 cases of death due to heroin body packing and 14 cases of death for other causes. However, it

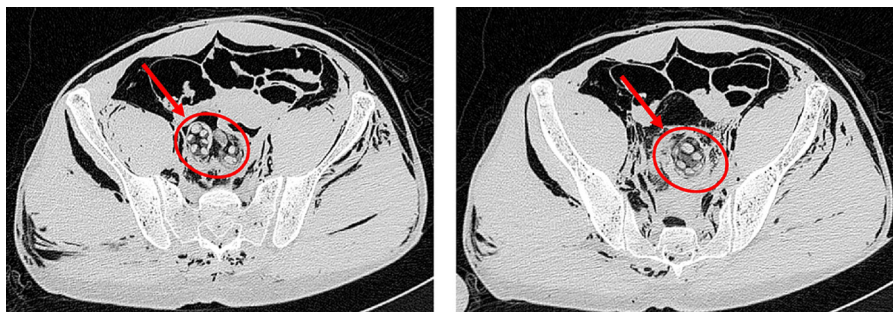


Fig. 1. Postmortem computed tomography. Drug packages composed by multiple spherical or oval hyperdense packages at the recto-sigmoid junction.

Download English Version:

<https://daneshyari.com/en/article/4760227>

Download Persian Version:

<https://daneshyari.com/article/4760227>

[Daneshyari.com](https://daneshyari.com)