A Case Report: Hybrid Treatment Approach to Lipoid Proteinosis of the Larynx

***Zhen Chen, †William Calawerts, *Yi Zhang, *,†Jack Jiang, and ‡Wen Xu,** **Shanghai, China, †Madison, Wisconsin, and ‡Beijing, China*

Summary: Objective. Previous research on treatment of lipoid proteinosis has focused on genetic etiology and clinical diagnosis of this rare laryngeal disorder. However, few studies on this disorder have examined treatment methods directed at improving voice qualities. The purpose of this study was to examine a novel hybrid treatment approach and its improvements in the patient's voice quality.

Study Design and Methods. In this case study, a 27-year-old man complaining of hoarseness of voice and effortful phonation was diagnosed with lipoid proteinosis. He was then prescribed a combination of surgical intervention and voice therapy to improve his overall voice quality.

Results. The results of the posttreatment evaluation demonstrate significant improvements in both objective and subjective voice quality measurements.

Conclusion. A further examination of this hybrid approach in the treatment of lipoid proteinosis is warranted to determine its efficacy.

Key Words: Lipoid proteinosis–Diagnosis–Treatment–Microphonosurgery–Voice therapy.

INTRODUCTION

Lipoid proteinosis is a rare, autosomal recessive disorder characterized by deposition of hyaline materials in the skin and mucosal membrane of the upper respiratory tract.[1–5] In rare cases, the central nervous system, lungs, lymph nodes, and striated muscles are involved.[6–10] Reported clinical symptoms and signs of this disorder include hoarseness of voice, weak crying in infancy, scarring and infiltrated plaques on mucosal surfaces, beaded papules along the eyelid margins, warty skin infiltration, and neuropsychiatric problems such as epilepsy.[3,11–15] The most common symptom of this disease is hoarseness of voice. The irregular deposition of amorphous hyaline material is associated with reduced vocal fold mucosal wave, increased vocal folds mass and stiffness, irregular vocal fold edges, and incomplete glottic closure. Anatomical abnormalities and compensatory behaviors damage the voice of most patients with lipoid proteinosis, and their voice is perceived severely hoarse with increased phonatory effort.[13]

The majority of previous studies regarding lipoid proteinosis focus on genetic etiology, histological description, and clinical diagnosis.[4,16] However, few have addressed the management of lipoid proteinosis. Acitretin, a metabolite of etretinate, is one treatment that has been reported effective for cutaneous and voice improvement in more than 10 patients with lipoid proteinosis.[14,17–19] Other medicines proven effective in dermatological treatment of lipoid proteinosis are only seen in case reports. These medicines include etretinate,[20] glucocoid,[15] neotigason, and D-penicillamine.[21] None of these pharmacological treatment studies aim at directly improving voice quality. Surgically, Harper et al conducted excision of lipoid deposits in a man with lipoid proteinosis and demonstrated improvements in voice hoarseness after the procedure.[1] Xu et al conducted a similar operation on eight severely dysphonic patients with lipoid proteinosis and reported voice improvement of various extents in each of the patients.[13]

Although some pharmacological treatments of lipoid proteinosis have been proven effective, most of them were case studies with small sample sizes. Additionally, for these methods to be effective, patients need to take the medications for 6 months to 3 years and tolerate the side effects induced by long-term medical use.[14,15] Thus, a more efficient treatment approach specific to vocal improvement and with fewer side effects needs to be developed to treat lipoid proteinosis.

In this study, we investigated the voice improvements of an adult with lipoid proteinosis after surgical excision of lipoid deposits combined with voice therapy. We hypothesized that the combination of these treatments would result in significant voice improvements in the patient. If successful, this hybrid approach combining surgical and behavioral management could be applied to all patients with lipoid proteinosis for voice improvement.

CASE REPORT

The patient was a 27-year-old man complaining of persistent hoarseness of voice and effortful phonation since birth. Other complaints included beaded papules along the upper eyelid margins (Figure 1) and rough skin on the cheeks and the forehead (Figure 2), which are visualized in Figures 1 and 2, respectively. He explained that his voice severely affected his quality of life, especially as a student. He also experienced increased depression and stress upon graduating from college as he worked for an information technology company. He smoked for approximately 4 years with average seven to eight cigarettes per day in his early 20s.

Accepted for publication December 13, 2015.

Conflict of interest: None.

From the *Department of Otorhinolaryngology Head and Neck Surgery, The Eye and ENT Hospital of Fudan University, Shanghai, China; †Department of Surgery, University of Wisconsin Madison School of Medicine and Public Health, Madison, Wisconsin; and the ‡Department of Otorhinolaryngology Head and Neck Surgery, Beijing Tongren Hospital, Capital Medical University, Beijing, China.

Address correspondence and reprint requests to Wen Xu, Beijing Tongren Hospital, 1 Dongjiaominxiang, Beijing 100730, China. E-mail: xuwendoc@126.com

Journal of Voice, Vol. 31, No. 1, pp. 128.e15–128.e19

0892-1997

© 2017 The Voice Foundation. Published by Elsevier Inc. All rights reserved.

http://dx.doi.org/10.1016/j.jvoice.2015.12.007

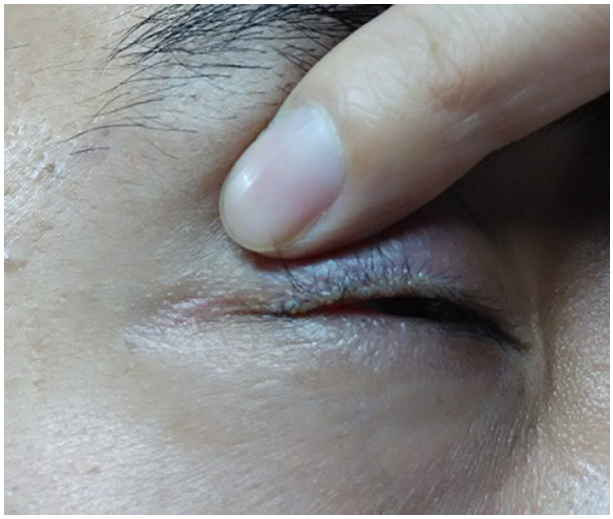

FIGURE 1. Yellowish beaded papules along the upper eyelid margin of the right eye. (For interpretation of the references to color in this figure legend, the reader is referred to the Web version of this article.)

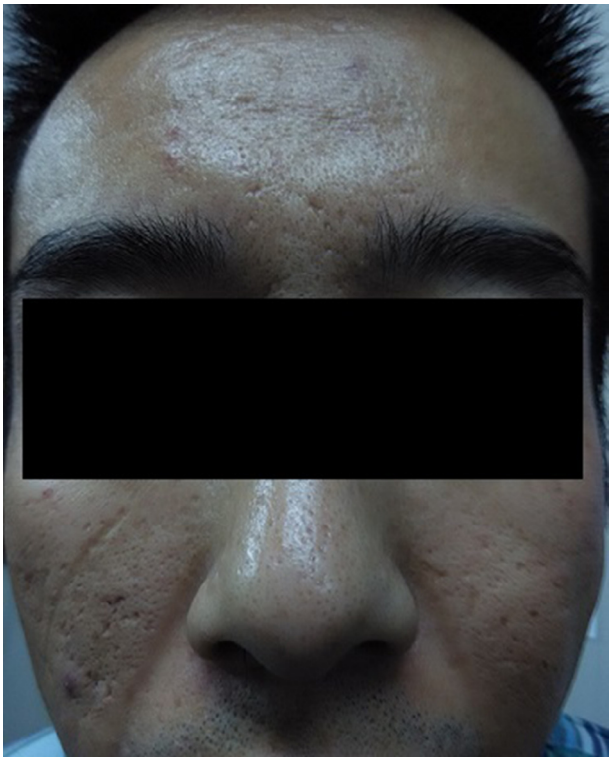

FIGURE 2. Rough skin on the cheeks and the forehead.

Pretreatment assessment

A stroboscopic examination revealed irregularities along the edges and on the surface of bilateral vocal folds, thickening of the interarytenoid regions with diffuse yellowish deposits, irregular anterior and posterior glottal gap, loss of mucosal wave on vocal fold surface, residual mucosal wave at vocal fold edges, and severe supraglottic constriction (Figure 3).An acoustic examination showed short maximum phonation time (9.33 seconds), high fundamental frequency (F0; 360 Hz) in vowel prolongation, high shimmer (7.76%) and jitter (0.86%), low harmonic to noise ratio (HNR) (2.08), high F0 range during vowel gliding (330 Hz–1397 Hz), and high s/z ratio (1.43). The patient's Vocal Handicap Index score was 86. Additionally, the patient received a score of G3R3B3A2S2 on the grade, roughness, breathiness, asthenia, strain (GRBAS) scale, a subjective evaluation method commonly used by clinicians. This score corresponds to severe roughness, severe breathiness, moderate asthenia, and moderate strain.

This patient was referred to a speech-language pathologist with extensive experience in treating voice disorders for behavioral therapy to address supraglottic constriction, effortful phonation, and reduced volume.

Treatment stage one: Presurgical voice therapy

Deactivation exercises were administered and successfully eliminated the patient's shoulder and clavicular tension during inhalation. The patient was subsequently trained for abdominal phonation to increase subglottal pressure. The training of abdominal phonation was modified from the Smith Accent Technique.[22] First, the patient practiced correct abdominal breathing following the clinician's demonstration. Second, the patient was instructed to sustain the production of voiceless (eg, f, s, sh) and voiced fricatives (eg, v, z, zh) with abdominal control. Next, the patient produced fricatives followed by vowels with various tones in Mandarin. For example, the fricative-vowel

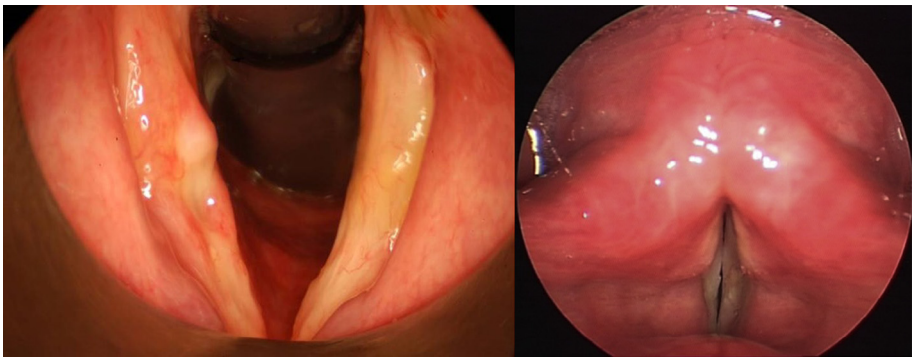

FIGURE 3. Pretreatment vocal fold appearance at abducted position and at closed phase. (For interpretation of the references to color in this figure legend, the reader is referred to the Web version of this article.)

Download English Version:

https://daneshyari.com/en/article/5124365

Download Persian Version:

https://daneshyari.com/article/5124365

Daneshyari.com