ARTICLE IN PRESS

Medical Dosimetry ■■ (2017) ■■–■■

Medical Dosimetry

journal homepage: www.meddos.org

Dosimetry Contribution:

Clinical applications of 3-dimensional printing in radiation therapy

Yizhou Zhao, M.D.,* Kathryn Moran, B.Sc., RT(T),* Mammo Yewondwossen, Ph.D.,† James Allan, B.Sc.,† Scott Clarke, M.Sc.,† Murali Rajaraman, M.D.,* Derek Wilke, M.D., M.Sc.,* Paul Joseph, M.D.,* and James L. Robar, Ph.D.†

*Department of Radiation Oncology, Dalhousie University, Queen Elizabeth II Health Sciences Centre, 5820 University Avenue, Halifax, Nova Scotia B3H 2Y9, Canada; and †Department of Medical Physics, Dalhousie University, Queen Elizabeth II Health Sciences Centre, 5820 University Avenue, Halifax, Nova Scotia B3H 2Y9, Canada

ARTICLE INFO

Article history:
Received 18 January 2017
Accepted 2 March 2017

Keywords:
3D printing
Bolus
Brachytherapy applicator
Modulated electron radiotherapy
Surface brachytherapy

ABSTRACT

Three-dimensional (3D) printing is suitable for the fabrication of complex radiotherapy bolus. Although investigated from dosimetric and feasibility standpoints, there are few reports to date of its use for actual patient treatment. This study illustrates the versatile applications of 3D printing in clinical radiation oncology through a selection of patient cases, namely, to create bolus for photon and modulated electron radiotherapy (MERT), as well as applicators for surface high-dose rate (HDR) brachytherapy. Photon boluses were 3D-printed to treat a recurrent squamous cell carcinoma (SCC) of the nasal septum and a basal cell carcinoma (BCC) of the posterior pinna. For a patient with a mycosis fungoides involving the upper face, a 3D-printed MERT bolus was used. To treat an SCC of the nose, a 3D-printed applicator for surface brachytherapy was made. The structures' fit to the anatomy and the radiotherapy treatment plans were assessed. Based on the treatment planning computed tomography (CT), the size of the largest air gap at the interface of the 3D-printed structure was 3 mm for the SCC of the nasal septum, 3 mm for the BCC of the pinna, 2 mm for the mycosis fungoides of the face, and 2 mm for the SCC of the nose. Acceptable treatment plans were obtained for the SCC of the nasal septum (95% isodose to 99.8% of planning target volume [PTV]), the BCC of the pinna (95% isodose to 97.7% of PTV), and the mycosis fungoides of the face (90% isodose to 92.5% of PTV). For the latter, compared with a plan with a uniform thickness bolus, the one featuring the MERT bolus achieved relative sparing of all the organs at risk (OARs) distal to the target volume, while maintaining similar target volume coverage. The surface brachytherapy plan for the SCC of the nose had adequate coverage (95% isodose to 95.6% of clinical target volume [CTV]), but a relatively high dose to the left eye, owing to its proximity to the tumor. 3D printing can be implemented effectively in the clinical setting to create highly conformal bolus for photon and MERT, as well as applicators for surface brachytherapy.

© 2017 American Association of Medical Dosimetrists.

Introduction

Bolus is commonly employed in high-energy radiotherapy to achieve a desired dose distribution. It is traditionally made from commercial materials such as synthetic oil gel sheets, wet gauze, moldable wax, and thermoplastic sheets or pellets. Sheet bolus is limited with regard to conforming to irregular patient surfaces and is supplied only in specific thicknesses. The use of gauze is subject to daily variation, and its dose buildup depends on wetness.[1] Wax and thermoplastic materials require manual fabrication; in this case, lack of conformity with the patient's surface is often only realized following computed tomography (CT) imaging, making the process iterative and time-consuming. These limitations can result in the presence of air cavities, which can compromise the accuracy of the surface dose,[2-5] which is paramount in the very cases for which bolus is used.

Three-dimensional (3D) printing technology allows the fabrication of detailed volumetric objects of virtually any shape. It is suitable to the production of complex patient-specific boluses and can therefore improve the uniformity of radiotherapy dose distribution over irregular surfaces. Several tissue-equivalent printing materials, such as acrylonitrile butadiene styrene (ABS), polylactic acid (PLA), thermoplastic polyurethane (TPU), and polyvinyl acetate, have been validated for use in radiotherapy. Their physical properties can be accurately modeled in the radiation treatment planning

Funding: This research did not receive any specific grant from funding agencies in the public, commercial, or not-for-profit sectors.

Reprint requests to Yizhou Zhao, M.D., Department of Radiation Oncology, Dalhousie University, Queen Elizabeth II Health Sciences Centre, 5820 University Avenue, Halifax, Nova Scotia B3H 2Y9, Canada.

E-mail: yizhou.zhao@dal.ca

http://dx.doi.org/10.1016/j.meddos.2017.03.001
0958-3947/Copyright © 2017 American Association of Medical Dosimetrists

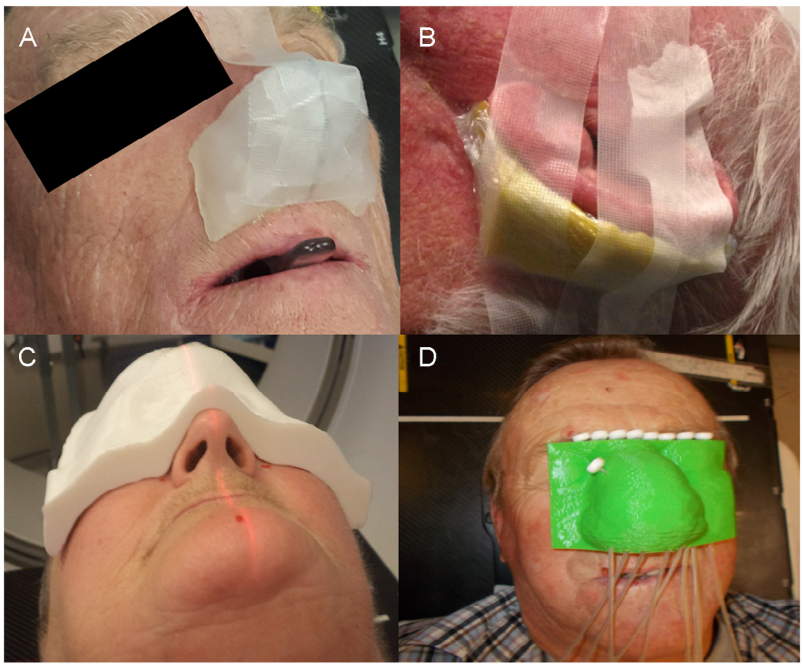

Fig. 1. Patients with their respective 3D-printed bolus. (A) TPU photon bolus for treatment of an SCC of the nasal septum. (B) PLA photon bolus for the treatment of a BCC of the pinna. (C) TPU MERT bolus for treatment of a mycosis fungoides of the face. (D) TPU applicator for HDR surface brachytherapy for treatment of an SCC of the nose.

system, and a limited set of applications has been tested on phantoms. The technology has been characterized with regard to the dosimetric properties of printable media,[6,7] has been applied for the creation of optimized bolus allowing modulated electron radiotherapy (MERT),[8] has been used in producing proton therapy compensators,[9] has been described for intensity-modulated radiation therapy with photon beam,[10] and has been used for the treatment of non-melanoma skin cancer cases.[11] Although these first reports have generated excitement over the potential of 3D printing in radiotherapy, descriptions of application to actual patient treatment and case reports remain sparse.

This report illustrates 4 disparate applications of 3D-printed bolus in modern radiotherapy, each accompanied by a clinical case: an intracavitary photon bolus for a squamous cell carcinoma (SCC) of the nasal cavity, a surface photon bolus for a basal cell carcinoma (BCC) in the posterior pinna, a MERT bolus for a mycosis fungoides involving the face, and a surface brachytherapy applicator for an SCC of the nose (Fig. 1). The aim of this study is to describe and evaluate the implementation of 3D-printed bolus in the clinical setting.

Methods and Materials

The following cases are of patients who underwent radiotherapy treatment at the Nova Scotia Health Authority in Halifax, Canada. Written informed consent was obtained from each individual for inclusion in this study.

3D printing

Two 3D printers were used in this work, namely, the MakerBot Z18 (MakerBot Industries, Brooklyn, NY) and the LulzBot TAZ 5 (Aleph Objects, Inc., Loveland, CO). The properties of each are given in Table 1. A key differentiator is the limiting build dimension. The MakerBot Z18 accommodates 49.3 cm on its build plate, whereas this dimension is 27.4 cm for the LulzBot TAZ 5. In this regard, although both printers are useful for a range of applications to radiation therapy, the LulzBot TAZ 5 may be limited in printing larger boluses. On the other hand, the LulzBot TAZ 5 features a heated print bed to reduce contraction of the printed object and the capacity to print using a wider array of media, including those that are flexible.

PLA and NinjaFlex TPU (NinjaTek, Manheim, PA) were used as printing materials in this work. The print settings used to generate bolus or applicator objects are provided in Table 2. A key requirement is that bolus is printed at 100% infill, to create a solid and homogeneous object. This has been shown to produce a bolus that has radiological properties reasonably close to those of water and can be readily modeled by treatment planning systems, for photon and electron beams.[6,8]

Photon bolus for SCC of nasal septum

A 68-year-old man with an SCC on the left side of the nasal septum had a first resection and reconstruction in 2013, with positive margins. In 2015, he developed a gross local recurrence, manifesting as a nodular lesion involving the caudal 10 mm of the nasal septum biased to the left side, extending into the columella, the left nasal sill, and slightly into the dome of the ipsilateral ala. He underwent a partial rhinectomy, septectomy, and lip resection, with reconstruction. There was a 15-

Table 1
Characteristics of the 3D printers used in this work

Parameters	MakerBot Z18	LulzBot TAZ 5
Maximum extrusion speed (mm/s)	175	200
Maximum print volume (cm^3)	281055	199375
Filament diameter (mm)	1.75	3.0
Printable media	PLA	Various, including flexible TPU
Multiple extruders	No	Yes
Minimum layer thickness (mm)	0.1	0.08
Heated print bed to prevent contraction of print	No	Yes

PLA, polylactic acid; TPU, thermoplastic polyurethane.

Table 2
3D printer settings used to print boluses and applicators in this work

Parameters	PLA	TPU (TAZ 5* only)
Infill (%)	100	100
Layer deposition height (mm)	0.3	0.3
Extruder temperature (°C)	215 (Z18†) 205 (TAZ 5)	230 (TAZ 5)
Print bed temperature (°C)	60 (TAZ 5 only)	Unheated
Extrusion speed (mm/s)	80	18

PLA, polylactic acid; TPU, thermoplastic polyurethane.
* LulzBot TAZ 5.
† MakerBot Z18.

Download English Version:

https://daneshyari.com/en/article/5498172

Download Persian Version:

https://daneshyari.com/article/5498172

Daneshyari.com