

Bronchiectasis Complicating Lung Volume Reduction Coil Treatment



Marie Pierre Debray, MD; Armelle Marceau, MD; Marie Christine Dombret, MD; Vincent Bunel, MD; Sylvie Leroy, MD; Gaëtan Deslée, MD; and Hervé Mal, MD, PhD

Endoscopic lung volume reduction has emerged over the past several years as a promising technique to improve the respiratory functional status of patients with advanced emphysema. Nevertheless, the procedure may be associated with various complications; among them, the development of bronchiectasis related to the coils has not yet been described. We report the case of a patient with emphysema who developed localized bronchiectasis at the site of coil insertion several months after lung volume reduction coil treatment.

CHEST 2017; 152(3):e57-e60

KEY WORDS: bronchiectasis; COPD; lung volume reduction surgery

Endoscopic lung volume reduction (LVR) by lobar instillation of vapor, endobronchial insertion of coils, or unidirectional valves has emerged over the past several years as a promising technique to improve lung function and quality of life in patients presenting with various forms of emphysema-related hyperinflation.¹⁻⁶ In the particular case of endoscopic LVR by insertion of coils, three randomized studies have evidenced a short- to median-term benefit in the LVR groups compared with control groups, but have shown that the procedure may be associated with various side effects.^{1,3,4} Here we report the development of bronchiectasis at the site of coil insertion, a complication that has not been previously described.

Case Report

A 51-year-old man, a former-smoker patient, presented with marked exercise limitation,

severe airflow obstruction with FEV₁ at 800 mL (23% predicted), marked hyperinflation (total lung capacity, 127% predicted; residual volume, 6030 mL [288% predicted]), severely impaired diffusion capacity for carbon monoxide (38% predicted), and homogeneous emphysema on chest CT scan. He underwent LVR coil treatment in 2013, in the setting of a French randomized controlled study (Réduction Volumique Endobronchique par Spirales [REVOLENS]).¹ Two sequential single-lobe insertion of endobronchial coils were performed under general anesthesia using fluoroscopic guidance in the right upper lobe (9 coils) and in the left lower lobe (10 coils) 5 weeks apart (June 2013 and July 2013). On the left side, the lower lobe was chosen as a target lobe instead of the upper lobe because the emphysematous lesions were more severe at this level. There were no complications during the procedure or in the

ABBREVIATIONS: LVR = endoscopic lung volume reduction

AFFILIATIONS: From the Service de Radiologie (Dr Debray), Hôpital Bichat, Assistance Publique Hôpitaux de Paris, Paris, France; Service de Pneumologie B (Drs Marceau, Bunel, and Mal), Hôpital Bichat, Assistance Publique Hôpitaux de Paris, Université Paris 7, INSERM UMR1152, Paris, France; Service de Pneumologie A (Dr Dombret), Hôpital Bichat, Assistance Publique Hôpitaux de Paris, Paris, France; Service de Pneumologie, FHU Oncoage, Université Côte d'Azur (Dr Leroy), CHU de Nice, Nice, France; and Service de Pneumologie (Dr

Deslée), INSERM U903, Hôpital Universitaire de Reims, Reims, France.

CORRESPONDENCE TO: Hervé Mal, MD, PhD, Service de Pneumologie B et Transplantation Pulmonaire, Hôpital Bichat, 46 rue Henri Huchard, Paris 75018, France; e-mail: herve.mal@bch.aphp.fr

Copyright © 2017 American College of Chest Physicians. Published by Elsevier Inc. All rights reserved.

DOI: <http://dx.doi.org/10.1016/j.chest.2017.04.189>

following weeks; the patient was seen in the outpatient clinic on a regular basis thereafter in compliance with the design of the clinical trial. At 6 months after the first procedure involving the right upper lobe, the patient reported a mild improvement in exercise capacity but without any change in the modified Medical Research Council scale (grade 3), and in the 6-min walking distance (240 m). At that time, residual volume had decreased by 1100 mL and FEV₁ remained stable. The patient was also found to be stable at the 12-month visit after the first procedure, but at the 18-month visit described a worsening of his respiratory status (modified Medical Research Council scale grade remaining at 3) and pulmonary function tests. He is presently considered for bilateral lung transplantation, the choice of transplanting two lungs vs one lung being driven by the rather young age of the patient and the presence of bilateral bronchiectasis. Chest CT scan performed in December 2016 during the lung transplantation evaluation process disclosed marked bronchiectasis localized at the site of coil insertion, involving mainly the left lower lung but also to a lesser degree the right upper lobe. The comparison with the previous CT scans showed that bronchiectasis were not present at inclusion before coil insertion and were very mild at 6 months (Fig 1 and Fig 2). The development of bronchiectasis did not lead to recurrent infections or to daily sputum production. A culture of bronchial aspiration performed under fiberoptic endoscopy as part of the pretransplant workup was negative in December 2016.

Discussion

LVR coil treatment is an interesting therapeutic option for patients with either homogeneous or heterogeneous

emphysema and hyperinflation, regardless of the presence of collateral ventilation between lobes. The coils used for endoscopic LVR (PneumRx Inc.) are made of preformed nitinol wire with shape memory. They are launched straight bronchoscopically via the working channel of a flexible bronchoscope and recover to a nonstraight predetermined shape upon deployment. Two recent randomized multicenter studies (REVOLENS and Lung Volume Reduction Coil Treatment in Patients With Emphysema) have demonstrated modest improvement in exercise capacity at 6 and 12 months.^{1,4} They reported a higher incidence of complications in the coil treatment groups compared with the control groups. The main reported adverse effects were COPD exacerbation, hemoptysis, pneumothorax, and pneumonia.^{1,3,4,7} The mechanisms underlying complications are not well understood. Pneumonia is a well-described complication but most often no infectious agents are identified and opacities reverse with steroid therapy, suggesting the involvement of an inflammatory process.^{1,4} The development of bronchiectasis at the site of coil insertion has not been described previously. Whether some of the cases of hemoptysis described in the literature are secondary to local development of bronchiectasis is speculative. Here again the mechanism is unclear: the development of bronchiectasis may result from a reaction of the bronchus wall to the component of the coil, an effect of subsegmental airway closure distal to the insertion site, local ischemia related to bronchial artery kinking or distortion, or from tension-induced inflammation. Bronchial wall inflammation, common in COPD but varying from one patient to another, may favor the development of this coil-induced bronchiectasis.

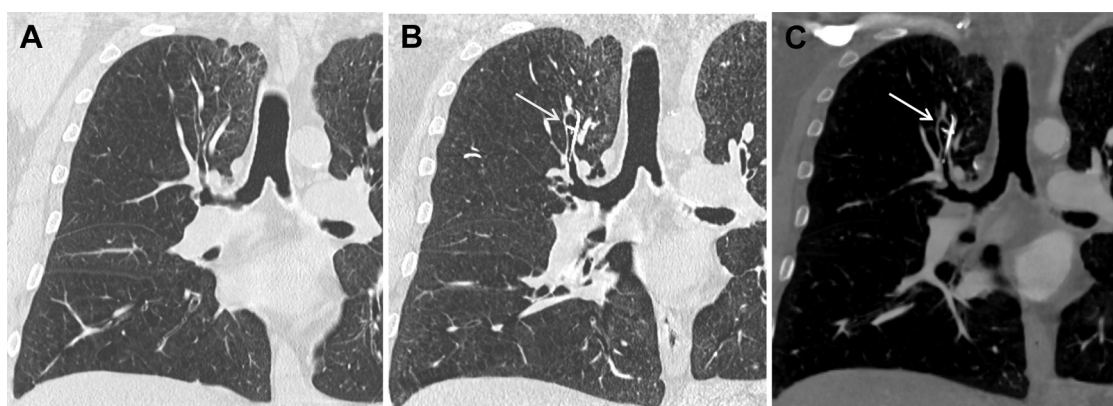


Figure 1 – Unenhanced chest CT scan in the coronal plane through the right upper lobe bronchus, which shows mild irregularities of apical segmental bronchus lumen before insertion of endobronchial coils (A). Three and a half years after endobronchial coils insertion, moderate focal bronchiectasis is seen at the site of one of the coils (arrow), whose proximal tip is in the dilated bronchus in pulmonary window (B) and mediastinal window (C).

Download English Version:

<https://daneshyari.com/en/article/5600298>

Download Persian Version:

<https://daneshyari.com/article/5600298>

[Daneshyari.com](https://daneshyari.com)