



ELSEVIER

CASE REPORT

# Laparoscopic sleeve gastrectomy on a morbidly obese patient with situs inversus totalis: A case study and systematic review of the literature



Mehmet Aziret\*, Kerem Karaman, Metin Ercan,  
Erdal Birol Bostancı, Musa Akoğlu

Sakarya University Faculty of Medicine, Department of General Surgery, Sakarya,  
Turkey

Received 22 July 2016; received in revised form 4 December 2016; accepted 7 December 2016

## KEYWORDS

Morbid obesity;  
Laparoscopic sleeve  
gastrectomy (LSG);  
Situs inversus totalis  
(SIT)

## Summary

**Introduction:** Situs inversus totalis (SIT) is a condition where the internal organs or organ systems are located contra-laterally to the norm, forming a mirror image. Laparoscopic sleeve gastrectomy (LSG) is an effective bariatric procedure that has become more common over the last two decades. We report on a morbidly obese patient with SIT who underwent a successful LSG.

**Case report:** A 54-year-old female morbidly obese patient (136 kg; 167 cm; body mass index (BMI): 48 kg/m<sup>2</sup>) was admitted for bariatric surgery. She had congenital SIT, a history of open cholecystectomy and, despite implementing the suggestions of the dietitian and endocrinologist, she had failed to lose weight. A standard LSG was performed successfully using the French method. The patient's postoperative course was uneventful and she was discharged on the 5th postoperative day. She is now in the 4th month with a weight loss of 30 kg.

**Discussion:** SIT is a rare congenital condition, occurring in 1/10,000 to 1/50,000 live births. Organ function is generally normal, although it may sometimes be accompanied by respiratory or cardiovascular anomalies. Although undertaking LSG on morbidly obese patients with SIT may seem a daunting proposition at first, experienced laparoscopic surgeons can manage this operation with success.

**Conclusion:** Although SIT is a rare congenital condition, LSG can be performed safely and effectively.

© 2016 Asia Oceania Association for the Study of Obesity. Published by Elsevier Ltd. All rights reserved.

\* Corresponding author. Fax: +90 264 275 91 92.  
E-mail address: [mhmtaziret@gmail.com](mailto:mhmtaziret@gmail.com) (M. Aziret).

## Introduction

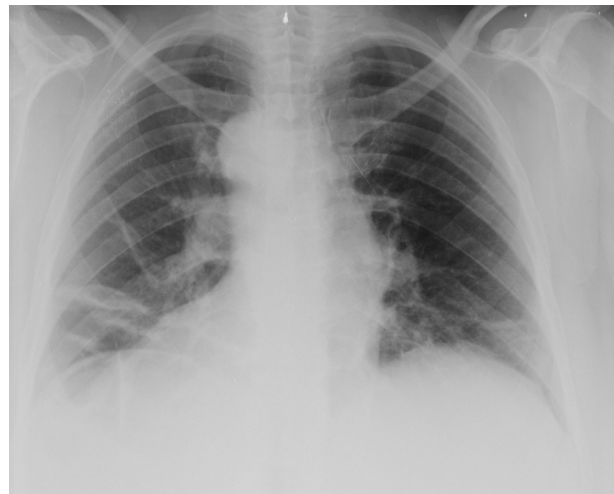
In recent years, morbid obesity has emerged as one of the most important public health issues worldwide, due to increased co-morbidities, including diabetes mellitus, hypertension, metabolic syndrome, and psychosocial impairment with a reduced life expectancy [1]. In morbidly obese patients whose body mass index is above 40 kg/m<sup>2</sup> or higher than 35 kg/m<sup>2</sup> with associated co-morbid diseases [2,3], bariatric surgery has proved to be the treatment of choice. LSG is one of the most commonly performed bariatric procedures, offering a satisfactory weight loss and improvement in hypertension and metabolic and endocrine disorders such as dyslipidemia and diabetes mellitus type 2 [3,4].

Situs inversus is classified in two types: situs inversus partialis (SIP) and SIT. In the case of SIP one or more organs in the abdominal or thoracic cavities is transposed; SIT, however, is a very rare clinical condition in which all organs and tissues are transposed to the opposite side of the body. SIT occurs in 1 in every 10,000 to 50,000 births [5]. Although SIT does not seem to affect normal health or life expectancy, the reverse anatomy may cause technical difficulties when performing surgical procedures [6–8]. Here, we report a successfully performed LSG in a morbidly obese patient with SIT and introduce a systematic review of the literature.

## Material and methods

### Research protocol and strategy

Study identification and data extraction were realized by searching Pubmed, Google Scholar and Researchgate scientific literature databases, using the following search terms: 'obesity', 'morbid obesity', 'bariatric surgery', 'obesity surgery', 'laparoscopic sleeve gastrectomy', 'laparoscopic adjustable gastric band', 'laparoscopic gastric bypass', 'situs inversus totalis'. In addition, additional studies were manually examined for relevant references by trained researchers. The article's title, abstract and full-text were evaluated for inclusion and exclusion criteria. This literature review covers all articles from 1979 to April 2016. The following information was collected: first author of article; publication year; patient's gender, age and preoperative signs; surgical technique and complications; situs inversus partialis or situs inversus totalis. Finally, we formed a search flow diagram based on the data evaluation (Table 1).



**Figure 1** The apex of the heart on the patient's right side shown in chest X-ray.

## Results

### Case report

A 54-year-old female patient with morbid obesity was electively admitted to our clinic for LSG procedure. She was 1.67 m tall and weighed 138 kg (BMI: 48 kg/m<sup>2</sup>). Her medical history revealed SIT, open cholecystectomy, Type 2 diabetes and osteoarthritis. On physical examination, a left subcostal incision scar was seen in the left upper quadrant and cardiac apex beat was found in the right hemi-thorax. Dextrocardia was detected on a plain chest X-ray (Fig. 1). The ear, nose and throat (ENT) examination was normal. Her laboratory tests including white blood cell count (WBC) and blood chemistry tests were within normal ranges. The presence of SIT had initially been discovered during the open cholecystectomy operation undergone 5 years previously and was confirmed by abdominal contrast-enhanced computed tomography (Fig. 2). LSG was planned after an anesthesia consultation with an ASA score of III (American Society of Anesthesiologists). The patient was positioned in reverse Trendelenburg position using the French method (thighs in abduction with the surgeon positioned between the legs). The insertion and location of the trocars was planned according to the mirror image anatomy of the intra-abdominal organs. A CO<sub>2</sub> pneumoperitoneum was established with a Veress needle and maintained at a pressure of 12 mmHg. A 30° viewing laparoscope was introduced through a 10 mm port which was inserted on the superior-lateral right side approximately 10 cm away from the umbilicus and SIT was confirmed under direct visualization. A 15 mm port was then

Download English Version:

<https://daneshyari.com/en/article/5619213>

Download Persian Version:

<https://daneshyari.com/article/5619213>

[Daneshyari.com](https://daneshyari.com)