Epilepsy & Behavior 68 (2017) 66–70

Contents lists available at ScienceDirect

Epilepsy & Behavior

journal homepage: www.elsevier.com/locate/yebeh

Acute and spontaneous seizure onset zones in the intraperitoneal kainic acid model

Phillip Connell [1], Arezou Bayat [1], Sweta Joshi, Mohamad Z. Koubeissi *

Department of Neurology, George Washington University, 2150 Pennsylvania Avenue NW, Washington, DC 20037, USA

ARTICLE INFO

Article history:
Received 18 October 2016
Revised 16 December 2016
Accepted 17 December 2016
Available online 19 January 2017

Keywords:
Kainic acid
Hippocampus
Claustrum
Epilepsy
Seizure

ABSTRACT

Objective: Hippocampal monitoring is often used in the intraperitoneal kainic acid (KA) seizure model for detection and quantification of early ictal activity. Here, we investigated extra-hippocampal seizure onset zones (SOZs) in this model.

Methods: Eight male Sprague Dawley rats implanted with depth electrodes were continuously recorded during intraperitoneal KA injections until status epilepticus (SE) was induced. Another group of four rats was monitored chronically up to two weeks after emergence of spontaneous recurrent seizures. All rats had hippocampal electrodes. Other sampled brain regions included, among others, the claustrum, piriform cortex, and orbital cortex. Seizures recorded with video-EEG were visually analyzed.

Results: In the 58 seizures recorded during KA injections, the SOZ was extrahippocampal in 7 (12%), diffuse in 29 (50%), and hippocampal in 22 (38%). Of the 14 spontaneous seizures recorded, none were solely extrahippocampal, 10 (71%) were diffuse, and 4 (29%) were of hippocampal onset. All extra-hippocampal seizures propagated to the hippocampus within 4 to 50 s (mean = 14, n = 7). No distinctive semiological manifestations correlated with the SOZs.

Significance: We conclude that seizures can have multifocal SOZs in the KA model. This finding is important to consider when using this model, among other purposes, to screen for new therapies, study pharmacoresistance, or investigate comorbidities of epilepsy.

© 2016 Elsevier Inc. All rights reserved.

1. Introduction

The kainic acid (KA) model is a common model of intractable epilepsy. Kainic acid comes from the seaweed plant *Digenea simplex* and was historically used as a treatment for ascariasis [1]. Over time, KA became known as a neurotoxic agent that activates glutamate receptors, and led to the development of a new animal model of temporal lobe epilepsy (TLE) [2]. When injected intraperitoneally in rodents, status epilepticus (SE) can be precipitated and spontaneous seizures usually emerge after a latency phase. SE may be induced through a variety of methods including intracerebral and systemic administration, both of which result in neuropathological changes in the hippocampus [2,3]. Seizures associated with hippocampal [4] and amygdalar [5] damage induced by systemic KA injections resemble human TLE in presentation and pathology [6,7]. Increasing seizure frequency, variation in seizure severity, and the latency phase between injury and the first spontaneous seizure are among the other similarities to human TLE [6]. Currently, researchers often rely on hippocampal depth electrodes to measure early ictal activity as the hippocampus is thought of as a key seizure onset zone (SOZ) in the KA model [2]. Although hippocampal sclerosis is well documented in TLE, extrahippocampal pathology is also present [8], a feature that has also been noted within the KA model [2]. Because the KA model is widely used, including to test the efficacy of antiseizure medications, it is important to identify SOZs in this model. Here, we examine the electrographic seizure onsets during both the acute pre-SE seizures, and later spontaneously recurring seizures, with the goal of describing SOZs.

2. Materials and methods

Adult male Sprague–Dawley rats weighing 250–390 g from Hilltop (Scottdale, PA) were used in this study. All animal procedures were conducted in accordance with the NIH guide for the care and use of laboratory animals (NIH Publications No. 8023) and reviewed and approved by the Institutional Animal Care and Use Committee (IACUC) of George Washington University. All animals were housed individually in conventional cages with 12–12 h light and dark cycle (7 a.m. on/7 p.m. off). Animal chow (Harlan Laboratories, Madison, WI) and water were provided *ad libitum* throughout the study.

2.1. Acute group

Eight rats with depth electrodes were recorded during intraperitoneal injections of KA that were administered every hour until SE

* Corresponding author at: 22nd & I street, NW 9th Floor, Washington, DC 20037, USA.
E-mail address: mkoubeissi@mfa.gwu.edu (M.Z. Koubeissi).

[1] These authors have contributed equally.

http://dx.doi.org/10.1016/j.yebeh.2016.12.017
1525-5050/© 2016 Elsevier Inc. All rights reserved.

was induced (ranging 3–7 h). Six rats were monitored with hippocampal electrodes bilaterally and two unilaterally. The other electrodes (Fig. 1), were implanted in bilateral claustra (n = 2); piriform cortices (n = 2); bilateral corpus callosum (n = 1); bilateral orbital cortices (n = 1); and unilateral suprahippocampal white matter, unilateral orbital cortex, contralateral frontal cortex, unilateral corpus callosum, and unilateral claustrum (n = 1). Of note, the electrodes that were histologically proven to be in the corpus callosum, frontal cortex, and orbital cortex were intended to be implanted in the claustrum; however, their data were included in the analyses as possible sites of seizure origination (Fig. 1) (Table 1).

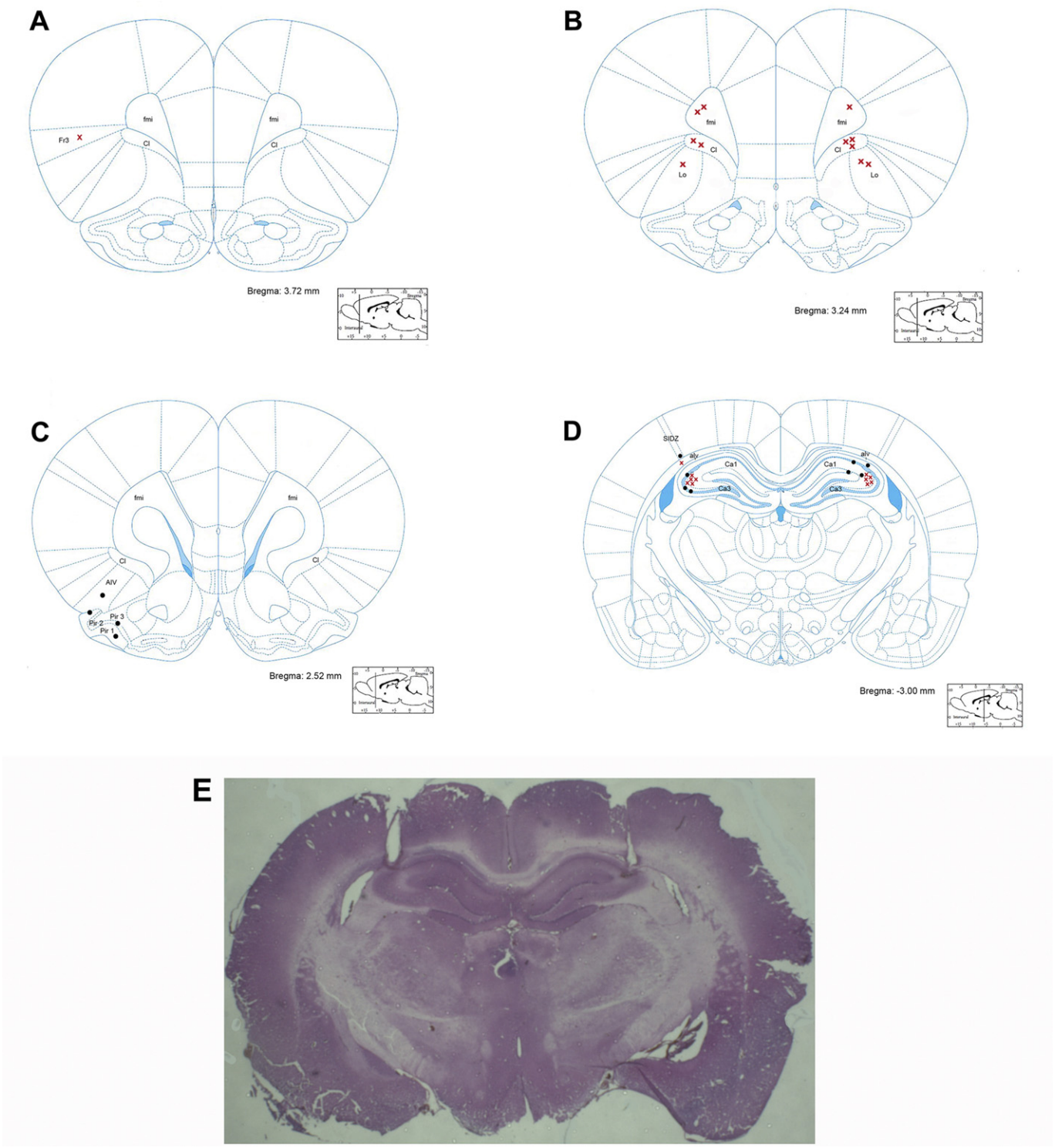

Fig. 1. Histological electrode placements for acute and spontaneous seizure groups. A–D: Electrode placements for acute seizure group (red crosses), and spontaneous seizure group (black dots). Depicted placements were confirmed with histology. 2 animals in the acute group with hippocampal and piriform electrodes are not depicted due to lack of histological confirmation. Schematics borrowed from Paxinos and Watson, 2006. [9] E: Sample histology illustrating electrode placement into bilateral CA3 regions of the hippocampi. Key: AIV: agranular insular cortex (ventral), Alv: alveus of the hippocampus, Cl: claustrum, fmi: forceps minor of the corpus callosum, Fr3: frontal cortex area 3, Lo: lateral orbital cortex, Pir: piriform cortex.

Download English Version:

https://daneshyari.com/en/article/5628061

Download Persian Version:

https://daneshyari.com/article/5628061

Daneshyari.com