

Original Article

Long term results of bone-patella-tendon-bone ACL reconstruction

Max Ettinger^a, Friedel Etter^b, Tilman Calliess^a, Michael Bohnsack^b, Christoph Becher^{c,*}^a Department of Orthopaedic Surgery, Hannover Medical School, Hannover, Germany^b Department Orthopaedic and Trauma Surgery, DIAKO, Bremen, Germany^c International Center of Hip-, Knee- and Foot Surgery, ATOS Clinic, Heidelberg, Germany

ARTICLE INFO

Article history:

Received 4 July 2016

Received in revised form 12 October 2016

Accepted 16 October 2016

Available online 1 November 2016

Keywords:

Knee

Anterior cruciate ligament (ACL)

Reconstruction

Patellar tendon

Long-term follow-up

ABSTRACT

Background: To assess outcomes of bone-patella-tendon-bone ACL-reconstruction at 18 years follow-up. **Material and methods:** Outcome measures included the IKDC clinical examination form and clinical scores. Radiographs were analyzed to determine the grade of osteoarthritis.

Results: 69% of the examined patients ($n = 54$) had a normal/nearly normal knee, 14% were abnormal and 17% severely abnormal with significant improvement ($P \leq 0.001$). The mean Lysholm score was 87.7 ± 12.4 and the Tegner activity level was 5 ± 2 . Osteoarthritic changes were present in 52%.

Conclusion: BPTB ACL-reconstruction provides a satisfactory outcome with a high incidence of radiographic osteoarthritic changes.

© 2016 Prof. PK Surendran Memorial Education Foundation. Published by Elsevier, a division of RELX India, Pvt. Ltd. All rights reserved.

1. Introduction

The anterior cruciate ligament (ACL) is the most commonly injured ligament in the knee, typically after decelerating/pivoting movements during sports. The majority of patients with a torn ACL can run normally, climb stairs and go jogging.¹ ACL reconstruction is indicated if the patient suffers a feeling of instability during everyday activities or when he wants to perform high-risk sports such as soccer or skiing.² The aim of the reconstruction is to re-establish normal joint kinematics and structural integrity while reducing the likelihood of further joint injury or deterioration.³

The term “ACL reconstruction” a very streamlined representation of the procedure since numerous variants exist, including e.g. tunnel placement, graft fixation, and type of graft.^{4–6} The options regarding autograft choice include the autologous bone-patellar-tendon-bone graft, the hamstring tendons (semitendinosus/gracilis) and the quadriceps tendon.⁷

Two recent long-term randomized controlled trial comparing hamstrings versus patellar tendon autograft revealed only minor and mostly insignificant differences between the two graft options with good long-term subjective and objective outcomes.^{8,9} However, the number of studies with patients evaluated at a long-term are still limited.

This study reports the outcomes of bone-patella-tendon-bone (BPTB) ACL reconstruction at 18 years follow-up. The objectives were to evaluate the clinical outcome according to the IKDC clinical examination form compared to the preoperative status, common clinical sores and the determination of the radiographic grade of osteoarthritis.

2. Material and methods

2.1. Patient selection

Between 1994 and 1996, a total of 371 consecutive patients underwent ACL reconstruction according to our database. Patients were selected for this study if an ACL reconstruction with BPTB autograft was performed and the IKDC clinical examination form was completed preoperatively. Patients with multi-ligament injuries, evidence of chondral damage > grade 2, previous or intraoperative meniscal injury of more than one-third of the menisci, abnormal contralateral knee and history of rheumatoid arthritis were excluded. Patients that sustained ACL graft rupture or other severe injuries at the operated or contralateral knee were not invited for clinical examination. Ethics approval (Nr. 2103) was obtained from the local ethical review board prior to the study.

2.2. Surgical procedure

All patients underwent an arthroscopically assisted ACL reconstruction with a BPTB autograft in a transtibial approach

* Corresponding author at: International Center for Hip-, Knee- and Foot Surgery, ATOS Clinic Heidelberg, Bismarckstr. 9–15, 69115 Heidelberg, Germany.
E-mail address: becher.chris@web.de (C. Becher).

for drilling of the femoral tunnel. The central-third patellar tendon graft was harvested through a longitudinal incision. The grafts were fixed with a titanium interference screw both on the femoral side and tibial side. All patients received the same standardized post-operative rehabilitation program. The rehabilitation program included full pain adapted weight bearing after the surgery under flexion limitation until the 21st day after surgery. The return to sports was as follows: (1) after 12 weeks jogging on plane sole. (2) after 6 months sports specific re-integration. (3) after 8–12 months return to sports specific competitions.

2.3. Outcome measures

The IKDC clinical examination form¹⁰ was completed preoperatively and at the follow-up visit. The KT-1000 Arthrometer was utilized for the measurement of the anterior–posterior stability.¹¹ Other outcome measures included the Lysholm score,¹² Tegner activity scale¹³ and rating of satisfaction (1 = poor, 2 = moderate, 3 = good, 4 = excellent) with the treatment outcomes at the time of follow-up.

Radiographic assessment included AP and lateral standing as well as merchant view X-rays. The radiographs were analyzed according to the Kellgren–Lawrence classification¹⁴ and Osteoarthritis Research Society International (OARSI) Grading System¹⁵ to grade the stage of osteoarthritis.

2.4. Statistical analysis

Mean and standard deviation values were recorded. To determine differences between the data of preoperative and follow-up IKDC clinical examination form results, the Wilcoxon nonparametric test (significance, $P \leq 0.05$) was used. Differences at the side-to-side measurements with the KT-1000 Arthrometer were evaluated using a paired *t*-test. Data analysis was performed using GraphPad Prism software (GraphPad Prism Software Inc, San Diego, CA).

3. Results

According to the in- and exclusion criteria, 81 patients were considered for inclusion in the study. 6 patients refused to participate and 21 (26%) patients sustained ACL graft rupture or other severe injury at the operated or contralateral knee leaving 54 patients (10 women and 44 men) for further analysis. 40 patients were clinically examined and 14 only answered the questionnaires. The mean follow-up was 17.7 ± 1.1 years. The mean age at the initial date of surgery was 26.9 ± 6.9 years and 46.0 ± 6.6 at the time of follow up.

According to the IKDC clinical examination form (Fig. 1), 69% of the examined patients had a normal/nearly normal knee (grade A or B) at follow-up. 14% were rated as abnormal (grade C) and 17% as severely abnormal (grade D) with statistically significant improvement ($P \leq 0.001$) compared to the preoperative status (5% grade A or B, 10% grade C and 85% grade D). The mean side-to-side difference at the KT-1000 measurement was 1.9 ± 1.6 mm ($P \leq 0.001$). 8 patients (20%) underwent other secondary arthroscopic procedures for meniscus or cartilage pathologies.

The mean Lysholm score result was 87.7 ± 12.4 . The mean Tegner activity level was 5 ± 2 . The result was rated excellent in 25% of the patients, very good in 31%, good in 36% and moderate in 8%.

The radiographic analysis (Figs. 2 and 3) revealed in 52% of the patients osteoarthritic changes at the time of follow-up with an average Kellgren & Lawrence grade 1.7 ± 0.7 (grade 0–1: 45%, grade 2–3: 55%). The average OARSI grade for osteophyte formation was 1.3 ± 0.6 in the medial compartment and 1.1 ± 0.6 in the lateral compartment.

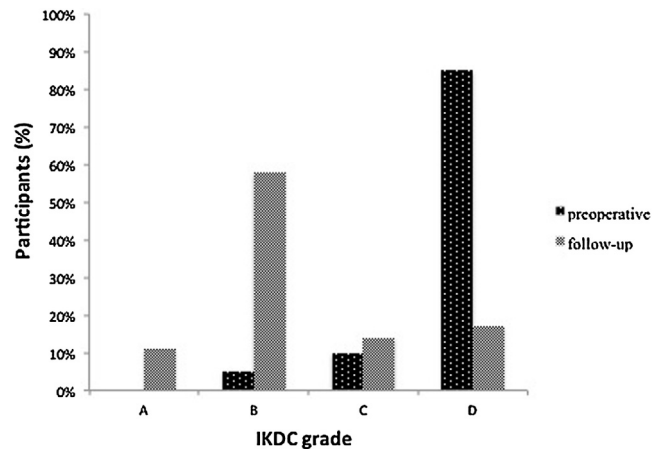


Fig. 1. According to the IKDC clinical examination form, 69% of the examined patients had a normal/nearly normal knee (grade A or B) at follow-up. 14% were rated as abnormal (grade C) and 17% as severely abnormal (grade D) with statistically significant improvement ($P \leq 0.001$) compared to the preoperative status (5% grade A or B, 10% grade C and 85% grade D).

4. Discussion

This study revealed that BPTB ACL-reconstruction provides a satisfactory objective and subjective outcome with respect to the score evaluation at an average follow-up of 18 years. The IKDC clinical examination form results showed a statistically significant improvement compared to the preoperative level with 69% patients graded as “normal” or “nearly normal”. These results, however, are inferior to a long-term evaluation that demonstrated 75% of patients with “normal” and “nearly normal knees” after ACL reconstruction with hamstring autograft at an average follow-up of 14.6 ± 1.9 years.⁷ Even better results were presented with 80% “normal” and “nearly normal” knees with allograft ACL reconstruction at an average follow-up of 10.5 years.¹⁶ However, there is still concern that these results will deteriorate over time since Pernin et al. found in their long-term outcome at an average of 24.5 years of ACL reconstruction with extra-articular augmentation (procedure performed through a medial arthrotomy) only 46% “normal” or “nearly normal” knees.¹⁷ Especially concerning about their report was that 75% of knees that were rated “nearly normal” at an 11.5-year follow-up had degraded to abnormal or severely abnormal at the final follow-up.¹⁷

The results of the patient-reported Lysholm knee scoring scale were good and comparable to the report of Möller et al. at an

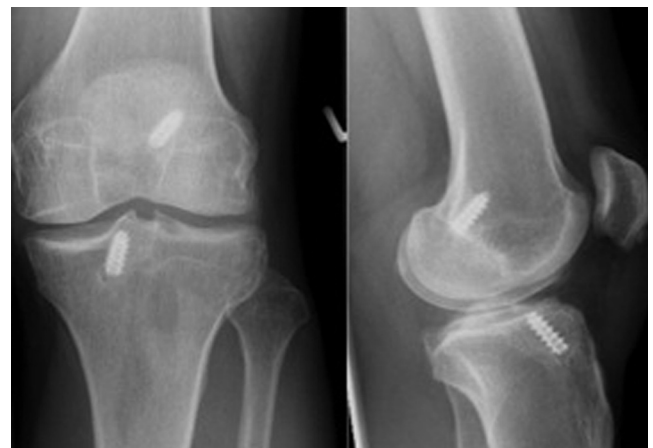


Fig. 2. X-ray (AP and lateral standing) 17 years after ACL reconstruction of a 36-year old male patient. No severe osteoarthritic changes were observed.

Download English Version:

<https://daneshyari.com/en/article/5654191>

Download Persian Version:

<https://daneshyari.com/article/5654191>

[Daneshyari.com](https://daneshyari.com)