Best Practice & Research Clinical Gastroenterology 31 (2017) 27–38

Contents lists available at ScienceDirect

Best Practice & Research Clinical Gastroenterology

journal homepage: https://ees.elsevier.com/ybega/default.asp

3

Acute mesenteric ischemia (Part II) – Vascular and endovascular surgical approaches

Jussi M. Kärkkäinen, MD, PhD Specialist in Vascular and Gastrointestinal Surgery [a, *], Stefan Acosta, MD, PhD Professor of Vascular Surgery [b]

[a] Heart Center, Kuopio University Hospital, P.O. Box 100, 70029 Kuopio, Finland
[b] Department of Clinical Sciences Malmö, Lund University, Sweden

Keywords:
Acute mesenteric ischemia
Acute on chronic mesenteric ischemia
Nonocclusive mesenteric ischemia
Mesenteric venous thrombosis
Endovascular procedures
Endovascular therapy
Angioplasty
Embolectomy
Mechanical thrombolysis
Surgical treatment

A B S T R A C T

The modern treatment of acute mesenteric ischemia (AMI) requires seamless collaboration of gastrointestinal surgeons, vascular surgeons, and interventional radiologists. The treatment strategy is straightforward aiming at rapid restoration of blood flow to the intestine. Bowel resection is performed on demand. The first thing to consider is the patient's clinical condition at presentation, whether there are signs of peritonitis or not, and whether the patient is hemodynamically stable or not. Second, there are four etiologies of AMI that need to be distinguished as they differ in treatment: superior mesenteric artery embolism, mesenteric arterial occlusive disease, mesenteric venous thrombosis, and non-occlusive mesenteric ischemia. In this review, we describe the basic vascular and endovascular treatment modalities accompanied by a simple algorithm for the various situations in AMI. Furthermore, the indications for damage control and primary definitive surgery are discussed.

Introduction

There are four different etiological categories of acute mesenteric ischemia (AMI) that are important to distinguish as they differ in treatment and prognosis. These are 1) superior mesenteric artery (SMA) embolism, 2) mesenteric arterial occlusive disease (i.e., obliterating atherosclerosis with or without thrombosis), 3) mesenteric venous thrombosis (MVT), and 4) non-occlusive mesenteric ischemia (NOMI). In arterial occlusive AMI (the first two categories), the current diagnostic and therapeutic strategy aims at restoring mesenteric circulation by endovascular or surgical means, before irreversible intestinal injury develops. When transmural bowel necrosis has already occurred, intestinal revascularization reduces the extent of damage and facilitates healing of bowel anastomoses. In MVT and NOMI, the initial treatment is usually conservative unless advanced bowel ischemia has already manifested. Endovascular techniques have gained ground in the management of arterial occlusive AMI and MVT. In contrast, there has not been any major breakthrough in the treatment of NOMI recently, if not taken into account advancements in intensive care medicine. In all four etiological categories of AMI, intestinal surgery is needed when bowel necrosis develops. Damage control principals are being widely adapted in the treatment of abdominal emergencies, including patients with peritonitis secondary to AMI [1–3].

Therapeutic strategy in occlusive AMI

The treatment algorithm of arterial occlusive AMI is illustrated in Fig. 1. In stable patients, contrast-enhanced computed tomography (CT) should always be obtained before treatment. In patients without peritonitis, endovascular therapy (EVT) can be attempted before laparotomy as the primary revascularization method [4]. Laparotomy (or laparoscopy) should be performed on demand with low threshold if the symptoms do not resolve quickly after successful EVT. If the endovascular approach fails or cannot be utilized, for example, due to logistical reasons or because of a heavily calcified SMA occlusion, surgical revascularization (open SMA stenting or bypass) is the alternative.

In patients with advanced peritoneal signs (severe pain, abdominal distension), lactatemia, metabolic acidosis, and/or CT findings of advanced bowel ischemia, the primary therapeutic approach is laparotomy. In stable patients with transmural bowel necrosis, intestinal revascularization should be performed prior to

* Corresponding author.
E-mail addresses: jkarkkai@gmail.com (J.M. Kärkkäinen), stefan.acosta@med.lu.se (S. Acosta).

http://dx.doi.org/10.1016/j.bpg.2016.11.003
1521-6918/

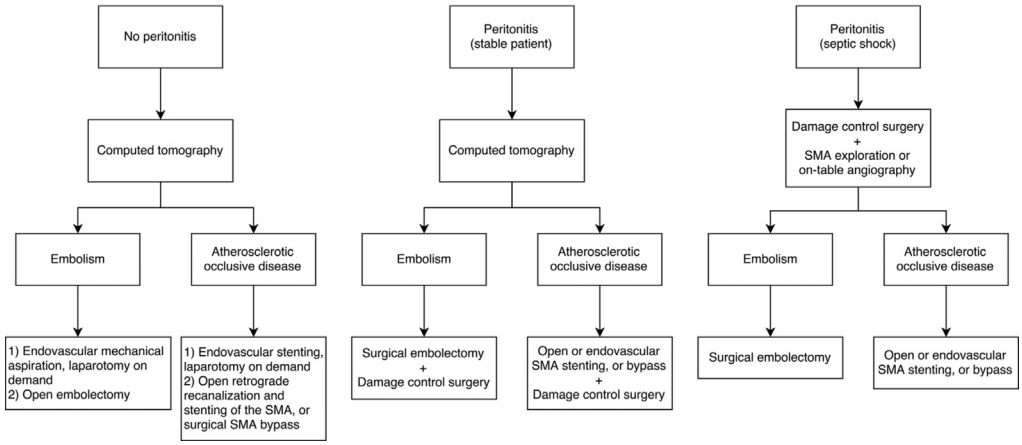

Fig. 1. The treatment algorithm of arterial occlusive AMI. Septic shock is defined as severe hypotension requiring vasoactive treatment.

resection, because the extent of irreversible bowel injury is often impossible to assess before the blood flow has been restored [2]. After 15–20 min of reperfusion, the unsalvageable part of the intestine is resected [5,6].

If the patient is in septic shock (severe hypotension requiring vasoactive medication), laparotomy may have to be performed without CT examination. In this case, the surgeon is usually unaware of the diagnosis. Thus, AMI is sometimes found more or less unexpectedly in laparotomy. In this situation, the surgeon has to make a call to the vascular surgeon and together decide, whether the patient has realistic changes of survival. If not, the abdomen is closed, vasoactive therapy is discontinued, and the patient is treated with maximum comfort care. In the other case, it may be a good idea to quickly staple off frankly ischemic, grey and smelly, or leaky bowel before any vascular surgery is performed. However, at this stage, bowel resection has to be done sparingly. There are two options for the vascular examination. The first is to perform angiography on table. The second is to surgically explore the SMA and assess the vessel by hand and ultrasonic flow meter; intra-operative duplex ultrasonography can also be helpful. In case of SMA embolism, open embolectomy is usually the quickest way to achieve bowel reperfusion during laparotomy. In case of atherosclerotic occlusion (calcified and pulseless SMA), stenting is a viable option; this can be done by endovascular approach or via open retrograde recanalization. If stenting cannot be utilized, a robust surgical bypass should be performed [2,7]. If the SMA is patent, however, you might be dealing with NOMI or distal SMA branch embolism. In that case, bowel resection is usually the choice of treatment.

In a rare situation, a patient with acute MVT might be taken to laparotomy without prior diagnosis by CT examination. The intestine appears to be swollen, oedematous, and ischemic. The SMA pulse is palpable. In this case, MVT can be diagnosed on-table with duplex ultrasonography of the mesentery. In addition, thrombosed veins can be seen while ligating and dividing the mesenteric vessels during bowel resection.

Embolism

Open embolectomy

The surgical exploration of the SMA is performed via upper midline incision (Fig. 2A). The SMA is exposed below the transverse mesocolon by making a horizontal incision in the mesenteric peritoneum. Sometimes, the anterior dissection of the SMA is relatively easy, but often there are fibrous bands, fat, lymphatic tissue, and branches of the superior mesenteric vein (SMV) in the way before the SMA can be reached. Therefore, the dissection has to be carried out carefully. The SMA falls into several branches below the mesocolon and many of these branches have to be taken under control with vessel loops or micro clamps (Fig. 2B). A transverse arteriotomy is made accross the SMA distal to the middle colic artery, and embolectomy is performed using No. 2 or 3 Fogarty balloon catheter. The balloon embolectomy has to be carried out very gently, because the SMA is fragile and dissection occurs very easily if too much force is applied or if the balloon is overdilated. The arteriotomy is closed with interrupted sutures. The result of should be checked at least with transit-time flow measurement, however, the presence of proximal SMA stenosis, distal embolization, or dissection can only be identified with intra-operative completion angiography [1,8].

Endovascular aspiration thrombectomy

The use of endovascular mechanical thrombectomy in AMI has become more common owing to the development of dedicated aspiration catheters [4,9,10]. Primarily, these catheters were designed for intra-cranial use, but now, there are aspiration catheters in the market that are intended for use in the visceral arteries as well. Mechanical aspiration of blood clot from the SMA can be performed via brachial or femoral access. The angle to the SMA is more favorable in the brachial approach, however, the brachial artery is more prone to access-related complications. Typically, 6 or 7 French long sheath is advanced over a guidewire to the visceral segment of the abdominal aorta. The SMA embolus is passed with a hydrophilic guidewire and 5 or 6 French catheter is used to suck the blood clot out with vacuum aspiration using a 20 or 50 ml syringe manually, or by employing an electric vacuum aspiration device such as the Pneumbra® System [4,11].

The risk associated with EVT in AMI is distal embolization of the thrombus material to the peripheral small arterial branches of the mesentery. In a study of 18 patients with SMA embolism, distal emboli or residual thrombus was detected in six patients after EVT; four of those patients received adjunctive thrombolysis [4]. However, according to the study, peripheral residual occlusion rarely deteriorated perfusion of the intestine owing to the mesenteric collateral network. The clinical outcome is usually more dependent on other factors such as the extent of the bowel injury and the patient's condition in general.