Neurochirurgie 63 (2017) 142–149

Disponible en ligne sur
ScienceDirect
www.sciencedirect.com

Elsevier Masson France
EM|consulte
www.em-consulte.com

Original article

Preoperative and intraoperative neurophysiological investigations for surgical resections in functional areas

G. Huberfeld[a,b,c,d], A. Trébuchon[e,f,g], L. Capelle[h], J.-M. Badier[e,f], S. Chen[e,f], J.-P. Lefaucheur[i,j], M. Gavaret[e,f,g,*]

[a] Sorbonne University, UPMC University Paris 06, 75005 Paris, France
[b] Neurophysiology Department, UPMC, centre hospitalo-universitaire Pitié-Salpêtrière, AP–HP, 75013 Paris, France
[c] Inserm U1129, "Infantile Epilepsies and Brain Plasticity", 75015 Paris, France
[d] Paris Descartes University, PRES Sorbonne Paris Cité; CEA, Gif-sur-Yvette, France
[e] Inserm UMR 1106, institut de neurosciences des systèmes, 13005 Marseille, France
[f] Faculté de médecine, Aix-Marseille université, 13005 Marseille, France
[g] Service de neurophysiologie clinique, hôpital de la Timone, AP–HM, 13005 Marseille, France
[h] Neurosurgery Department, centre hospitalo-universitaire Pitié-Salpêtrière, AP–HP, 75013 Paris, France
[i] Service de physiologie, explorations fonctionnelles, hôpital Henri-Mondor, AP–HP, Créteil, France
[j] EA 4391, Nerve Excitability and Therapeutic Team, Faculty of Medicine, Paris-Est Creteil University, Créteil, France

ARTICLE INFO

Article history:
Received 30 April 2016
Received in revised form 17 October 2016
Accepted 31 October 2016
Available online 12 May 2017

Keywords:
Awake surgery
Functional mapping
Glioma
Language
Motricity
Neurophysiology
Somatosensory
Vision

ABSTRACT

Brain regions are removed to treat lesions, but great care must be taken not to disturb or remove functional areas in the lesion and in surrounding tissue where healthy and diseased cells may be intermingled, especially for infiltrating tumors. Cortical functional areas and fiber tracts can be localized preoperatively by probabilistic anatomical tools, but mapping of functional integrity by neurophysiology is essential. Identification of the primary motor cortex seems to be more effectively performed with transcranial magnetic stimulation (TMS) than functional magnetic resonance imaging (fMRI). Language area localization requires auditory evoked potentials or TMS, as well as fMRI and diffusion tensor imaging for fiber tracts. Somatosensory cortex is most effectively mapped by somatosensory evoked potentials. Crucial eloquent areas, such as the central sulcus, primary somatomotor areas, corticospinal tract must be defined and for some areas that must be removed, potential compensations may be identified. Oncological/functional ratio must be optimized, resecting the tumor maximally but also sparingly, as far as possible, the areas that mediate indispensable functions. In some cases, a transient postoperative deficit may be inevitable. In this article, we review intraoperative exploration of motricity, language, somatosensory, visual and vestibular function, calculation, memory and components of consciousness.
© 2017 Elsevier Masson SAS. All rights reserved.

1. Introduction

When removing tissue to treat brain lesions, such as tumors, from which diseased cells infiltrate into the normal parenchyma, neurosurgeons aim to retain brain function to the maximal extent possible. However, there is a conflict, which was evident at the start of the last century [1] and still crucial today. Brain lesions may induce clinical symptoms or affect bodily function or may pass unperceived by patients. Neurons and networks around or inside a tumor may still contribute usefully to a function and so must be precisely mapped before and also during surgical resections. Testing function during surgery requires access to the area to be stimulated, and evaluation of the stimulation, which often necessitates active participation of an awake patient. Tests of the functionality or involvement of an area should be reversible and reproducible [2]. Electrical brain stimulation during surgery may interfere directly and transiently with restricted cortical areas of axons [3] and also provoke glutamate, gamma-amino-butyric acid (GABA) release to initiate a surround inhibition and therefore enhance spatial resolution [4].

Abbreviations: AEP, auditory evoked potentials; DCS, direct cortical stimulation; ECoG, electrocorticography; EEG, electroencephalography; fMRI, functional MRI; MEG, magnetoencephalography; MEP, motor evoked potentials; nTMS, navigated TMS; nrTMS, navigated repetitive TMS; RC, release component; rTMS, repetitive TMS; SSEP, somatosensory evoked potentials; TMS, Transcranial Magnetic Stimulation; VOT, voice onset time.

* Corresponding author. Service de neurophysiologie clinique, pôle neuro-Sainte-Anne, centre hospitalier Sainte-Anne, 1, rue Cabanis, 75014 Paris, France.
E-mail address: martine.gavaret@parisdescartes.fr (M. Gavaret).

http://dx.doi.org/10.1016/j.neuchi.2016.10.008
0028-3770/© 2017 Elsevier Masson SAS. All rights reserved.

Historical anatomo-clinical methods provided initial data on how brain areas are related to functions. The concept of an eloquent area that produces functions or signs when stimulated [5] emerged from electrical brain mapping. Subsequently functional imaging showed that multiple areas connected in functional macroscopic networks were typically involved in a variety of tasks. Recent electrical brain mapping studies have seen a shift from "a localizationist view of brain processing" where cerebral functions are attributed to modular, segregated regions, to a hodotopical framework, in which brain functions emerge from large integrated, parallel and dynamic cortico-subcortical networks [6]. In this context stimulating subcortical fibers permits identification of brain functional connectivity [7].

Localizing eloquent cortical areas or fiber bundles is mandatory to preserve the function and optimize the extent of resection of brain lesions. Presurgical tools may permit tests on the level of function and on the integrity of functional pathways or cortical areas. However, tumoral and normal tissues are frequently intermingled, and resections should normally extend beyond the anatomical limits of the tumor, since tumoral cells typically extend beyond the MRI-defined abnormalities. Intraoperative testing of local functions and connections is therefore crucial [8]. Furthermore, a growing tumor induces plastic reorganizations of cortical functions. This type of anatomo-functional rearrangement must be identified by intraoperative functional mapping even if recognized preoperatively [9,10]. Current mapping techniques permit a tailored functional localization based on the location of cortical areas and subcortical connections [11–13].

Here, we review techniques and indications of preoperative and intraoperative neurophysiological investigations for surgical resections in functional brain areas. The review focuses on motricity, language, somatosensory functions, vision, vestibular and other integrated functions.

2. Motricity

2.1. Preoperative motor mapping

Intraoperative direct cortical stimulation (DCS) permits the surgical removal of a brain tumor to be completed in the rolandic region, while minimizing the risk of postoperative motor deficits. Preoperative functional data may be useful for surgical planning, but the accuracy of functional magnetic resonance imaging (fMRI), in assessments of motor cortical function, has recently been questioned [14]. Transcranial magnetic stimulation (TMS), a non-invasive procedure, yields motor cortex maps of high anatomical precision when integrated with individual MRI data with a dedicated navigation system [15]. Navigated TMS (nTMS) mapping consists of measuring the amplitude of motor evoked potentials (MEP) across motor cortical regions for each stimulation site and locating responses on a 3D-reconstruction of patient's head by a frameless stereotaxic system. A color code is used to visualize the cortical targets with respect to the corresponding MEP amplitude. This information merged with MRI scans (Fig. 1) can be transferred to neuronavigation systems in the operating room.

Preoperative nTMS data correlate well with intraoperative DCS data, with difference of only 4–8 mm in locations of motor hotspot defined by the two techniques [14,16]. Multiple studies now show the functional and anatomical identification of eloquent motor cortical regions obtained with nTMS is superior to the precision obtained with fMRI or magnetoencephalography (MEG) [17,18]. Navigated TMS affects treatment with several studies suggesting that surgical strategies are modified for 25–70% of operations [14,19,20]. The nTMS technique was also found to have a good reproducibility in recurrent brain tumor surgeries [21].

In conclusion, preoperative nTMS mapping is a valid and useful tool to optimize surgical planning and reduce the risk of postoperative motor deficits due to damage of the eloquent motor cortex. This rapid and simple technique should be more systematically performed used for brain tumor surgery.

2.2. Intraoperative evaluation of motricity

Preserving motor function is a major challenge in surgery for intra-axial brain tumors [22]. Functional neuronavigation may become unreliable due to brain movements during surgery resulting from tumor resection, cerebrospinal fluid loss, surgical retraction or gravity. Navigation based on preoperative anatomical and functional imaging becomes unreliable for tumor resection close to motor cortex or pyramidal tract [23]. Direct cortical and subcortical stimulation remains the gold standard to identify and preserve the corticospinal tract. Direct cortical and subcortical MEP can be recorded intraoperatively to assess function and estimate the distance from the corticospinal tract [22]. MEP are recorded by pairs of needle electrodes inserted into the contralateral target muscles for the face and the distal upper and lower limbs.

Subcortical motor mapping has an important effect on resection grade and motor outcome during eloquent tumor surgery [22,24–29]. Even while eloquent cortex is preserved, interrupted connections with subcortical regions may lead to postsurgical

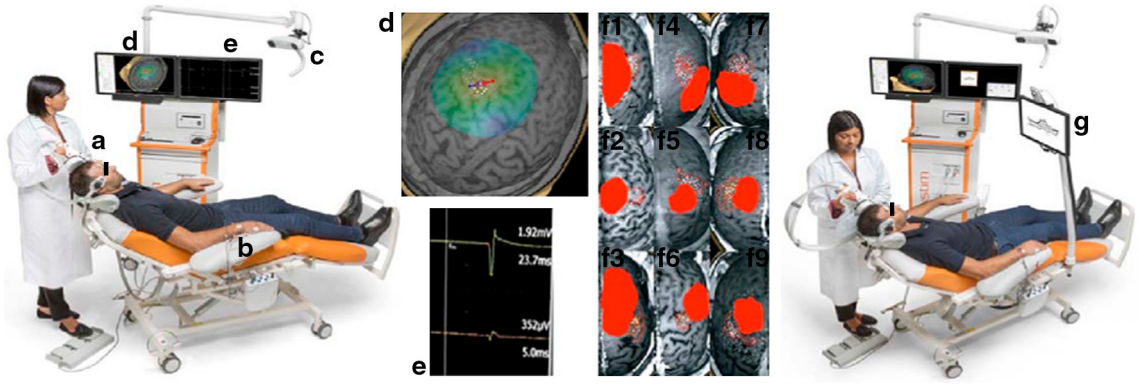

Fig. 1. The navigated transcranial magnetic stimulation (nTMS) system. a: TMS coil; b: surface electrode for recording MEPs; c: infrared tracking camera; d: screen for online visualizing coil orientation (blue-red double-arrow) and motor cortical map (one marker for each stimulation, colored in pink or red for the sites of stimulation producing MEPs; e: screen for online visualizing MEPs; f: motor maps in 9 patients with rolandic tumour (coloured in red) on the right (f1-F6) or left (f7-f9) hemisphere, showing a shift of the cortical area producing MEPs (pink or red markers, circled by a thin red line) on the anterolateral (f1,f5), lateral (f2,f8), posterolateral (f3,f9), anteromedial (f4,f7), or posteromedial (f6) direction (derived from [Picht et al., 2012]); g: screen where the pictures to name are presented during repetitive TMS trains for language and speech production test.

Download English Version:

https://daneshyari.com/en/article/5681671

Download Persian Version:

https://daneshyari.com/article/5681671

Daneshyari.com