The Knee xxx (2017) xxx–xxx

Contents lists available at ScienceDirect

The Knee

Detection of bone defects around zirconium component after total knee arthroplasty

Yukihide Minoda [a,*], Kazumasa Yamamura [a], Kazutaka Sugimoto [b], Shigekazu Mizokawa [a], Shingo Baba [c], Hiroaki Nakamura [a]

[a] Department of Orthopaedic Surgery, Osaka City University Graduate School of Medicine, Osaka, Japan
[b] Sonodakai Joint Replacement Center, Tokyo, Japan
[c] Shimadzu Corporation, Kyoto, Japan

ARTICLE INFO

Article history:
Received 9 November 2016
Received in revised form 25 March 2017
Accepted 27 April 2017
Available online xxxx

Keywords:
Computed tomography (CT)
Magnetic resonance imaging (MRI)
Plain radiography
Tomography
Total knee arthroplasty
Zirconium

ABSTRACT

Background: It is difficult to detect bone defects caused by loosening or osteolysis around the femoral component after total knee arthroplasty (TKA) because the thick metal hinders visualization of bone defects. Previous reports have shown that tomosynthesis, a novel tomographic technique, is advantageous over fluoroscopically guided plain radiography, computed tomography (CT) and magnetic resonance imaging (MRI) for the early detection of bone defects around a conventional cobalt–chromium alloy component. However, there have been no reports on a zirconium component. The purpose of this study was to examine the sensitivity and specificity of the detection of bone defects around a zirconium component using fluoroscopically guided plain radiography, tomosynthesis, CT and MRI.
Methods: Six zirconium femoral components were implanted in pig knees. Two were cemented without any bone defects. Two were cemented with cystic defects. Two were cemented with four-millimeter-thick defects between the bone cement and the bone. Defects were filled with agarose gel. Eight orthopedic surgeons examined the fluoroscopically guided plain radiography, tomosynthesis, CT and MRI images. Sensitivity and specificity of each method were analyzed.
Results: No bone defects were detected with plain radiography. The sensitivity and specificity of tomosynthesis were 21.9% and 36.8%, respectively. The sensitivity and specificity of CT were 15.1% and 33.0%, respectively. The sensitivity and specificity of MRI were 84.4% and 86.6%, respectively.
Conclusions: For the detection of bone defects around a zirconium component after TKA, MRI is advantageous over fluoroscopically guided plain radiography, tomography and CT, in terms of sensitivity and specificity.

© 2017 Elsevier B.V. All rights reserved.

1. Introduction

Recent national registry data show that the number of total knee arthroplasty (TKA) procedures has increased, and will continue to increase [1–6]. The number of revision TKA surgeries is also increasing [4,5]. Loosening and osteolysis are still the most

* Corresponding author at: Department of Orthopaedic Surgery, Osaka City University Graduate School of Medicine, 1-4-3 Asahimachi Abeno-ku, Osaka 545-8585, Japan.
E-mail address: yminoda@msic.med.osaka-cu.ac.jp (Y. Minoda).

http://dx.doi.org/10.1016/j.knee.2017.04.020
0968-0160/© 2017 Elsevier B.V. All rights reserved.

ARTICLE IN PRESS

frequent causes for revision TKA [7]. However, it is difficult to detect bone defects caused by loosening or osteolysis around the femoral component because the thick metal of the femoral component hinders visualization of bone defects [8]. For detection of bone defects caused by osteolysis and loosening around the conventional cobalt–chromium (Co–Cr) alloy component, the novel tomographic technique (tomosynthesis) is advantageous over fluoroscopically guided plain radiography, computed tomography (CT) and magnetic resonance imaging (MRI) [9].

To reduce the polyethylene wear particle generation, oxidized zirconium was introduced as a bearing surface material for the femoral component (Oxinium, Smith & Nephew, Inc., Memphis, TN, USA). This implant was produced from a wrought zirconium alloy (Zr–2.5%Nb) that is oxidized by thermal diffusion to create a zirconium ceramic surface about five-micrometer thick [10]. Visualization of bone defects around the component may differ between zirconium and Co–Cr alloy. Previous reports have compared visualization of bone defects around the zirconium femoral component and Co–Cr alloy femoral component using MRI [11]. However, there have been no reports comparing visualization of bone defects around a zirconium femoral component between MRI and other examinations such as fluoroscopically guided plain radiography, tomosynthesis and CT.

The purpose of this study was to examine, in a pig model, the sensitivity and specificity of the detection of the bone defects around a zirconium component caused by osteolysis and loosening using fluoroscopically guided plain radiography, tomosynthesis, CT and MRI.

2. Methods

Six zirconium femoral components (Legion PS; Smith & Nephew, Inc., Memphis, TN, USA) were implanted in pig knees (Figures 1 and 2). This component had a metal box between the medial and lateral condyles. Three types of models were prepared: nondefect, osteolysis and radiolucent line.

2.1. Nondefect model

In two knees, femoral components were implanted using bone cement (Simplex P, Stryker, Kalamazoo, MI, USA) without any bone defects.

2.2. Osteolysis model

To simulate osteolysis-induced bone defects, cystic defects were created on the distal femoral condyles of two knees after the preparation of bone for implantation. The bone defects were placed on the distal surface of the femoral condyles. One defect was created in each femoral condyle. The bone defects were filled with one percent agarose to simulate granuloma tissue, in order to reduce the air artifacts around the bone lesions that can interfere with imaging procedures [9,10]. Then, two components were implanted with bone cement (Figure 1). The size of bone defects was estimated by the amount of the agarose gel that filled the bone defects. The mean size of bone defects was 3.0 ± 0.5 (mean $\pm$ standard deviation) cm^3.

2.3. Radiolucent line model

To simulate early stage loosening of the femoral component, two femoral components with four-millimeter-thick defects between the bone cement and the bone were implanted (Figure 2). The bone defects were filled with one percent agarose to simulate granuloma tissue [9,10].

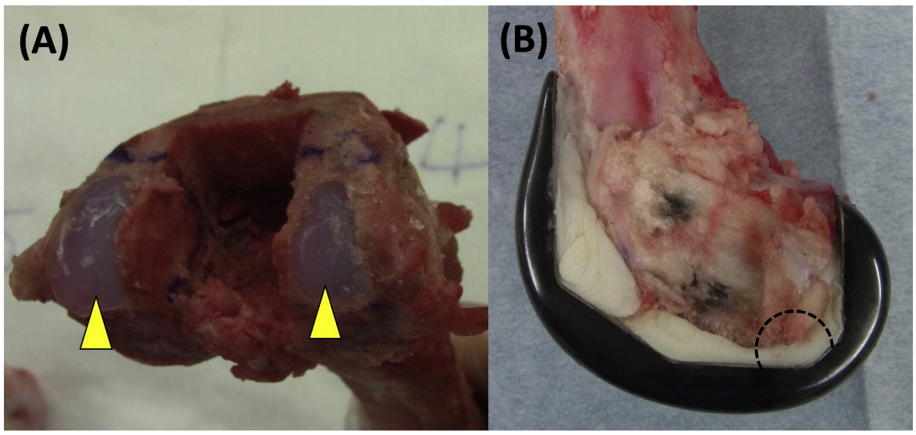

Figure 1. (A) Osteolysis model. The bone defects were filled with agarose gel to simulate granuloma tissue to prevent air artifacts (yellow arrows) [9,10]. (B) The femoral component was fixed with bone cement. The bone defect could not be seen after cementing the femoral component (dotted line). (For interpretation of the references to color in this figure legend, the reader is referred to the web version of this article.)

Please cite this article as: Minoda Y, et al, Detection of bone defects around zirconium component after total knee arthroplasty, Knee (2017), http://dx.doi.org/10.1016/j.knee.2017.04.020

Download English Version:

https://daneshyari.com/en/article/5710744

Download Persian Version:

https://daneshyari.com/article/5710744

Daneshyari.com