CASE REPORT – OPEN ACCESS

International Journal of Surgery Case Reports 39 (2017) 115–118

Contents lists available at ScienceDirect

International Journal of Surgery Case Reports

journal homepage: www.casereports.com

A staged, endovascular approach to treat a ruptured external iliac artery mycotic pseudoaneurysm in an intravenous drug user: A case report

Mehtab Ahmad*, Yi Wen Poh, Christopher H.E. Imray

University Hospitals Coventry and Warwickshire, Clifford Bridge Road, Walsgrave, Coventry, CV2 2DX, United Kingdom

ARTICLE INFO

Article history:
Received 22 March 2017
Received in revised form 29 July 2017
Accepted 29 July 2017
Available online 5 August 2017

Keywords:
Case report
Treatment
Mycotic pseudoaneurysm
IVDU

ABSTRACT

INTRODUCTION: Ruptured mycotic pseudoaneurysms are one of the ways IVDU patients can present in extremis. The principles of treatment include arterial ligation for haemorrhage control but can leave patients vulnerable subsequent limb ischaemia.
PRESENTATION OF CASE: We report a female IVDU presenting with abdominal pain and sepsis. Imaging demonstrated haemorrhage from an external iliac pseudoaneurysm. A two-staged hybrid approach with initial endografting and debridement for sepsis-control followed by delayed endograft removal and arterial reconstruction was successfully undertaken.
DISCUSSION: The primary use of endovascular techniques to control haemorrhage in unstable patients is a useful adjunct to treat ruptured mycotic pseudoaneurysms in IVDU patients with delayed removal and arterial reconstruction.
CONCLUSION: We have shown a successful outcome in managing a challenging patient using endovascular techniques as a bridge to definitive arterial reconstruction. This circumvents traditional approaches including primary arterial ligation, which carry a risk of limb-loss.

1. Introduction

Mycotic pseudoaneurysm formation and subsequent rupture in intravenous drug users (IVDU) can be potentially devastating to patients, or result in death [1,2]. Various treatment strategies for haemorrhage control have been reported with most advocating arterial ligation [3,4]. Other strategies include arterial ligation with immediate arterial reconstruction or as we report, endovascular stent-graft insertion. This report is compliant with the SCARE criteria and PROCESS guidelines published on case report submissions [5,6]. Our case adds to the literature by being, we believe, one of two published reports in the literature describing the use of emergency stent-grafting and subsequent (delayed) arterial reconstruction after sepsis–control, and the only one describing its utility in the IVDU setting [7].

2. Case report

A 37-year old Caucasian female IVDU presented to our emergency department with a one-week history of fever with worsening left flank, groin and abdominal pain. She was normotensive, but tachycardic and tachypnoeic at presentation. Examination revealed scarred groins, discharging purulent fluid. Other physical findings were unremarkable. Her medical history included Hepatitis C and she admitted to a heroin addiction. She had no known allergies.

2.1. Investigations

Laboratory investigations showed a marked leucocytosis (38.0×10^9/L), elevated C-reactive protein (CRP) (350 mg/L) and normocytic anaemia (10.0 g/dL). A computed tomographic (CT) angiogram of her abdomen and pelvis demonstrated a medially displaced left kidney with a 10 cm retroperitoneal, loculated collection communicating with the left external iliac artery (EIA) whose appearances suggested pseudoaneurysm formation with recent haemorrhage (Figs. 1 and 2).

Abbreviations: IVDU, intravenous drug use; DVT, deep venous thrombosis; CRP, C-reactive protein; CT, computed tomographic; EIA, external iliac artery; cm, centimetre; ITU, intensive treatment unit; DSA, digital subtraction angiogram.

* Corresponding author.
E-mail address: tabbyahmad@doctors.org.uk (M. Ahmad).

http://dx.doi.org/10.1016/j.ijscr.2017.07.054

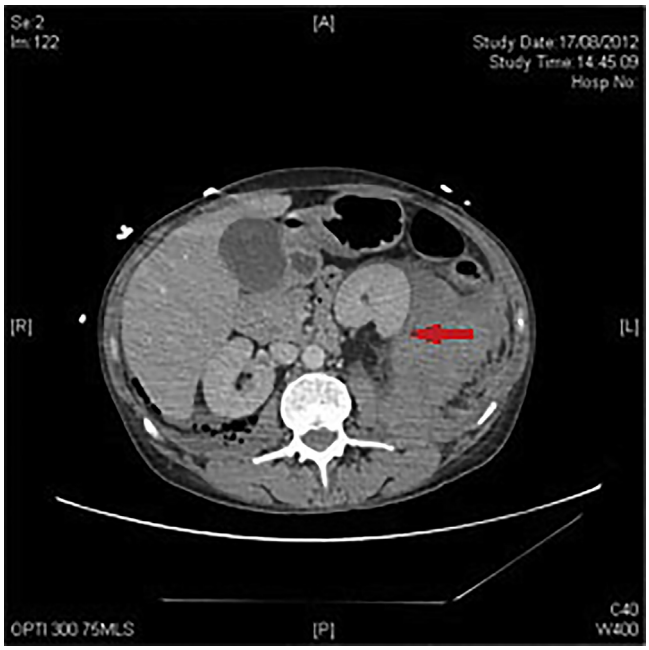

Fig. 1. Retroperitoneal haematoma and a medially displaced left kidney.

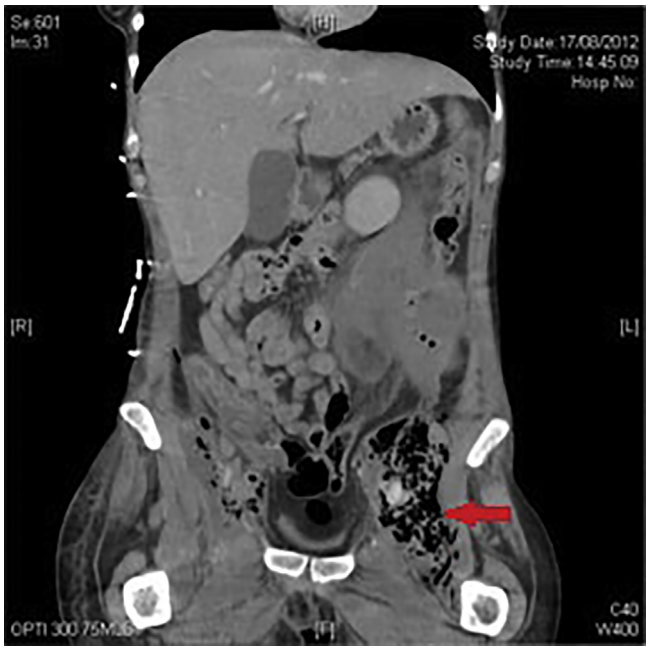

Fig. 2. Extensive gas locules in the left iliopsoas region.

Fig. 3. Intra-operative digital subtraction angiogram (DSA) demonstrating extravasation of contrast from the ruptured external iliac artery mycotic pseudoaneurysm.

Fig. 4. Intra-operative digital subtraction angiogram (DSA) showing control of haemorrhage using a covered stent-graft.

2.2. Treatment

A decision was made to control haemorrhage using endovascular techniques and subsequently plan for delayed arterial reconstruction. She was stabilised and transferred to theatre, where surgical cut-down to the left popliteal artery was undertaken to provide access for Bard Fluency® Plus (covered) Vascular Stent Graft (7 mm × 6 cm) insertion via retrograde puncture (Figs. 3 and 4). Prior to arterial closure, a distal popliteal embolectomy was also performed. Diagnostic laparoscopy excluded occult intra-peritoneal contamination and bilateral Rutherford-Morrison incisions were then made to drain the retroperitoneum. Extensive infected clot was removed from both retroperitoneal spaces, lavage performed and drains placed. Wounds were packed with betadine-soaked gauze in anticipation of further wound toilet and debridement. She was transferred to the intensive treatment unit (ITU) and returned to theatre at 24-h for a re-look. Further infected clot was evacuated and the wound re-packed. This cycle of wound toilet continued for a further 48 h at which point wounds were closed. She remained on ITU for a further ten days and was treated with appropriate antibiotics (intra-operative cultures grew *Staphylococcus* sp. *Diphtheroids* sp., anaerobic gram positive cocci and aerobic gram positive bacilli). She was discharged home on antibiotics after a three-week in-patient stay.

On out-patient follow-up the left-sided incision continued to discharge pus, and CT imaging demonstrated peri-stent-graft