

Contents lists available at [ScienceDirect](http://ScienceDirect.com)

International Journal of Surgery Case Reports

journal homepage: www.casereports.com

The great mimicker at thoracolumbar spine: Non-Hodgkin's lymphoma



Turgut Akgül, Yücel Bilgin, Gökhan Karademir*

Department of Orthopedics and Traumatology, Istanbul Faculty of Medicine, Istanbul University, Capa Fatih, Istanbul, 34050, Turkey

ARTICLE INFO

Article history:

Received 2 February 2017

Received in revised form 18 August 2017

Accepted 18 August 2017

Available online 24 August 2017

Keywords:

Thoracolumbar
Spine
Mimicker
Non-Hodgkin's
Lymphoma

ABSTRACT

PURPOSE: To report two cases with Non-Hodgkin's Lymphoma (NHL) in thoracolumbar spine with very different presentation.

METHODS: Case 1; An 84-year-old female patient was admitted to our emergency clinic with paraparesis in both lower extremities. Magnetic resonance imaging (MRI) revealed an epidural mass at the level of the T12 vertebrae. She was operated immediately with wide laminectomy and posterior instrumentation because of the paraparesis of both lower extremities. Case 2; An 70-year-old female patient was admitted to our clinic with thoracolumbar back pain. There was a T12 vertebra compression fracture view in the X-ray imaging. MRI revealed multiple infiltrations in medullar canale at thoracolumbar spine with lytic lesion. She underwent eight cycles of chemotherapy.

RESULTS: Multiple bone involvement was detected in both cases in PET-CT (Positron emission tomography-computed tomography) scans. Additionally it was found that there were nodal involvements accompanying these involvements in case 1. Because radiological examinations were not specific enough to diagnose, it was necessary to perform a biopsy. The histopathological diagnosis of these patients revealed diffuse large B cell non-Hodgkin's lymphoma.

CONCLUSIONS: Diagnosis of the non-Hodgkin's lymphomas that are localized in thoracolumbar spine is often missed or delayed due to lack of specific findings and presence similarities to other diseases. Diagnosis is made by histopathologic examination. Although the main treatment is chemotherapy for these patients, surgery is necessary for patients with neurological deficits.

© 2017 Published by Elsevier Ltd on behalf of IJS Publishing Group Ltd. This is an open access article under the CC BY-NC-ND license (<http://creativecommons.org/licenses/by-nc-nd/4.0/>).

1. Introduction

Non-Hodgkin lymphomas (NHL) are malignant neoplasms of lymphoid cells, the predominant cells of the immune system [1]. Primary bone involvement within these involvements has been reported in 5% of extranodal involvement and has been reported in 7% of all bone tumors [2]. In the histopathologic diagnosis, it is often encountered with diffuse large B-cell lymphoma [3]. As well as bone involvements can be single or multiple. Bone involvements often have been reported as ilium, scapula, vertebrae, femur and tibia [4]. Patients can be admitted to the hospital with complaints of pain, soft tissue swelling, pathological fractures and neurological symptoms [5–7]. In the literature, lymphomas that are localized in the thoracolumbar region have been reported with difficulties in the differential diagnosis within nonspecific infection, tuberculosis, lumbar disc herniation [7–9]. Although lytic, blastic or mixed lesions are detected on the radiological examination, there are no specific findings [10]. In our study, patients with NHL who had

extranodal involvement localized in thoracolumbar region and who admitted to the hospital with complaints of different clinical and radiological findings were presented.

1.1. Case 1

An 84-year-old female patient was admitted to our emergency clinic with continued back pain for 3 months. The patient had lower extremity muscle weakness complaints during the last two weeks. On the examination of the patient, lower extremity muscle strength was 2/5. A T2-weighted sagittal magnetic resonance imaging (MRI) scan of the thoracolumbar spine showed a high-signal mass including epidural area and left paravertebral area at the level of T12 vertebrae (Fig. 1). Also the medullar canale involvement at the level of T12 vertebrae was determined. Computarized tomography(CT) of the spine showed minimal height loss at the T12 vertebrae body. (Fig. 2) Blood analysis showed the following results (Table 1): White blood cell count(WBC):6500/mL (Normal Value(NV) 4000–10.000/mL), C-reactive protein level(CRP): 85,66 mg/L (NV 0–5 mg/L), Erythrocyte sedimentation rate(ESR):83 mm/h (NV 0–20 mm/h), Hemoglobin(Hb):11,6 g/dL (NV 13–17 g/dL), Hematocrit(Hct):34,9% (NV:36–46%), Serum protein electrophoresis was

* Corresponding author.

E-mail address: dr@gokhankarademir.com (G. Karademir).

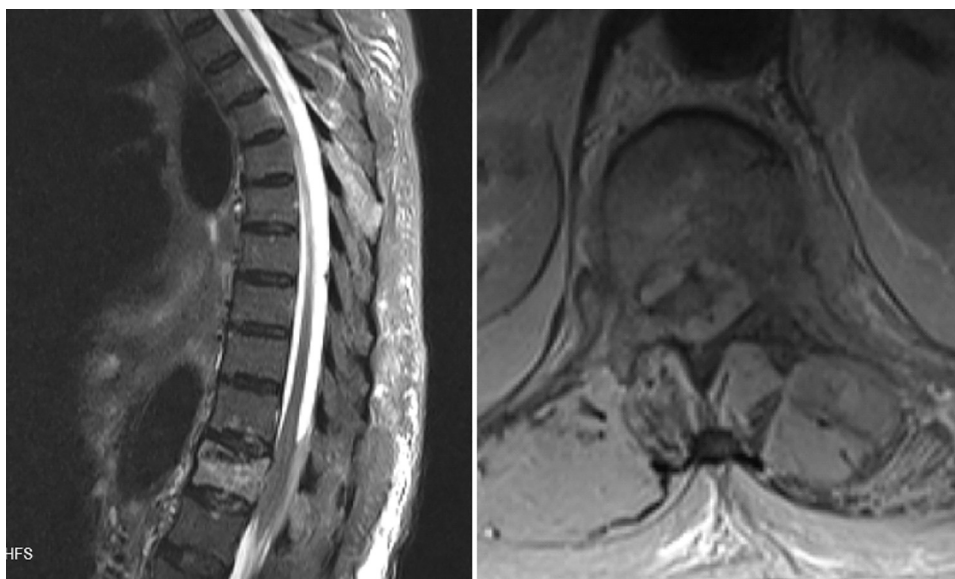


Fig. 1. Magnetic resonance imaging (MRI) scan of the thoracolumbar spine showed a high-signal mass including epidural area and left paravertebral area at the level of T12 vertebrae.

normal, Wright test: negative, Tuberculin test:negative. Positron emission tomography–computed tomography (PET-CT) scanning in patients with celiac and portal hilar area (Maximum standardized uptake value (SUVmax):39.8), iliac chain (SUVmax:25.3), T6-11-12 and L1-2-4 vertebrae (SUVmax:22.3) diffuse involvement, T12, L3 and accompanied by soft tissue component of the pubis (SUV max:39.7). These involvements were pathological. Because of the paraparesis of both lower extremities we performed surgical treatment. Patient underwent surgery in prone position under general anesthesia. Midline skin incision was made between T10-L2 vertebrae levels. Paravertebral muscles separated. Posterior elements were revealed. A paravertebral mass was seen. We made posterior decompression with wide laminectomy (T11-L1). Mass in the medullary canal was cleaned. After that T10–L2 posterior instrumentation with poliaxiel pedicle screws was performed for stabilization (Fig. 3). There was not much bleeding during surgery. Wound area problem did not develop.

Diffuse neoplastic development with large round cell morphology was observed in samples taken in the operation. Antigenic examination CD3 (–), CD5 reactive T lymphocytes (+), CD20 (+), MUM-1 (+) 10–20% of cells, CD10 (–), Bcl-6 (+), Bcl-1 (–), CD138 (–), S-100 (–), Ki-67 80–90% have been found. Increase in muscle strength was recorded after the 3rd postoperative day. The histopathologic diagnosis of the patient was reported as diffuse large B-cell lymphoma. Patient was hospitalized to oncology service for chemotherapy but the patient died of respiratory failure 15 days after operation.

Table 1
Blood analysis of two cases (Wbc:White Blood Cell, CRP:C-Reactive Protein, ESR:Eritrocyte Sedimentation Rate, Hb:Hemoglobin, Hct:Hematocrit, NV:Normal Value).

	Case 1	Case 2
WBC (NV 4000–10.000/mL)	6500/mL	8400/mL
CRP (NV 0–5 mg/L)	85,66 mg/L	27,3 mg/L
ESR (NV 0–20 mm/h)	83 mm/h	26 mm/h
Hb (NV 13–17 g/dL)	11,6 g/dL	11,3 g/dL
Hct (NV:36–46%)	34,9%	34,8%

1.2. Case 2

An 70-year-old female was admitted to our clinic with persistent low back pain for 3 months. She was administered diclofenac and gabapentin treatment with a diagnosis of degenerative lumbar spine disease. However there was no decrease in the patient’s pain. In the MRI, there was compression fracture in the T11 vertebrae. There were lytic lesions with corpus involvement that localized in L1, L4 and L5 vertebrae on MRI T2-weighted images (Fig. 4) Blood analysis showed following results (Table 1): WBC:8400/mL (NV 4000–10.000/mL), CRP level:27.3 mg/L (NV 0–5 mg/L), ESR:26 mm/h (NV 0–20 mm/h), Hb:11.3 g/dL (NV 13–17 g/dL), Hct:34.8% (NV:36–46%). After PET-CT scan, bone marrow biopsy was performed with pre-diagnosis of multiple myeloma. On the PET-CT scan; there were clavicle, sternum, L1, L2, L4, L5 vertebrae corpus and both femoral intertrochanteric region (SUV max:10.7) involvement of lytic manner. Additionally there was T11 compression fracture (SUVmax:7). Serum protein electrophoresis and bone marrow biopsy was evaluated as negative. Biopsy taken from the sacral lesion under CT. Enough tissue couldn’t be obtained whereupon open biopsy was performed in the proximal femoral intramedullary lesion. After histological examination of the taken tissue sample, diffuse large B-cell lymphoma was diagnosed. Immunohistochemical analysis revealed that CD20 (+), bcl-6 (+), bcl-2 (+), Bax-5 (+) lymphoma cells and Ki-67 proliferation was determined as 80%. Patient underwent eight cycles of chemotherapy involving cyclophosphamide, adriamycin, oncovin, prednisone (CHOP) and rituximab without complications. Two cycles of chemotherapy involving Rituximab, cyclophosphamide and prednisolone was added the treatment. After 6 cycles of chemotherapy, PET-CT scan was performed again. The control PET-CT scan showed no pathological finding. Patient’s pain was relieved after 3 cycles of chemotherapy. Zolendronic acid was planned for lytic lesion after chemotherapy.

2. Discussion

NHL cases who had only bone involvement (Non-systemic involvement within the first 6 months from diagnosis) are seen in less than 1% [1–3]. Patients usually admitted to hospital with complaints of radiculopathy, suspected infection, degenerative lumbar

Download English Version:

<https://daneshyari.com/en/article/5732789>

Download Persian Version:

<https://daneshyari.com/article/5732789>

[Daneshyari.com](https://daneshyari.com)