



## Case Report

## The impact of three-dimensional optical coherence tomography and kissing-balloon inflation for stent implantation to bifurcation lesions



Hiroshi Koiwaya (MD, PhD)<sup>a,\*</sup>, Masao Takemoto (MD, PhD)<sup>b</sup>, Kenji Ogata (MD)<sup>a</sup>, Tatsuya Nakama (MD)<sup>a</sup>, Makoto Furugen (MD, PhD)<sup>a</sup>, Nozomi Watanabe (MD, PhD, FJCC)<sup>a</sup>, Nehiro Kuriyama (MD, PhD)<sup>a</sup>, Yoshisato Shibata (MD)<sup>a</sup>

<sup>a</sup> Department of Cardiology, Miyazaki Medical Association Hospital, Miyazaki, Japan

<sup>b</sup> Cardiovascular Center, Munakata Suikokai General Hospital, Fukutsu, Japan

## ARTICLE INFO

## Article history:

Received 16 July 2015

Received in revised form 28 October 2015

Accepted 16 December 2015

## Keywords:

Bifurcated lesion

Kissing-balloon inflation

Optical coherence tomography

Stent deformation

## ABSTRACT

The rates of restenosis and stent thrombosis after the therapeutic stent deployment for bifurcation lesions are still comparably high after the introduction of the new-generation drug-eluting stents (DESs), because of the various factors including their morphology. We experienced a case of a successful percutaneous coronary intervention using three-dimensional optical coherence tomography (3D OCT) with a single stent deployment to a bifurcation lesion of the left anterior descending artery (LAD) and left circumflex artery (LCx) with a following kissing-balloon inflation (KBI). The 3D OCT, after the inflation of the jailed ostium of the LCx following the stent deployment to the LAD crossing the LCx, could clearly demonstrate a stent deformation and incomplete apposition at an opposite site of the LCx, which may cause high rates of restenosis and stent thrombosis. These stent abnormalities were steadily corrected by a subsequent KBI of the LAD and LCx. Furthermore, the 3D OCT images were the same findings as those of the experiments from both an *in vitro* phantom coronary bifurcation model and macroscopic images of the stent.

**<Learning objective:** In view of this case report, these modalities with three-dimensional optical coherence tomography and the techniques for the following kissing-balloon inflation may be one of the useful and effective therapeutic strategies to reduce the rates of restenosis and stent thrombosis of the percutaneous coronary intervention for bifurcation lesions.>

© 2015 Japanese College of Cardiology. Published by Elsevier Ltd. All rights reserved.

## Introduction

Although the new-generation drug-eluting stents (DESs) have gained widespread use due to the low rates of restenosis and stent thrombosis, and lower risk of death [1], the rates of restenosis and stent thrombosis after the therapeutic stent deployment for bifurcation lesions are still comparably high, because of various factors including their morphology defined by the Medina bifurcation classification [2], the target vessel's reference diameter, bifurcation angle, design of the stents, and strategies of the stent implantation. Thus, the strategies used for those lesions are still not well established [3–5] in the new-generation DES era. Here we

report a case that progressed satisfactorily after a bifurcation stenting using three-dimensional optical coherence tomography (3D OCT) (St. Jude Medical, ILUMIEN OPTIS™, St. Paul, MN, USA) and following a kissing-balloon inflation (KBI) for the bifurcation lesions.

## Case report

A 62-year-old male was admitted to our hospital with the chief complaint of increasing episodes of chest pain on exercise. His coronary risk factors included hypertension, dyslipidemia, and a family history of coronary artery disease. A 12-lead electrocardiogram revealed a T-wave inversion in the precordial leads. His plasma troponin I levels were significantly elevated, but the other cardiac enzymes were not. Since the emergent coronary angiography (CAG) revealed that there was one-vessel disease with a long diffuse narrow and severe stenosis of the proximal left anterior descending (LAD) coronary artery (Medina's classification 0, 1, 0

\* Corresponding author at: Department of Cardiology, Miyazaki Medical Association Hospital, 738-1 funato Shinbeppu-machi, Miyazaki 880-0834, Japan. Tel.: +81 985 24 9119; fax: +81 985 23 2210.

E-mail address: [koiwaya.hiroshi@gmail.com](mailto:koiwaya.hiroshi@gmail.com) (H. Koiwaya).

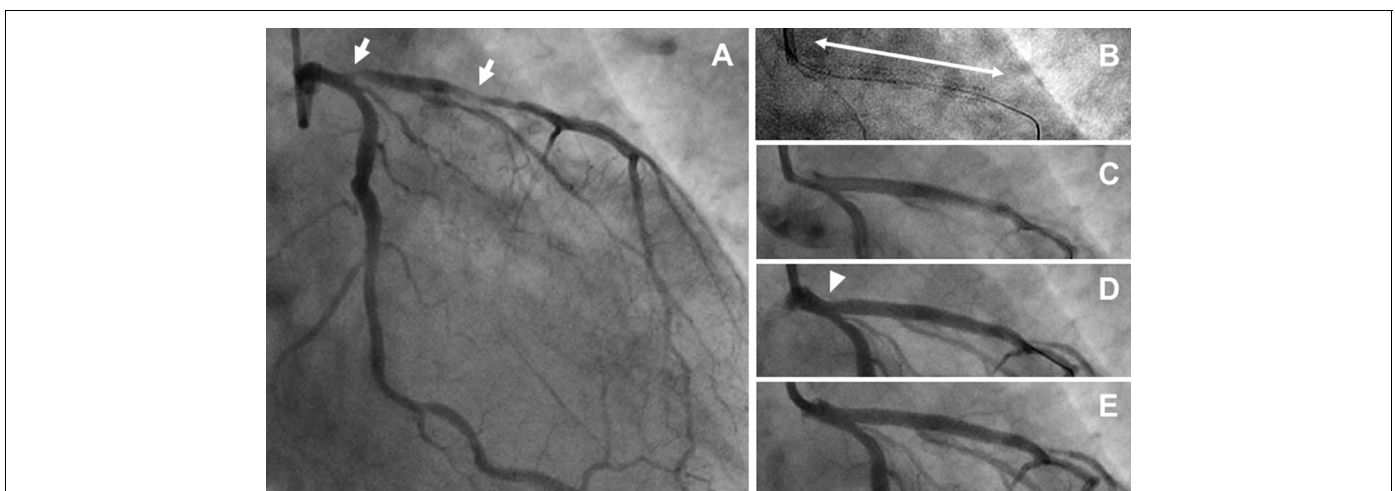
[2]) (Fig. 1A), percutaneous coronary intervention (PCI) with a new-generation DES was performed. The OCT before stenting revealed the diameter of the left main trunk (LMT) and the proximal LAD was  $3.61 \text{ mm} \times 3.25 \text{ mm}$  and  $3.13 \text{ mm} \times 2.64 \text{ mm}$ , respectively. First, we implanted a  $3.0 \text{ mm} \times 38 \text{ mm}$  everolimus-eluting stent (EES) (PROMUS Element™, Boston Scientific, Natick, MA, USA) from the LMT to the proximal LAD lesion, crossing over the LCx, at 12 atmospheres to avoid the restenosis of the edge of the stent (Fig. 1B). The images from the cross-sectional OCT (Fig. 2A) and instant reconstruction 3D OCT (Fig. 2D) demonstrated the sufficient expansion from the LMT to LAD, crossing over the ostium of LCx entirely, and good apposition of the stent struts. Good apposition to the vessel wall of the stent struts opposite the LCx was also demonstrated, suggesting that there were no findings of stent malapposition. Then, a guidewire was advanced into the LCx through the jailing struts of the ostium of the LCx, but the recrossing position was unclear in this case. After inflating a  $2.75 \text{ mm} \times 12 \text{ mm}$  balloon catheter at 12 atmospheres in the jailing struts of the LCx, the well opened jailing struts of the LCx were confirmed with a cross-sectional OCT. However, a new development of stent malapposition was confirmed opposite the LCx ostium by a cross-sectional OCT and instant reconstruction 3D OCT (Fig. 2B, arrows and E, arrow head). Thus, a KBI with a  $2.75 \text{ mm} \times 12 \text{ mm}$  balloon catheter for the LCx and a  $3.0 \text{ mm} \times 12 \text{ mm}$  balloon catheter for the LAD was inflated at 8 atmospheres. Finally, the cross-sectional OCT (Fig. 2C) and instant reconstruction 3D OCT (Fig. 2F) imaging after the KBI could clearly demonstrate the adequate expansion of the proximal portion of the stent and the disappearance of the stent malapposition. After this session, we also performed a bench test replicating the clinical situation with a phantom coronary bifurcation model and macroscopic images to evaluate this phenomenon *in vivo*. The cross-over stenting to the main branch was performed with a  $3.0 \text{ mm} \times 32 \text{ mm}$  EES in the coronary bifurcation model (Fig. 2G and I). The inflation of the jailing stent struts by a  $2.75 \text{ mm} \times 15 \text{ mm}$  balloon catheter for a side branch caused a deformation at the vessel wall opposite the side branch (Fig. 2H, arrow head, and K, arrow head). We could confirm that the stent deformation was precisely corrected by the following KBI with a  $2.75 \text{ mm} \times 15 \text{ mm}$  balloon catheter for the side branch and a  $3.0 \text{ mm} \times 15 \text{ mm}$  balloon catheter for the main branch for the bifurcation lesions (Fig. 2I and L). These *in vitro* findings (Fig. 2G–L)

were consistent with those *in vivo* (Fig. 2A–F), respectively. He had no restenosis during the CAG, which was performed 6 months after the PCI, and has remained well without any symptoms thereafter.

## Discussion

The new-generation DESs have significantly reduced the development of restenosis and stent thrombosis, and additionally lowered risk of death [1]. However, the rates of restenosis and stent thrombosis after the therapeutic stent deployment for bifurcation lesions are still comparably high. Previous clinical studies have shown that treatment with two stents for bifurcation lesions causes higher rates of procedure-related myocardial infarction without any significant differences in major adverse cardiac events (MACE), compared with treatment with single stents [6]. On the other hand, the KBI after the stent deployment for bifurcation lesions may yield clinical benefits [4,5], including (1) the full expansion of the stent struts at the ostium of the side branch for a reduction in side branch restenosis, (2) the precise correction of the stent deformation and/or distortion at the vessel wall opposite the side branch [7], and (3) the adequate expansion of the main vessel and side branch to the appropriate size. However, the strategies for those lesions are not well established [3–5] even in the new-generation DES era.

Herein, we experienced a case of a successful PCI with a single stent deployment to the bifurcation lesion from the LMT to the LAD crossing the LCx followed by a KBI for the LAD and LCx using cross-sectional OCT and 3D OCT. 3D OCT reconstructed by the automatic detection of lumen-vessel border can help to visualize the deformation of vessel or stent. Although cross-sectional OCT imaging after inflating a balloon catheter in the jailing struts of the LCx could demonstrate that the adequate opening of the jailing struts of the LCx, a new development of stent malapposition was confirmed opposite the LCx ostium by a cross-sectional OCT and instant reconstruction 3D OCT (Fig. 2B, arrows, and E, arrow head). These stent abnormalities, which may cause a high rate of restenosis and stent thrombosis contributing to a higher risk of death [7], were easily corrected by a subsequent KBI of the LAD and LCx using both cross-sectional OCT (Fig. 2C) and instant reconstruction 3D OCT (Fig. 2F) imaging. Recent clinical trials have demonstrated that the optimal rewiring of the side branches during bifurcation stenting is important for favorable stent



**Fig. 1.** The coronary angiogram (CAG) before the procedure (A), after the stent implantation from the left main trunk (LMT) to the left anterior descending (LAD) artery across the left circumflex (LCx) artery without contrast (B), the two-way arrow indicates the implanted stent site and with contrast (C), after the balloon inflation for the ostium of the LCx (D), and after a kissing-balloon inflation (KBI) for the LAD and LCx (E). The CAG revealed a 90% luminal diameter stenosis at the proximal lesion of the LAD (A, arrow), and the stent distortion after the balloon inflation for the ostium of the LCx (D, arrow head).

Download English Version:

<https://daneshyari.com/en/article/5984418>

Download Persian Version:

<https://daneshyari.com/article/5984418>

[Daneshyari.com](https://daneshyari.com)