The Journal of Emergency Medicine, Vol. 50, No. 3, pp. 477–481, 2016
Copyright © 2016 Elsevier Inc.
Printed in the USA. All rights reserved
0736-4679/$ - see front matter

http://dx.doi.org/10.1016/j.jemermed.2015.11.012

Pharmacology in Emergency Medicine

HIGH-DOSE ADENOSINE FOR TREATMENT OF REFRACTORY SUPRAVENTRICULAR TACHYCARDIA IN AN EMERGENCY DEPARTMENT OF AN ACADEMIC MEDICAL CENTER: A CASE REPORT AND LITERATURE REVIEW

Abby M. Bailey, PHARMD,* Regan A. Baum, PHARMD,* Justin Rose, MD,† and Roger L. Humphries, MD†

*Department of Pharmacy Services, Department of Pharmacy Practice and Science and †Department of Emergency Medicine, University of Kentucky Chandler Medical Center, University of Kentucky College of Pharmacy, Lexington, Kentucky

Reprint Address: Abby M. Bailey, PHARMD, Department of Pharmacy Services, Department of Pharmacy Practice and Science, University of Kentucky Chandler Medical Center, University of Kentucky College of Pharmacy, 800 Rose Street, H10, Lexington, KY 40526

☐ **Abstract—Background: Symptomatic tachycardia is a common admission diagnosis in the emergency department (ED). This can be a life-threatening condition and requires immediate attention. Supraventricular tachycardia (SVT) is commonly treated with adenosine, and successful treatment is limited to atrioventricular (AV) node-dependent SVTs as adenosine causes a transient heart block. However, there are limited data available for instances when the recommended dosing regimen (6 mg, 12 mg, 12 mg) fails to terminate SVT. Case Report: A 33-year old man was evaluated in the ED with an electrocardiogram revealing a regular narrow complex tachycardia with a heart rate of 180 beats/min and a rhythm consistent with SVT. He reported experiencing 3 days of fatigue, myalgias, palpitations, and dyspnea on exertion, but was otherwise hemodynamically stable. Attempts at chemical cardioversion with standard doses of adenosine (6 mg, 12 mg, and 12 mg) were given without success. After consultation with the cardiology service, additional doses of 24 mg and then 36 mg of adenosine were administered. The last dose of 36 mg produced sustained conversion and return to a normal sinus rhythm. The patient later underwent radiofrequency ablation of a left-sided orthodromic reciprocating accessory pathway. After 3 months of medical management, the patient had an implantable cardiac defibrillator placed for prevention of sudden cardiac death. Why Should an Emergency Physician Be Aware of This?: Each case of SVT demands immediate attention from an emergency physician. It is imperative that providers be aware of the limitations of adenosine and when it may be appropriate to deviate from standard dosing recommendations. This is in addition to collaborating with an expert in cardiac electrophysiology when initial management tactics are not successful.** © 2016 Elsevier Inc.

☐ **Keywords—adenosine; supraventricular tachycardia; dysrhythmias; cardioversion; emergency department**

INTRODUCTION

Symptomatic tachycardias represent a common admission diagnosis in the emergency department (ED) setting. These can be life-threatening conditions and require immediate medical attention to treat the dysrhythmia, stabilize the patient, and then elucidate the etiology of the underlying disorder. Supraventricular tachycardia (SVT) can be broken down into atrioventricular nodal reentrant tachycardia, atrioventricular reciprocating tachycardia, atrial tachycardia, and other less common tachycardias (1). SVT is commonly treated with adenosine, but little exists in the way of dosing recommendations when guideline-recommended doses of adenosine fail to control or terminate SVT (2,3).

CASE REPORT

A 33-year old male patient was admitted through the ED from a cardiology clinic. The patient was noted to have a

RECEIVED: 23 July 2015; FINAL SUBMISSION RECEIVED: 30 October 2015;
ACCEPTED: 10 November 2015

regular narrow complex tachycardia with a rate of 180 beats/min and a rhythm consistent with SVT. He reported experiencing 3 days of fatigue, myalgias, palpitations, and dyspnea on exertion. He had a recent diagnosis of dilatated, nonischemic cardiomyopathy (NICM) secondary to polysubstance abuse (methamphetamines, benzodiazepines, and opioids), with an ejection fraction of 25–35% along with a previous diagnosis of hypertension. The patient denied currently abusing any medications that would precipitate a dysrhythmia. However, his urine drug screen was positive for caffeine. The patient had experienced a prior episode of SVT approximately 1 month prior to his ED visit, at an outside facility. This episode was treated with chemical cardioversion using adenosine and then progressing to electrical cardioversion after initial adenosine failed to terminate SVT.

Upon arrival, his maximum heart rate was 185 beats/min. His electrocardiogram (ECG) showed SVT, with a rate of 184 beats/min (Figure 1). During initial evaluation the patient was asymptomatic except for expressing symptoms of weakness. He was hemodynamically stable with a systolic blood pressure ranging from 96–121 mm Hg. Initially, chemical cardioversion was attempted with rapid administration of intravenous adenosine (6 mg, 12 mg, and then an additional 12 mg given 1 min apart each) through an 18-gauge intravenous catheter in an antecubital vein. A stopcock was used to facilitate rapid 10-mL normal saline flush immediately after the adenosine bolus. The patient's vital signs remained similar to those observed prior to adenosine administration (heart rate of 183 beats/min and systolic blood pressure of 100–115 mm Hg), however, adenosine did not successfully terminate the SVT. Procedural sedation and synchronized cardioversion was deferred as the patient had eaten a full meal just prior to arrival in the ED and he was hemodynamically stable. The cardiology service was consulted for evaluation and definitive management of his SVT in the setting of his complex cardiovascular problems (history of cardiomyopathy, congestive heart failure, recurrent dysrhythmia, and renal insufficiency). After consultation with the cardiology service and comparison of his ECG from the patient's prior hospitalization (Figure 2), additional doses of 24 mg and then 36 mg of adenosine were administered. The last dose of 36 mg produced successful, sustained conversion and return to a normal sinus rhythm (NSR). Thirty-five minutes elapsed between the initial attempt at chemical cardioversion and achieving NSR (Figure 3).

The patient was admitted to the inpatient Cardiology service and started on propranolol 10 mg four times daily, and an electrophysiologic study was performed 2 days later along with radiofrequency ablation of a left-sided orthodromic reciprocating accessory pathway. The patient was discharged 6 days after admission. After 3 months of medical management, the patient had an implantable cardiac defibrillator placed for primary prevention of sudden cardiac death in the setting of NICM.

DISCUSSION

Supraventricular tachycardia is quite common and occurs in 1 per 500 persons and can result in a heart rate of upwards of 250 beats/min (1,4). SVT is usually narrow complex and originates through the His-Purkinje system, making adenosine or vagal maneuvers ideal for termination of the electrophysiologic event.

Prior to the 1980s, SVT was commonly treated with boluses of longer-acting medications that act on the atrioventricular (AV) node, including intravenous verapamil, propranolol, or digoxin. However, given the prolonged

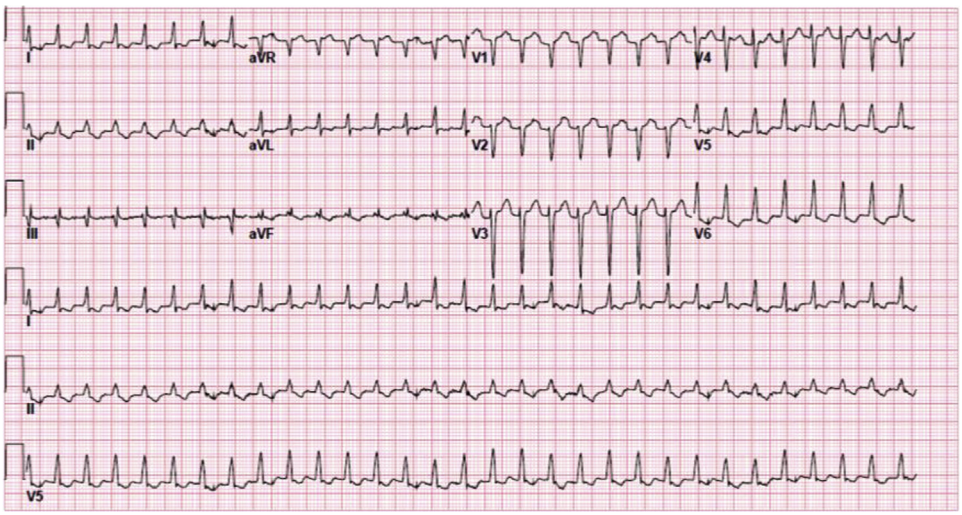

Figure 1. Baseline electrocardiogram during initial evaluation in the Emergency Department.

Download English Version:

https://daneshyari.com/en/article/6084729

Download Persian Version:

https://daneshyari.com/article/6084729

Daneshyari.com