


Available online at www.sciencedirect.com

Pediatric Dental Journal

journal homepage: www.elsevier.com/locate/pdj

Case Report

Chondroma of angle of mandible in a pediatric patient: A rare case report



Suresh K. Sachdeva MDS, Dr. *, Manoj Vengal MDS, Dr.

Department of Oral Medicine and Radiology, Vyas Dental College and Hospital, Jodhpur 342005, Rajasthan, India

ARTICLE INFO

Article history:

Received 28 September 2014

Received in revised form

11 November 2014

Accepted 15 December 2014

Available online 13 January 2015

Keywords:

Chondroma

Chondrosarcoma

Female

Mandible

Young

ABSTRACT

Chondroma is a benign neoplasm of mature hyaline cartilage, being one of the most common benign tumors of the axial skeleton, but is rare in the head region. In the facial bones, it involves anterior maxillary region adjacent to the nasal spine and nasal septum and in mandible, it involves symphysis, body, coronoid process and mandibular condyle. This tumor probably arises from remnants of the embryonal cartilaginous tissue that escapes resorption during endochondral ossification. The aim of this article is to present an unusual case of chondroma of angle region of mandible in a 9-year old female, and to discuss its clinical, imaging features along with its differential diagnosis and management. Copyright © 2014 The Japanese Society of Pediatric Dentistry. Published by Elsevier Ltd. All rights reserved.

1. Introduction

Chondroma is a benign neoplasm of mesenchymal connective tissue origin, which is composed of mature hyaline cartilage. On the basis of location, it may be either classified as enchondromas (located within the medullary cavity of the bony skeleton) or as juxta articular chondroma (related to extra skeletal cartilage) and extra skeletal chondroma or soft tissue chondroma. Juxta articular chondroma is also known as periosteal, as there is involvement of the periosteum in this type [1].

Although, chondroma is one of the most common benign tumors of the axial skeleton, but is rare in the head and neck region. In the head and neck region, it mostly involves anterior

maxilla, ands mandibular symphysis, body, coronoid process and condyle. In general, it occurs in young people, with no sex predilection. Radiographically, chondroma appears as completely or partially radiopaque with distinct borders on computed tomography (CT) as well as on plain radiography [2]. Histologically, it should be differentiated from osteoma, benign osteoblastoma, and chondroblastoma. The histological criteria for the diagnosis include chondrocytes of the cartilaginous cap arranged in clusters in lacunar spaces similar to those of normal epiphysial cartilage [3]. The definite diagnosis of a chondroma is based upon the clinical, imaging and histopathological findings. The treatment of choice is wide surgical excision.

Herewith, a rare case of chondroma of angle region of left mandible in a 9-year old female is presented.

* Corresponding author. 13/573, Gali No. 1, Khanna Colony, Sirsa 125055, Haryana, India. Tel.: +91 8764419775.

E-mail address: drsureshsachdeva7184@gmail.com (S.K. Sachdeva).

<http://dx.doi.org/10.1016/j.pdj.2014.12.001>

0917-2394/Copyright © 2014 The Japanese Society of Pediatric Dentistry. Published by Elsevier Ltd. All rights reserved.

2. Case report

A 9-year old female reported with a chief complaint of a painless swelling over left side of lower jaw, since 6 month. History of presenting illness revealed that swelling was insidious in onset, initially small, now increased to attain the present size. There was no history of trauma, fever or similar swelling elsewhere in the body. Family history and past medical and dental history was non-contributory. On clinical examination, single, nodular, bony hard and non-tender swelling of size 2 cm × 2.5 cm was present at angle of mandible on left side. The overlying skin was of normal color with intact surface and without any rise in local temperature. Regional lymph nodes were not palpable [Fig. 1(a–c)].

Intra-orally, the mixed dentition was present. Total no. of teeth were 23 including both deciduous and permanent (16,55,54,53,12,11,21,22,63,64,65,26,36,75,74,73,32,31,41,42,83, 85,46). There was carious involvement of 74 and 85. There was brownish black pigmentation of attached and marginal gingiva on the labial aspect, which was suggested of physiologic pigmentation [Fig. 1(d)].

The Orthopantomogram (OPG) revealed heterogeneous calcified mass posterior to angle of mandible on left side. Other finding showed that teeth were in the mixed dentition stage, with various permanent teeth in different stages of development [Fig. 2(a)].

The Computerized tomography scan (CT), both axial and three dimensional (3-D) view showed calcified mass on most posterior and the inner aspect of left angle of mandible, which was less calcified than adjacent bone and with irregular margin [Fig. 2(b & c)]. Routine blood investigations were within normal limits.

On the basis of history, clinical examination and imaging features, a provisional diagnosis of benign non-odontogenic neoplasm of left angle of mandible was made.

As the clinical history, examination and the radiologic features suggested a non-aggressive nature of the lesion, excision biopsy with wide margin was done and the specimen, which was encapsulated mass during surgery, was sent for microscopic examination. On microscopic examination, varying amount of chondrocytes present in the lacunar spaces. Also it was confirmed that it was a benign neoplasm and the margins were free of neoplastic cells [Fig. 3]. So a final diagnosis of chondroma of angle of mandible of left side was

made. Post operative healing was uneventful. Patient was advised regular follow-up and no recurrence was reported on follow-up [Fig. 4(a–c)].

3. Discussion

Cartilaginous tumors of the head and neck region are rare and mostly malignant [4]. Chondroma represents approximately 2.38% of cartilaginous tumors [2]. Chondroma is a benign neoplasm of unknown etiology, though a hamartomatous origin has been documented. These tumors probably arise from remnants of the embryonic cartilaginous skeleton that escape resorption during endochondral ossification [5]. Chondroma may be due to growth of germ cells with cartilaginous potential as a consequence of continuous tensions exerted on particular tendons [6].

Chondroma is composed of mature cartilage cells. Chondroma is usually discovered in the 3rd or 4th decade of life, with no sex predilection. Chondroma is rare in facial bones, in maxilla it involves anterior region adjacent to the nasal spine and nasal septum and in mandible it involves symphysis, body, coronoid process and mandibular condyle [7]. Chondroma can also develop in tissues that do not normally contain cartilage at any stage of development. Aberrant embryonic cell rests have been suggested to explain the origin of cartilaginous tumors at these sites [8]. Multidirectional differentiation of the mesenchymal cells has also been implicated in the origin of cartilaginous tumors at these sites. In the present case it involved angle region on left side of mandible, which is an unusual location for chondroma to occur. Oral soft tissue chondroma (extra skeletal) have been found in the tongue, the cheek, on the nasal surface of the soft palate and in hyperplastic palatal mucosa in denture wearer [9].

Clinically, chondroma is slow growing, asymptomatic, firm, smooth-surfaced nodules of the jaw, which may take years to become apparent. The overlying skin or mucosa is rarely involved due to the gradual expansion of the lesion [7].

Medical consultation is needed because chondroma can be a part of maffucci syndrome, oller disease or metacondromatosis. In Maffucci syndrome, there will be multiple enchondromas, hemangiomas and lymphangomas will be seen. These enchondromas have more malignant transformation into chondrosarcoma, may cause pathological

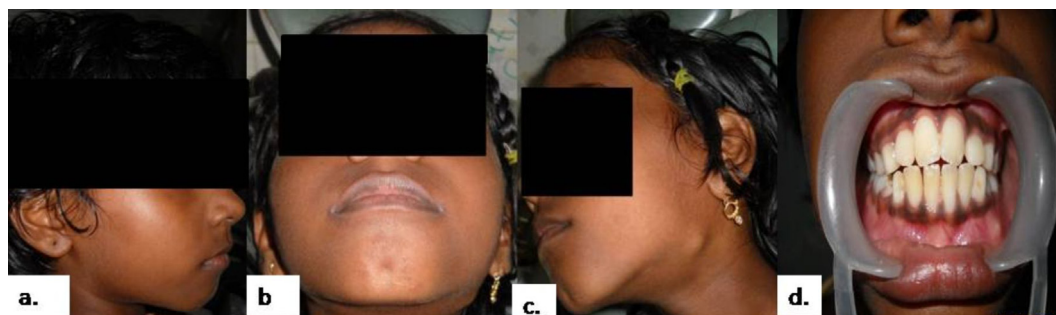

Fig. 1 – (a) shows apparently normal right side of the face. Single, nodular, bony hard and non-tender swelling present at angle of mandible on left side with intact overlying skin (b,c). Intra-orally, there was mixed dentition with dental caries in 74 and 85 (d).

Download English Version:

<https://daneshyari.com/en/article/6263007>

Download Persian Version:

<https://daneshyari.com/article/6263007>

[Daneshyari.com](https://daneshyari.com)