Pathology (■ 2017) ■(■), pp. 1–12

GYNAECOLOGICAL PATHOLOGY

Ovarian sex cord-stromal tumours: an update in recent molecular advances

Diana Lim[1,2] and Esther Oliva[3]

[1]Department of Pathology, National University Hospital, Singapore; [2]Translational Centre for Development and Research, National University Health System, Singapore; and [3]Department of Pathology, Massachusetts General Hospital, Boston, MA, United States

Summary

Sex cord-stromal tumours (SCSTs) consist of a heterogeneous group of neoplasms with diverse clinicopathological features and biological behaviour. They often present as a diagnostic challenge as they have varied and occasionally overlapping histomorphology and some may even mimic non-SCSTs. An accurate diagnosis is important for therapeutic and prognostic purposes. The use of a panel of immunohistochemical markers which are sensitive and specific for sex cord-stromal differentiation such as α-inhibin, calretinin, SF-1 and FOXL2, may be helpful in confirming the cellular lineage of these tumours, but is of limited utility in distinguishing between the different tumour types within this category. Additionally, the development of new therapeutic strategies in patients with SCSTs is also hampered by the infrequent occurrence of these neoplasms.

Recent molecular analyses of some SCSTs has led to the discovery of novel molecular events, which may have important diagnostic, prognostic and therapeutic implications. The salient pathological features, management issues and recently described genetic aberrations in adult and juvenile granulosa cell tumours as well as Sertoli–Leydig cell tumours are discussed in this review, with particular emphasis on the clinical significance of *FOXL2* and *DICER1* mutations. An in-depth understanding of the molecular pathogenesis underlying SCSTs may aid in improving tumour classification and disease prognostication and also potentially lead to the discovery of more effective treatment strategies.

Key words: Sex cord-stromal; FOXL2; DICER1; immunohistochemistry; molecular; ovary.

Received 8 August, accepted 17 October 2017
Available online: xxx

INTRODUCTION

Sex cord-stromal tumours (SCSTs) are a diverse group of neoplasms derived from either gonadal sex cord cells (granulosa and sertoli cells), gonadal stromal cells (theca cells), or fibroblasts.[1] They account for 8% of all primary ovarian tumours and encompass entities with widely varied clinicopathological features and biological behaviour. In the most recent World Health Organization (WHO) classification of tumours of the female reproductive organs, SCSTs are separated into pure stromal, pure sex cord and mixed SCSTs[2] (Table 1). Whilst most tumours have characteristic morphological appearance, some can exhibit unusual or overlapping features and even mimic non-SCSTs. In these instances, ancillary techniques, such as immunohistochemistry may be useful in confirming the cellular lineage of these tumours. Most SCSTs express α-inhibin, calretinin and steroidogenic factor-1 (SF-1) and are typically negative for epithelial and germ cell tumour markers. More recently, FOXL2 (Foxhead box protein L2) has also been identified to be a sensitive and specific marker of sex cord-stromal differentiation. However, no immunomarker shows absolute sensitivity or specificity for SCSTs and most have limited utility in distinguishing between the different tumour types within this category.

Recent studies have led to the discovery of novel molecular events, which may have important diagnostic, prognostic and therapeutic implications in this group of tumours. In this review, we discuss the salient pathological features, management issues and recently described genetic aberrations in granulosa cell and Sertoli–Leydig cell tumours, and examine the clinical significance of these molecular findings.

GRANULOSA CELL TUMOURS

Granulosa cell tumours represent 90% of all ovarian SCSTs and constitute ~5% of ovarian cancers. They are divided into two categories: adult GCTs (AGCTs) and juvenile GCTs (JGCTs) on the basis of differing clinicopathological characteristics. Evidence provided by various molecular studies also indicates that these tumours are distinct entities.

Adult granulosa cell tumours

AGCTs constitute 95% of all granulosa cell tumours and are the most common malignant SCSTs.[3,4] They can occur at any age but are commonly seen in perimenopausal or early post-menopausal women with a peak age incidence between 50 and 55 years.[5] Patients often present with oestrogenic manifestations such as menometrorrhagia or post-menopausal bleeding and some may have underlying endometrial hyperplasia and/or adenocarcinoma. Rarely, AGCT can be associated with androgenic manifestations, especially if they are cystic.[6] Patients may also present with abdominal pain and distension secondary to a large pelvic mass.

The majority (90%) of tumours are unilateral with an average diameter of 12 cm, although size may vary from microscopic to ~30 cm. Cut surface typically reveals a tan (Fig. 1A) to yellowish solid or solid-cystic appearance, but

Print ISSN 0031-3025/Online ISSN 1465-3931 © 2017 Published by Elsevier B.V. on behalf of Royal College of Pathologists of Australasia.
DOI: https://doi.org/10.1016/j.pathol.2017.10.008

Please cite this article in press as: Lim D, Oliva E, Ovarian sex cord-stromal tumours: an update in recent molecular advances, Pathology (2017), https://doi.org/10.1016/j.pathol.2017.10.008

ARTICLE IN PRESS

Table 1 WHO classification of ovarian sex cord-stromal tumours

Pure stromal tumours
Fibroma
Cellular fibroma
Thecoma
Luteinised thecoma associated with sclerosing peritonitis
Fibrosarcoma
Sclerosing stromal tumour
Signet-ring stromal tumour
Microcystic stromal tumour
Leydig cell tumour
Steroid cell tumour
Steroid cell tumour, malignant
Pure sex cord tumours
Adult granulosa cell tumour
Juvenile granulosa cell tumour
Sertoli cell tumour
Sex cord tumour with annular tubules
Mixed sex cord-stromal tumours
Sertoli–Leydig tumours
Well differentiated
Moderately differentiated
With heterologous elements
Poorly differentiated
With heterologous elements
Retiform
With heterologous elements
Sex cord tumour, NOS

NOS, not otherwise specified; WHO, World Health Organization.

rarely, tumours may be predominantly cystic. On microscopic examination, AGCTs can exhibit a wide spectrum of morphological features, with a combination of growth patterns often encountered within the same tumour. The granulosa cells have ovoid or round nuclei, pale chromatin and often, nuclear grooves, imparting a 'coffee-bean' appearance (Fig. 1B). The cytoplasm is usually scant, although luteinised cells with moderate to abundant eosinophilic cytoplasm, round to ovoid nuclei with prominent nucleoli and lacking nuclear grooves may be seen.[7,8] Mitotic rate is variable but generally low (<5/10 HPF). Bizarre cells may be identified in ~2% of AGCTs[9] and rare tumours with sarcomatous transformation[10] or hepatic differentiation[11] have been reported. Cells can be arranged in a variety of architectural patterns including diffuse or sheet-like growth, microfollicular, macrofollicular, trabecular, insular, tubular (solid or hollow), corded, watered silk and gyriform (zigzag cords). Call–Exner bodies (Fig. 1C) are a feature of the microfollicular pattern, and are characterised by microcystic spaces containing eosinophilic basal lamina material. The presence of nuclear grooves and Call–Exner bodies are often considered to be pathognomonic of AGCTs, however these features may be lacking in some tumours and their absence does not preclude a diagnosis of AGCT.

Chromosomal aberrations

Using cytogenetic[12] and comparative genomic hybridisation analyses,[13] trisomy of chromosomes 12 and 14 and monosomy of chromosome 22 have been detected in a subset of AGCTs.[12,13] Caburet *et al.* also reported the presence of supernumerary chromosomes 8, 9, 12 and 14 as well as partial or complete loss of chromosomes 1p, 13p, 16, 11 and 22, with a statistically significant non-random association for +14 with −22 and +7 with −16q.[14]

FOXL2

In a landmark study using whole-transcriptome sequencing, Shah *et al.* identified a recurrent, somatic missense mutation in codon 134 (402C→G) of *FOXL2* (Fig. 2) in four AGCTs.[15] This mutation was also identified in 86/89 (97%) additional AGCTs, but only in 3/14 (21%) thecomas and 1/10 (10%) JGCTs, and none of the 49 ovarian SCSTs of other types, 149 epithelial ovarian tumours and 180 breast carcinomas. It has since been postulated that this mutation is the driver event in AGCTs.[15]

FOXL2 is a single-exon gene of 2.7 kb located at 3q23 that encodes for a 376 amino acid protein, which is a member of the forkhead–winged helix family of transcription factors containing a highly conserved DNA-binding forkhead domain. *FOXL2* is selectively expressed in the mesenchyme of developing mouse eyelids and in the adult ovarian follicle. It is one of the earliest markers of ovarian differentiation, and is essential for the normal development of granulosa cells.[16,17] FOXL2 has also been linked to the regulation of several key biological processes, such as apoptosis, oxidative stress response and cell proliferation. Several targets of FOXL2 have been identified in gonadal cells[18] including genes fundamental to granulosa cell function and the development of ovarian follicles.[19] Regulation of gene expression by FOXL2 involves interactions with other transcription factors such as nuclear receptors and the SMAD family of transcription factors.[20,21]

Germline mutations in *FOXL2* result in the blepharophimosis, ptosis, and epicanthus inversus syndrome (BPES), either with or without associated premature ovarian failure.[22] The somatic missense point mutation (C402G)

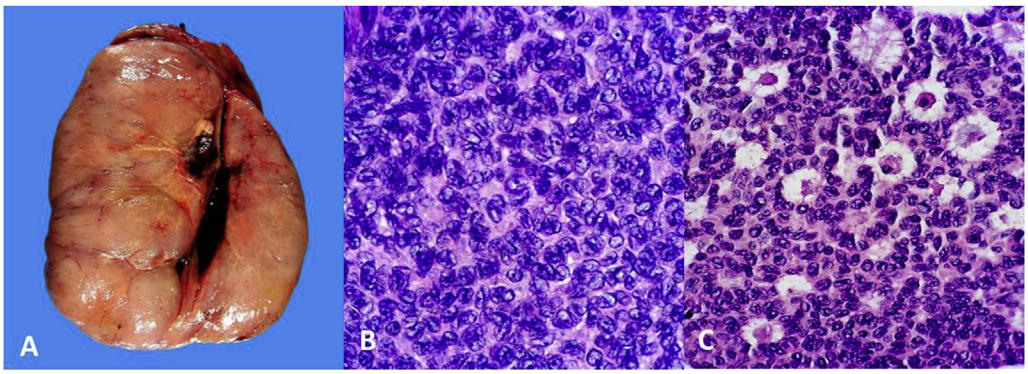

Fig. 1 Adult granulosa cell tumour. (A) The tumour is solid with a tan cut surface. (B) The cells have ovoid nuclei and longitudinal nuclear grooves. (C) Call–Exner bodies are noted.

Please cite this article in press as: Lim D, Oliva E, Ovarian sex cord-stromal tumours: an update in recent molecular advances, Pathology (2017), https://doi.org/10.1016/j.pathol.2017.10.008

Download English Version:

https://daneshyari.com/en/article/6555559

Download Persian Version:

https://daneshyari.com/article/6555559

Daneshyari.com