Magnetic Resonance Imaging 51 (2018) 113–119

Contents lists available at ScienceDirect

Magnetic Resonance Imaging

journal homepage: www.elsevier.com/locate/mri

Original contribution

Pancreatic stiffness response to an oral glucose load in obese adults measured by magnetic resonance elastography

Ruoyun Ji[a], Jiahui Li[a], Ziying Yin[b], Yanqing Liu[a], Lizhuo Cang[a], Min Wang[a], Yu Shi[a,*]

[a] Department of Radiology, Shengjing Hospital of China Medical University, Shenyang, China
[b] Department of Radiology, Mayo Clinic, Rochester, MN, USA

ARTICLE INFO

Keywords:
Magnetic resonance elastography
Pancreas
Glucose
Obese

ABSTRACT

Background: To test the feasibility of magnetic resonance elastography (MRE) for assessing changes in pancreatic stiffness of obese adults administered an oral glucose load.

Methods: MRE scans were performed on 21 asymptomatic obese volunteers (BMI ≥ 27 kg/m^2) before and after receiving a 75-g oral glucose load, and repeated in 7 days without a glucose load. Shear waves at 40 and 60 Hz were introduced into the upper abdomen by a pneumatic drum driver (diameter of 12 cm). Two radiologists subjectively graded the overall quality of the wave images of the pancreas using a scale from 1 to 4, in which suboptimal image quality was considered to be scores of 1 and 2.

Results: Good inter-observer agreement was found for image quality at both frequencies (kappa = 0.805 for 40 Hz and 0.762 for 60 Hz). The median overall image quality score was significantly higher in 40 Hz than that of 60 Hz (4 versus 2). At 40 Hz, pancreatic stiffness in response to oral glucose had a decrease of 6.7% (pre vs post: 1.17 ± 0.13 kPa vs 1.08 ± 0.12 kPa; $P < 0.001$), whereas the change in stiffness was not significant at 60 Hz (pre vs post: 2.01 ± 0.21 kPa vs 2.02 ± 0.24 kPa; $P = 0.695$). Excellent intersession agreement was found for MRE acquisitions at 40 Hz with an overall intraclass correlation coefficient = 0.947 (95% confidence interval: 0.913–0.967).

Conclusion: MRE at 40 Hz provides good-quality wave images and high sensitivity to changes in the mechanical properties of pancreatic tissue in obese volunteers after an oral glucose load.

1. Introduction

Pancreas disorders such as pancreatitis and pancreatic cancer is one of the most frequent gastrointestinal causes for hospitalization worldwide [1]. Accurate discrimination of chronic pancreatitis, premalignant lesions, and pancreatic cancers with overlapping radiological and clinical features is highly challenging in the clinical setting [2–5]. Moreover, highly specific and sensitive imaging and/or laboratory markers that can complement the current imaging modalities are not available for the early detection of pancreatic diseases [4,6–8].

Magnetic resonance elastography (MRE) as an emerging imaging method can measure the mechanical properties of biological tissues by imaging and processing the propagating shear waves [9,10]. Many pathological processes, such as inflammation, fibrosis, tumor, and congestion have been shown to cause marked changes in the MRE-assessed liver stiffness, which is manifested by the changed wavelengths of the propagating shear wave traveling though diseased tissues [11,12]. MRE studies in pancreas have also demonstrated the promise in differentiating normal pancreas from diseased ones [13,14]. In pancreatic MRE, pervious feasibility and reproducibility studies were performed at vibration frequencies of 40 and 60 Hz using a spin-echo echo-planar-imaging (SE-EPI) sequence [14–16]. However, further evaluation of the wave quality at different vibrational frequencies among individuals with different Body Mass Index (BMI) has not been investigated. The wave penetration in individuals with high BMIs tend to be inhibited by the large volumes of tissue between the MRE driver and the deep-seated pancreas [15]. Given overweight/obesity is an established risk factor for both pancreatitis and pancreatic cancer, optimizing the driver set-up for the effective wave penetration in large BMI subjects is needed [17].

In pancreas, the blood perfusion, especially to the islets, is normally coupled with insulin released in response to changes in the concentrations of blood glucose [18]. The blood glucose level increases markedly and peaks 30–40 min after the administration of a 75-g oral glucose load (OGL) [19]. Given by the fact that increased blood perfusion could affect the mechanical properties of various organs [16], we hypothesized that with the optimized driver set-up, pancreatic MRE would be feasible and sensitive for detecting changes in the pancreatic

* Corresponding author at: Department of Radiology, Shengjing Hospital, China Medical University, No. 36, Sanhao Street, Heping District, Shenyang 110004, China.
E-mail address: 18940259980@163.com (Y. Shi).

https://doi.org/10.1016/j.mri.2018.04.019
Received 23 February 2018; Received in revised form 30 April 2018; Accepted 30 April 2018

stiffness of obese volunteers in response to an OGL. To the best of our knowledge, MRE has not yet been used to investigate the effects of an OGL on the pancreas. Hence, in this study, we first evaluated the performance of different drivers for obese volunteers. Then, we used the optimized driver set-up to characterize the changes of pancreatic stiffness in response to an OGL.

2. Materials and methods

2.1. Study participants

This prospective study was compliant with the Health Insurance Portability and Accountability Act and approved by the Institutional Review Board of our local hospital. Written informed consent was obtained from all participants, who were recruited from the community and hospital visitors and staff between March 2017 and October 2017. Participants aged ≥18 y with a BMI ≥27 kg/m^2 were initially enrolled. Exclusion criteria included the following: (1) history of pancreatitis or pancreatic mass; (2) pregnancy; (3) Type 1 diabetes or evidence of glucose intolerance on a standard 75-g oral glucose tolerance test (OGTT); (4) alcohol or tobacco abuse (for excluding patients with chronic asymptomatic pancreatitis); (5) abnormal serum amylase and lipase levels; (6) abnormal pancreatic magnetic resonance imaging (MRI) findings as determined by a senior radiologist with 20 years of experience in abdominal imaging; and (7) methodological failure of MRE scan, including poor breath holding and intolerance to the driver stimulus. Finally, the study included a total of 21 obese adult volunteers (mean age: 39.7 ± 10.6 years; BMI: 30.0 ± 2.0 kg/m^2; 12 male/9 female).

This study had 2 stages. The first stage compared the performance of 6 different drivers on 5 volunteers at both 40 Hz and 60 Hz, respectively. The second stage used the optimal driver evaluated in the first stage to perform MRE scans on all study participants before and after an OGL at both 40 Hz and 60 Hz.

2.2. First stage

Five of the 21 volunteers were recruited to participate. Five round pneumatic drum drivers with the diameters of 19 cm (D19), 12 cm (D12), 9 cm (D9), 7.5 cm (D7.5), and 4 cm (D4) [20] and one rectangular soft driver (19 cm × 14 cm) [15] were separately placed in the middle of the upper abdomen and tightly secured with an elastic band that was wrapped around the participant (Fig. 1). The D12, D9, D7.5, and D4 drivers were composed of acrylic plastic, and the drum head consisted of 0.02-cm thick polycarbonate plastic, similar to the cardiac driver reported by Kolipaka [20]. The soft driver is a pillow-like, passive driver and consists of a soft, inelastic fabric cover over a porous, springy mesh, previously used in renal and pancreatic studies [15,21].These 5 drivers were developed in house by the Mayo Clinic (Rochester, MN, USA) and were given to our institution, along with a service agreement. The largest D19 driver is a commercial product of MR Touch (Resoundant, Rochester, MN, USA). Briefly, the results showed that D19 and D12 produced the best wave images (details in the Results). D12 produced slightly better wave images than D19 and was used for all study participants in the second stage of the study.

2.3. Second stage

Twenty-one participants underwent 3 MRE scanning sessions (session 1: before an OGL, session 2: after an OGL, and session 3: repetition of session 1 in 7 days). Each MRE session consisted of 2 MRE scans at 40- and 60 Hz. Each participant was asked to fast overnight for at least 6 h before undergoing MRE. After the first MRE session, the participant ingested 300 mL of a solution containing 75-g of glucose over a 1-min period, and the time right after drinking was set as time zero. Thirty-five minutes later, the participant underwent the second MRE session. Between session 1 and 2, the participant was removed from the MRE table and allowed to rest. Seven days later, each participant underwent the third MRE session, which was equivalent to the first session (no ingestion of glucose solution), to test the reproducibility of MRE acquisition. The same operator performed all the exams.

2.4. MRE pulse sequence

All MR examinations were performed on a 3.0 Tesla (T) MRI scanner (Signa EXCITE HD MRI System; GE Healthcare) using an 8-channel phased-array surface coil. The three-dimensional wave field was acquired by a two-dimensional, single-shot, SE-EPI sequence with flow-compensated motion-encoding gradients. Thirty-two consecutive slices were acquired within 5 breath holds (4 of 22 s and 1 of 11 s) at 40 Hz and 3 breath holds (3 of 21 s) at 60 Hz. The other imaging parameters for MRE were as follows: repetition time = 1375 for 40 Hz and 1334 for 60 Hz; the 40-Hz and 60-Hz echo times for any particular patient were the same, and ranged from about 37.7–40.5 ms, depending on the patient weight; field of view = 36–44 cm; matrix size = 96 × 96; slice thickness = 3.5 mm; phase offsets = 3.

2.5. MRE data processing and imaging analysis

The post-processing software was integrated with the MRE pulse sequence. Within 2 min after MRE scanning, the wave images were processed automatically to generate tissue stiffness maps (elastograms), which quantitatively depict mechanical properties. The elastogram was created with a direct inversion (DI) algorithm as previous described

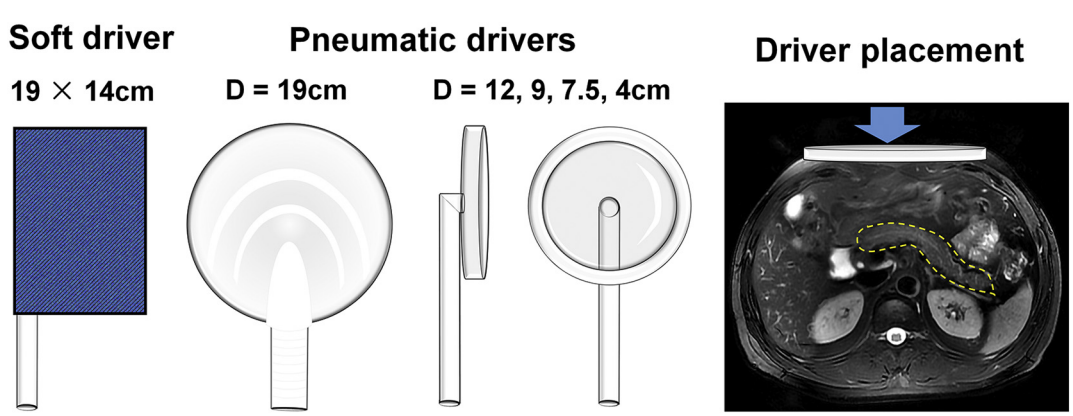

Fig. 1. Representative images of different drivers for magnetic resonance elastography of the pancreas. From left to right: soft rectangular driver, pneumatic driver with the diameter of 19 cm (a commercial product of GE MR-Touch system), and pneumatic drivers with the diameter of 12 cm, 9 cm, 7.5 cm, and 4 cm, as well as MRE setup with the passive driver positioning.