



Early results on canine fetal kidney development: Ultrasonographic evaluation and value in prediction of delivery time

Elaine Mayumi Ueno Gil^{*}, Daniela Aparecida Ayres Garcia, Amália Turner Giannico, Tilde Rodrigues Froes

Federal University of Paraná, Brazil

ARTICLE INFO

Article history:

Received 1 September 2017
Received in revised form
9 November 2017
Accepted 11 November 2017
Available online 16 November 2017

Keywords:

Dog
Pregnancy
Ultrasound monitoring
Delivery date prediction
Gestational age

ABSTRACT

To date there have been no studies that describe the ultrasonographic evaluation of kidney development in canine fetuses. The aim of this prospective and longitudinal study was to monitor fetal kidney development with ultrasound and use fetal kidney measurements as a complementary biometric index for estimation of gestational age. Ultrasonographic examinations were performed on 15 clinically healthy pregnant bitches every four days from 30th day of pregnancy, until visualization of the fetal renal pelvis was no longer possible. Four distinct periods of ultrasonographic canine fetal kidney development were defined. Kidney length and renal pelvis distention were measured on longitudinal plane images. The fetal kidney ranged from 0.40 cm to 2.30 cm in length, and diameter of the pelvis ranged from 0.06 cm to 0.17 cm, however by the end of gestation the renal pelvis was no longer dilated and so its diameter could not be measured. Statistical analysis confirmed a relationship between gestational age and fetal kidney growth. Ultrasonographic evaluation of fetal kidney development is simple to perform. There is a strong correlation between gestational age and kidney length, which allowed generation of an equation to estimate delivery date with high sensitivity between 48 and 52 days of pregnancy. Fetal organ development can be considered complete when the renal pelvis is no longer dilated, this finding can assist the ultrasonographer in staging the gestation by prompting examination for fetal intestinal motility which begins at the same gestational age. Measurement of fetal kidney length can be used in conjunction with other methods to estimate gestational age and predict delivery time.

© 2017 Elsevier Inc. All rights reserved.

1. Introduction

Accurate determination of gestational age allows estimation of the time of delivery, such that breeders and veterinarians can plan for an assisted delivery, if required, thus helping to reduce peripartum losses [1,2]. If hormonal assays and determination of ovulation time are not possible, estimation of gestational age can be based on the time of first ultrasonographic appearance of specific embryonic and fetal structures [3–6]. However, this method is only accurate to within one or two days. Therefore, new methods for more accurate determination of the gestational age in dogs would help to reduce the risk of death as consequence of premature C-section.

Several ultrasonographic examinations, including identification

of: fetal liver, stomach, bladder, and heart have been reported to accurately estimate gestational age [5,7]. Recently, high-definition ultrasound visualization of the renal pelvis in feline fetuses was reported [7], and this technique allows the final stage of gestation to be identified more accurately.

Mammalian kidney formation (nephrogenesis) begins in the intermediate mesoderm with early development of the kidney: pronephros, mesonephros, and metanephros. Pronephros and mesonephros are transient excretory systems and disappear without contributing to a permanent renal system and metanephros involves formation of a permanent kidney [8]. Depending on the species, nephrogenesis ceases shortly after delivery but, in the dog, the kidney continues to develop in the first weeks postpartum [9]. Therefore, it has been hypothesized that due to the different embryological stages of renal development the kidneys might appear ultrasonographically different during distinct stages of pregnancy.

The kidneys are first visible ultrasonographically in the canine

^{*} Corresponding author. Federal University of Paraná, Rua dos Funcionários 1540, Juvevê, 80035-050 Curitiba City, Paraná State, Brazil.

E-mail address: elainegil07@gmail.com (E.M.U. Gil).

fetal abdomen between days 40–46 of pregnancy [10] and limited information about their development has been reported. Initially they appear hypoechoic with a dilated, anechoic renal pelvis [5], but as gestation progresses, the renal cortex can be differentiated from the medulla and the less dilated pelvis [11]. However, high-resolution ultrasound imaging provides a better assessment of fetal development, allowing the identification of detailed changes in the appearance of the fetal kidney over shorter periods of time relating to gestational age. In man, ultrasound scanning has been used to monitor the normal development of fetal anatomy and to detect nephropathies based on abnormalities relating to parenchyma and/or size of kidney and renal pelvis [12,13].

There are no previous studies describing the ultrasonographic evaluation of kidney development in canine fetuses. Our hypothesis is that it is possible to monitor the development of fetal kidneys using ultrasonography and to use fetal kidney measurements as a complementary biometric index for estimation of gestational age. The purpose of this study was fourfold: (1) to describe the ultrasonographic development of the canine fetal kidney and correlate this with gestational age; (2) to assess the degree of correlation between gestational age and kidney length; (3) to evaluate the degree of correlation between gestational age and the diameter of renal pelvis; and (4) to determine a regression equation for estimation of gestational age from kidney length.

2. Materials and methods

2.1. Patient selection

Fifteen clinically healthy pregnant bitches were recruited in a prospective and longitudinal study. Breeds represented were: English Bulldog (4), American Staffordshire Terrier (1), Miniature Schnauzer (4), Pug (2), Pekingese (1), French Bulldog (1), Yorkshire Terrier (1) and Chinese Crested (1). Ages ranged from one to six years and weight between 3 and 26 kg. The number of fetuses identified in each pregnancy ranged from three to nine fetuses. Bitches that were unavailable for serial examinations, i.e. due to late pregnancy (more than 35 days of pregnancy) at the time of the first presentation, date of delivery not reported by owners, and bitches presented with concomitant disease or receiving diuretic drugs were excluded from this study. Care was taken to ensure that bitches did not drink a large amount of water before the ultrasound examination. All fetuses from a pregnancy in which any structural abnormalities were detected by ultrasonography were also excluded. All procedures were conducted in accordance with the

institutional Animal Use Committee guidelines.

2.2. Equipment and ultrasound imaging

Two-dimensional ultrasonographic evaluations were performed using a MyLab™30VET Gold (Esaote, Genova, Italy) with a 7.5–12 MHz high-resolution linear multifrequency transducer (LA523 reference – Esaote, Genova, Italy).

Bitches were positioned in dorsal recumbency using a sponge trough. Abdominal hair was clipped to optimize ultrasonographic image acquisition and acoustic gel was applied to the transducer. The protocol as described by Gil et al. [14] was used to evaluate as many fetuses as possible in each bitch, and ultrasound images were acquired in a clockwise circle. The gain, focus and depth penetration was adjusted for each fetus during examination to optimize the image quality.

Ultrasonographic examinations were performed from 30th day after first mating or insemination for pregnancy diagnosis. Examinations were repeated every four days until it was no longer possible to visualize the renal pelvis. From that examination onward, daily assessments were made until delivery.

Gestational age was estimated in days of pregnancy, using the descriptions of Yeager et al. [5] combined with assessment of the development of fetal bowel as reported by Gil et al. [15]. Confirmation of gestational age was made after delivery, in days from delivery, by counting backward (delivery as Day 0); normal gestational duration was considered to be 57–63 days due to the variability of proestrus and estrus periods in dogs [16]. Evaluations were performed on as many fetuses as possible on each occasion, but they were not performed if fetal positioning was sub-optimal for ultrasonographic measurements of fetal kidneys. Intrauterine fetal abdomens were assessed in the transverse and dorsal planes of each fetus (Fig. 1). In all patients, a complete survey of fetal anatomy was performed first; giving priority to the examination of the kidney. Images of fetal kidneys were recorded in longitudinal and dorsal sections (Fig. 1B). Two experienced ultrasonographers (one of whom is a member of Brazilian College of Veterinary Radiology) were responsible for image acquisition throughout the study (Daniela Garcia; D.G.; and Elaine Gil; E.G.); evaluations were not blinded since an interobserver study was not the objective of this research.

2.3. Ultrasonographic measurements

After identification of the fetus, the fetal abdomen was scanned

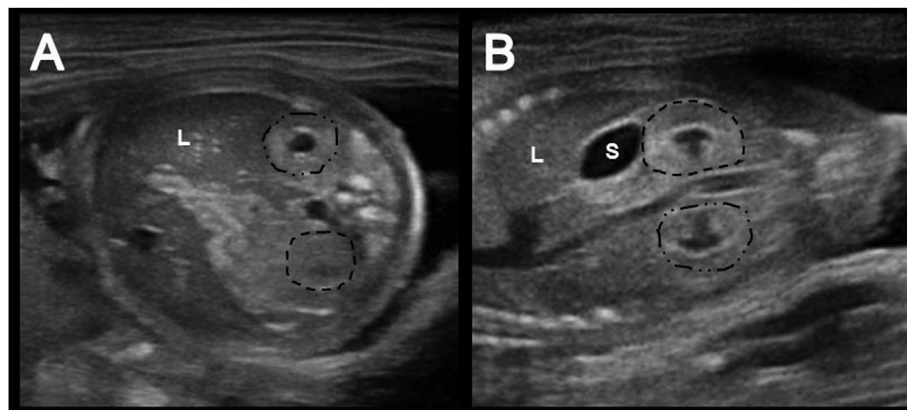


Fig. 1. Ultrasonographic imaging of canine fetus demonstrating: (A) Fetal abdomen in transverse plane with right kidney (dots and dashes) adjacent to the liver (L) and left kidney (dashes) in transverse plane; (B) Fetal abdomen in the dorsal plane with right kidney (dots) and left kidney (dashes) adjacent to the stomach (S) in longitudinal plane. L, liver; S, stomach.

Download English Version:

<https://daneshyari.com/en/article/8427745>

Download Persian Version:

<https://daneshyari.com/article/8427745>

[Daneshyari.com](https://daneshyari.com)