Medical Mycology Case Reports 19 (2018) 45–48

Contents lists available at ScienceDirect

Medical Mycology Case Reports

journal homepage: www.elsevier.com/locate/mmcr

Histoplasmosis: An oral malignancy-like clinical picture

Tomasz Chroboczek[a], Julie Dufour[a], Alain Renaux[b], Christine Aznar[c,d], Magalie Demar[c,d], Pierre Couppie[a,d], Antoine Adenis[d,e,*]

[a] Service de Dermatologie Vénérologie, CH de Cayenne, Cayenne, France
[b] Service d'Oto-Rhino-Laryngologie, CH de Cayenne, Cayenne, France
[c] Laboratoire Hospitalo-Universitaire de Parasitologie-Mycologie, CH de Cayenne, Cayenne, France
[d] Ecosystèmes Amazoniens et Pathologies Tropicales, EA3593, Université de Guyane, Cayenne, France
[e] Centre d'Investigation Clinique Antilles-Guyane, Inserm CIC1424, CH de Cayenne, Cayenne, France

ARTICLE INFO

Keywords:
Histoplasma capsulatum
Histoplasmosis
HIV
Oral
Differential diagnosis

ABSTRACT

HIV-associated histoplasmosis is mainly misdiagnosed for granulomatous diseases, such as tuberculosis. Nonetheless, malignancy-like lesions have been reported sporadically in HIV-infected patients. Although the main reported lesions are erosive or ulcerated, here a rare case of oral tumor is reported. This case raises the awareness of this presentation, and the importance of accurate identification in the laboratory. Performing systematic specific stains for fungal elements and culture on tissue samples ensures accurate differential diagnosis.

1. Introduction

Histoplasma capsulatum is responsible for histoplasmosis, a deep systemic mycosis with worldwide distribution that can affect both immunocompetent and immunocompromised individuals [1]. Histoplasmosis is mainly an airborne disease. Disruption of soils contaminated by *H. capsulatum* aerosolizes microconidia which are eventually inhaled by a host [1].

Although it is mostly asymptomatic and spontaneously resolutive in immunocompetent persons, histoplasmosis is symptomatic and disseminated in 95% of HIV-infected patients with a CD4 count less than 200/mm^3 [2]. In endemic areas, the pathophysicological mechanism that leads to disease remains debated (new infection or endogenous reactivation) [3].

During HIV infection, the evolution is highly variable, from extreme latency to fulminant forms [2]. The most frequent presentation is subacute, with symptoms evolving for over one or two months. The clinical presentation is misleading, with non-specific symptoms. Fever, fatigue and weight loss are almost constant. The presence of respiratory signs, and/or digestive signs, and/or superficial lymphadenopathies is frequent. Neurological, oral and cutaneous involvements are less frequent. For 10–20% of patients, the presentation is fulminant, similar to septic shock and rapidly fatal [4].

The diagnosis of histoplasmosis requires pathological investigations that are often invasive (bone marrow sample or tissue biopsy). Moreover, it is necessary that clinicians suspect the diagnosis when facing certain clinical situations, in order to ask for specific fungal investigations [4]. Among these are the direct examination of a fresh sample and fungal culture which remains the gold standard method despite its low sensitivity and the slow growth rate of the fungus in culture (up to six weeks) [1,5]. Among non-culture-based diagnostic tests, serology is not very contributive in HIV-infected patients and molecular tools are not commercialized yet. However, robust enzyme immunoassays (EIAs) on urine, blood or bronchoalveolar lavage are being commercialized [6]. Recent developments in monoclonal antigen detection in urine and blood are promising since the most sensitive EIA developed to date has only been available in the USA [7]. Standard biological examinations are not specific but may orient clinicians.

While waiting for a mycological gold standard-based diagnosis, when clinical suspicion is high, clinicians have two options for treatment initiation according to disease severity: intravenous liposomal amphotericin B (L-AmB) for severe cases or oral itraconazole for non-severe cases [8]. Although L-Amb has shown its fungicidal activity and its efficacy on survival, it is nephrotoxic [9]. L-AmB or alternative lipid formulation of AmB at the same dosage are safer and may be preferred to Deoxycholate-AmB. Itraconazole is fungistatic and exposes to drug-drug interactions if the treatment of potential coinfections and or antiretroviral therapy need to be introduced at the same time. This is compounded by a reduced bioavailability during HIV infection, which makes reaching the recommended effective blood levels long and difficult [1].

Despite numerous publications on HIV-associated histoplasmosis,

* Corresponding author at: Centre d'investigation clinique Antilles-Guyane, Centre Hospitalier de Cayenne, Av. Des flamboyants, BP6006, 97306 Cayenne CEDEX, France
E-mail address: antoine.adenis@gmail.com (A. Adenis).

https://doi.org/10.1016/j.mmcr.2017.11.001
Received 7 December 2016; Received in revised form 12 September 2017; Accepted 24 November 2017
2211-7539/ © 2017 The Author(s). Published by Elsevier B.V. on behalf of International Society for Human and Animal Mycology. This is an open access article under the CC BY-NC-ND license (http://creativecommons.org/licenses/BY-NC-ND/4.0/).

the true burden of HIV-associated histoplasmosis remains unknown in endemic areas [1,10]. Nevertheless the disease may rank among the top causes of AIDS-related deaths in Latin America and probably accounts for thousands of deaths every year while being undiagnosed [11]. The disease has been stated a neglected disease because, even in endemic areas, physicians awareness seems insufficient and a few laboratories are able to perform the diagnosis [6,10]. With no access to diagnostic tools or adapted antifungal therapy, one of the main issues is that histoplasmosis is probably often misdiagnosed for another disease, and therefore physicians do not ask for a fungal diagnosis and do not treat it with antifungals. Reported since the discovery of histoplasmosis, the main differential diagnosis of HIV-associated histoplasmosis is tuberculosis [12]. Malignancy-like clinical presentations also represent a challenging differential diagnosis requiring specific stainings and culture when performing a tumor biopsy in endemic or non-endemic areas. Regarding malignancy-like lesions of the mucous membrane caused by *H. capsulatum* gastrointestinal and oral involvements have been reported in non-HIV and in HIV-infected patients [13–17].

Here we report a rare case of oral HIV-associated histoplasmosis because it is important to reinforce awareness of physicians and dentists on fungal infections when facing a malignancy-like oral lesion.

2. Case

A 52 year-old man presented at the emergency department for fever and fatigue. He was a homeless man originating from Haïti and hab been living in French Guiana for over ten years. He was known for an advanced HIV infection diagnosed 7 years before when the patient presented with concomitant pulmonary tuberculosis and pneumocystosis. At the time of HIV infection diagnosis, the CD4 lymphocyte count and HIV viral load were at 57/mm3 and over 6 log10, respectively. The patient received six weeks of anti-tuberculosis therapy and cotrimoxazole for pneumocystosis before fleeing the hospital and interrupting medical follow up. Other past medical events were chronic obstructive pulmonary disease due to smoking, a negative hepatitis C serology, serological evidence of a past toxoplasmosis infection (IgM antibody negative and IgG antibody positive) and serological evidence of a resolved hepatitis B (HBs antigen negative, HBc antibody and HBs antibody positive).

Upon admission in the emergency department, the patient reported anorexia and a 15 kg weight loss over a period of a few months, and a recent dysphonia. There was no dyspnea. Fever was 38.5 °C, and there was a large burgeoning and necrotic ulceration of the base of the tongue and the anterior part of the soft palate pillars, with a whitish coating (Fig. 1). There were no lymphadenopathies, and the rest of the examination was without particularities.

Biologically, lactate deshydrogenase (LDH) was elevated at 210 IU/l, albumin concentration was 26.7 mg/l, ferritine was 482 mg/l, C-reactive Protein (CRP) was 45 mg/l, creatinine awast 49 µmol/l, and liver enzymes were normal. The hematological results showed platelets at 215,000/mm^3, hemoglobin at 9.3 g/dl, and white blood cells at 4 400/mm3. The CD4 lymphocyte count was 40/mm3 with a HIV viral load of 5.5 log10. The search for acid-fast bacilli was negative on 3 sputum samples (direct examination and culture) and in the blood cultures.

Radiologically, the chest Xray showed an interstitial syndrome suggestive of histoplasmosis with sequellae of the past tuberculosis (Fig. 2). Computed tomography showed an ulcerated lesion of the tongue and the oropharyngeal region (Fig. 3), right jugulo-carotidian lymphadenopathies, an aspect of pulmonary miliary, fibrotic sequelae associated with a localized bronchial dilatation of the right lung, and

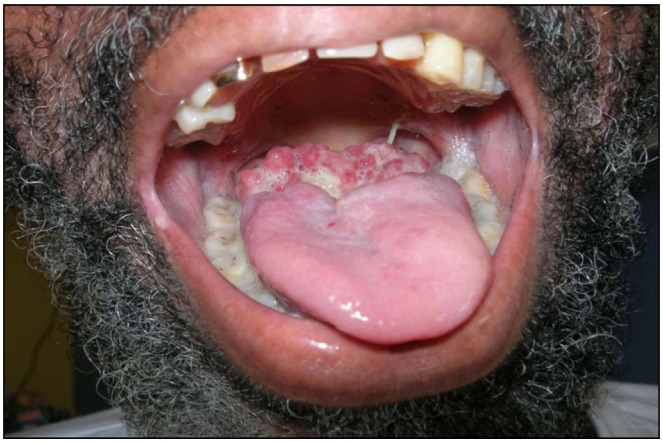

Fig. 1. Oral examination upon hospital admission.

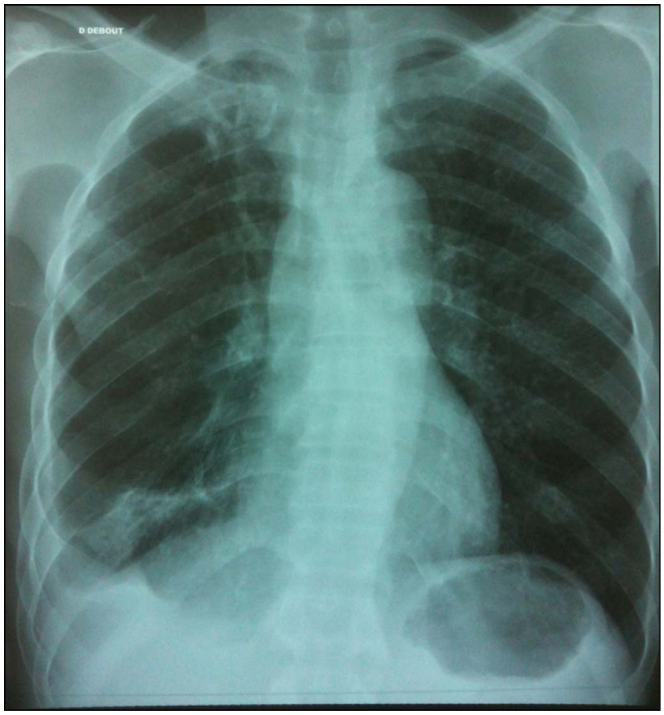

Fig. 2. Chest X-Ray upon hospital admission.

Fig. 3. Computed tomography of the pharyngeal region upon hospital admission (sagittal section).

Download English Version:

https://daneshyari.com/en/article/8484746

Download Persian Version:

https://daneshyari.com/article/8484746

Daneshyari.com