

## First case of invasive *Magnusiomyces capitatus* infection in Slovakia



Dominika Tanuskova<sup>a,\*</sup>, Julia Horakova<sup>a</sup>, Peter Svec<sup>a</sup>, Ivana Bodova<sup>a</sup>, Martina Lengerova<sup>b</sup>, Matej Bezdicek<sup>b</sup>, Miroslava Poczova<sup>c</sup>, Jozef Koppl<sup>d</sup>, Alexandra Kolenova<sup>a</sup>

<sup>a</sup> Department of Paediatric Haematology and Oncology, Comenius University Children's Hospital, Bratislava, Slovakia

<sup>b</sup> Department of Internal Medicine – Hematology and Oncology, University Hospital Brno, Brno, Czechia

<sup>c</sup> Department of Mycology, HPL Ltd. a Member of Medirex Group, Bratislava, Slovakia

<sup>d</sup> Department of Paediatric Anesthesiology, Comenius University Children's Hospital, Bratislava, Slovakia

### ARTICLE INFO

#### Keywords:

Blastoschizomyces  
Geotrichum  
Magnusiomyces  
Stem cell transplantation

### ABSTRACT

*Magnusiomyces capitatus* (previously known as *Geotrichum capitatum* or *Blastoschizomyces capitatus* or *Trichosporon capitatum*) is a rare cause of fungal infection in immunocompromised patients. Most of these cases (87%) have been reported from the Mediterranean region, as it is extremely rare to recognize it in other regions. Here we report a first case of disseminated *M. capitatus* infection in Slovakia. The patient – 19 year old woman with myelodysplastic syndrome was diagnosed with *M. capitatus* fungemia after allogeneic stem cell transplantation. The infection occurred despite antifungal prophylaxis with micafungin, which was *in vitro* sensitive to the yeast. The treatment according to minimal inhibitory concentrations (micafungin, voriconazole) and granulocyte transfusions were administered. *M. capitatus* was cleared out from the bloodstream. However, patient died of multiple organ failure. Autopsy showed multiple lesions in organs, but did not prove presence of yeast by histopathology. *M. capitatus* was confirmed by polymerase chain reaction from all tested organs: heart, brain, lungs, spleen, liver and kidneys. We present the post mortem pictures showing the yeast lesions in affected organs. 2012 Elsevier Ltd. All rights reserved.

### 1. Introduction

*Magnusiomyces capitatus* is a rare cause of fungal infection in immunocompromised patients, occurring almost exclusively in the Mediterranean region, with only a few case reports from outside this region. This paper presents the first case of disseminated *M. capitatus* infection in Slovakia. We present the post mortem pictures showing the lesions in affected organ, in which *M. capitatus* was confirmed by polymerase chain reaction (PCR).

### 2. Case

A 19-year old woman with refractory cytopenia type of myelodysplastic syndrome (RCC/MDS) was admitted to our unit for planned allogeneic stem cell transplantation. Multiresistant *Pseudomonas aeruginosa* from stool and rectum and *Candida glabrata* from vulva were found in routinely performed pretransplant swabs, however the patient had no signs of infection. Peripheral blood stem cell transplantation from a 9/10 HLA- matched unrelated donor was performed (D 0) following the conditioning consisting of Fludarabine (4 × 40 mg/m<sup>2</sup>) and Thiotepea (3 × 5 mg/kg). Anti-thymocyte globulin (3 × 15 mg/kg),

cyclosporine A and methotrexate (10 mg/m<sup>2</sup>) were used for T cell depletion and graft-versus-host disease (GvHD) prophylaxis. Micafungin (1 mg/kg/daily) was used for antifungal prophylaxis. On D – 2 the patient became febrile and on D + 3 a yeast - *M. capitatus* was identified in blood cultures from central venous catheter (CVC). This yeast was found in several consecutive blood cultures. From D + 8 multiresistant, yet sensitive to colimycine *P. aeruginosa* was identified in blood cultures from CVC and from peripheral blood as well (being colonized with the bacteria – the swab from rectum and stool). At this point the patient had suffered from agranulosis for 4 months for what we know. In-vitro susceptibility testing of *M. capitatus* showed sensitivity to azoles, amphotericin B and micafungin (Table 1) and combined micafungin (2 mg/kg) and voriconazole (1.day 6 mg/kg, then 4 mg/kg) treatment began. The sensitivity was valued according to CLSI breakpoints for *Candida spp.*, there are none specifically set for this pathogen. Lung high resolution computed tomography (HRCT) showed inflammatory infiltrates in the both lungs with fluidothorax. Treatment with granulocytes infusions began on D + 10. Patient's condition started to deteriorate, respiratory failure occurred and she was febrile despite the targeted antifungal and antibacterial treatment. On D + 12 the patient was transferred to paediatric intensive care unit (PICU) due to required

\* Corresponding author.

E-mail address: [donissima@gmail.com](mailto:donissima@gmail.com) (D. Tanuskova).

<http://dx.doi.org/10.1016/j.mmcr.2017.03.004>

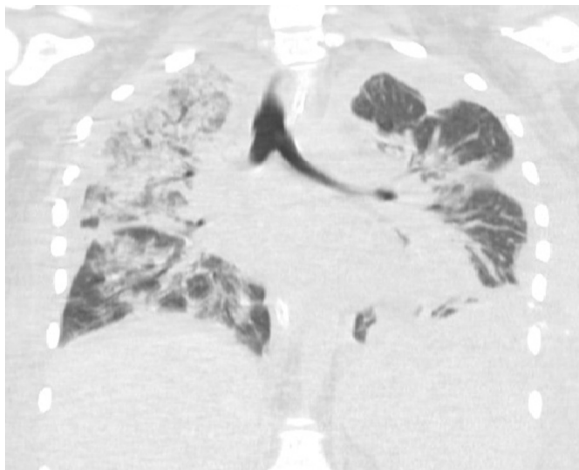
Received 18 January 2017; Received in revised form 22 March 2017; Accepted 28 March 2017

Available online 31 March 2017

2211-7539/ © 2017 The Author(s). Published by Elsevier B.V. on behalf of International Society for Human and Animal Mycology. This is an open access article under the CC BY-NC-ND license (<http://creativecommons.org/licenses/by-nc-nd/4.0/>).

**Table 1**  
Minimum inhibitory concentrations (MIC) of the *Magnusiomyces capitatus* isolate as reported by Department of mycology, HPL Ltd. a Member of Medirex Group, Bratislava, Slovakia Bratislava, Slovakia.

Antifungal agent	MIC (µg/mL)
Fluconazole	C 6.0
Itraconazole	C 0.125
Voriconazole	C 0.094
Posaconazole	C 0.75
Amphotericin	C 0.38
Caspofungin	R 32
Anidulafungin	R 32
Micafungin	C 0.003



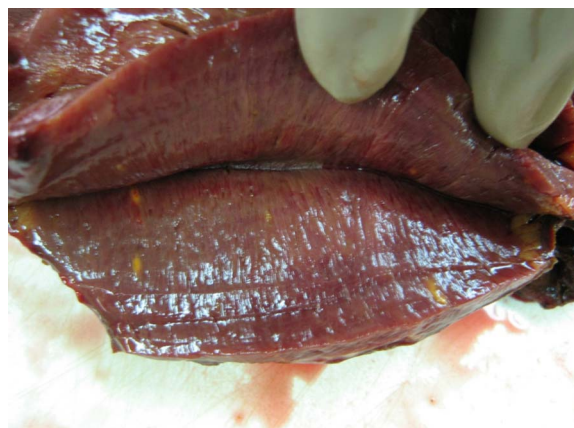**Picture 1.** Lungs CT scan with multiple areas of hypodensities.

mechanical ventilation (MV). The deteriorating condition continued with renal failure, and the patient received haemodialysis starting on D + 14. Leukocytes engraftment occurred on D + 17, with complete donor chimerism in peripheral blood. The molecular adsorbents recirculating system (MARS) was required for liver failure from D + 19. The first negative blood culture for *P. aeruginosa* was recorded on D + 18, for *M. capitatus* the first negative blood culture was found on D + 19. Nevertheless, *P. aeruginosa* was still found in swabs from rectum and throat and *M. capitatus* in the urine and in the swabs from nose and from tongue (D + 26). On D + 38 computed tomography of brain, lungs and abdomen showed multiple areas of hypodensity in following organs: brain, liver, spleen, kidneys, and lungs (Picture 1). These were the assumed infectious emboli of the yeast, however the unstable and critical condition of the patient made it impossible to perform biopsy. The patient suffered another complications – left thoracoscopic revision due to fluidothorax and haemothorax (D + 33), which was complicated with haemorrhagic shock after the thoracoscopy, left thoracotomy with haematoma evacuation and drainage (D + 40), diffuse bleeding from the gastrointestinal tract. Cultivations of pleural effusions (D + 33) and from bronchoalveolar lavage specimen (D + 53) were both tested negative for bacterial and mycotic agents as well. The patient died D + 71 of multiple organ failure. The autopsy showed multiple lesions in heart, brain, lungs, spleen, liver and kidneys (Picture 2, 3, 4, 5, 6, 7), but did not prove any mycotic infection in the morphological picture. Autopsy samples were tested with two different panfungal PCR methods [1,2].

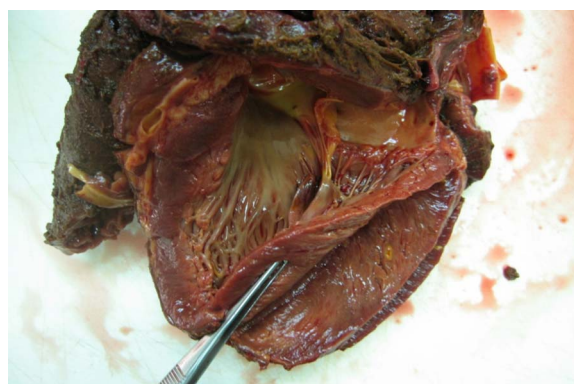Regarding the tissue samples neither of our methods was positive despite our expectations. Consequently, we designed a novel specific PCR (Table 2) for detection of *Saprochaete capitata* and *S. clavata* followed by species identification based on sequencing. After PCR products sequencing we confirmed *M. capitatus* (Anamorph *S. capitata*)



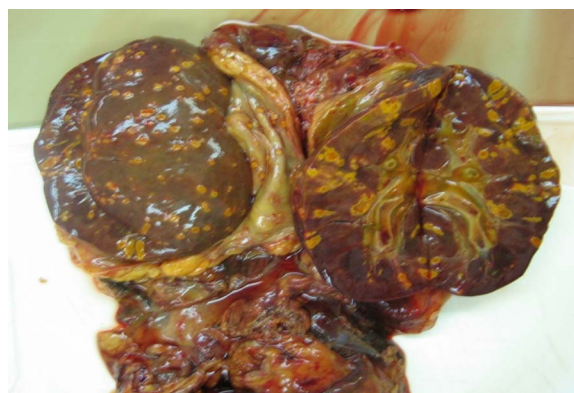
**Picture 2.** Lungs.



**Picture 3.** Heart.



**Picture 4.** Heart.



**Picture 5.** Kidneys.

Download English Version:

<https://daneshyari.com/en/article/8484838>

Download Persian Version:

<https://daneshyari.com/article/8484838>

[Daneshyari.com](https://daneshyari.com)