The Journal of Foot & Ankle Surgery 57 (2018) 509–513

Contents lists available at ScienceDirect

The Journal of Foot & Ankle Surgery

journal homepage: www.jfas.org

Anatomic Reconstruction Versus Traditional Rebalancing in Lesser Metatarsophalangeal Joint Reconstruction

Jeremy J. Cook, DPM, MPH, FACFAS [1,2], Lindsay J. Johnson, DPM, FACFAS [1,3,4], Emily A. Cook, DPM, MPH, FACFAS [1,5]

[1]*Clinical Instructor in Surgery, Harvard Medical School, Boston, MA*
[2]*Director of Research and Quality Assurance, Division of Podiatric Surgery, Department of Surgery, Mount Auburn Hospital, Cambridge, MA*
[3]*Chief, Division of Podiatric Surgery, Department of Surgery, Harvard Vanguard Medical Associates, an Affiliate of Atrius Health, Braintree, MA*
[4]*Assistant Director of Resident Training, Division of Podiatric Surgery, Department of Surgery, Mount Auburn Hospital, Cambridge, MA*
[5]*Director of Resident Training, Division of Podiatric Surgery, Department of Surgery, Mount Auburn Hospital, Cambridge, MA*

ARTICLE INFO

Level of Clinical Evidence: 3

Keywords:
collateral ligaments
hammer toe syndrome
metatarsophalangeal joint
plantar plate
toes

ABSTRACT

Traditional rebalancing techniques, such as capsulotomies and capsulorrhaphies, are commonly performed during complex hammertoe and lesser metatarsal osteotomy procedures involving metatarsophalangeal joint (MTPJ) contractures; however, floating toes, digital instability, and malalignment are concerns. We critically analyzed the outcomes after anatomic reconstruction of the plantar plate and collateral ligaments compared with those after traditional rebalancing techniques. A case-control study was conducted of 54 patients who had undergone surgical correction of lesser MTPJ imbalances due to complex hammertoe deformities (power 80%, type I error = 0.05). Cases were defined as consecutive patients treated with anatomic plantar plate and collateral ligament reconstruction. Controls had undergone traditional lesser MTPJ rebalancing and were matched to cases by age, gender, follow-up duration (minimum 12 months), and concomitant procedures of the same lesser ray. Multivariate logistic regression demonstrated that patients treated with anatomic reconstruction had greater digital stability (negative dorsal drawer and negative paper pull-out test findings) at final follow-up examination compared with the controls. American College of Foot and Ankle Surgeons (ACFAS) forefoot module scores were greater in the anatomic group in all domains ($p \leq .05$). Controls had greater postoperative radiographic MTPJ angles than the cases, with no differences detected between the 2 groups in visual analog scale scores or proximal interphalangeal joint angles. The importance of restoration of the plantar plate and collateral ligament integrity as a digital stabilizer is generally accepted but has not been well studied. We found that anatomic reconstruction yielded greater digital stability, greater ACFAS Forefoot module scores, and better radiographic MTPJ alignment than controls. Additional studies are warranted to assess the long-term viability of anatomic lesser MTPJ reconstruction.

© 2018 by the American College of Foot and Ankle Surgeons. All rights reserved.

An estimated 60 million people develop hammertoe deformities in the United States. Nearly 550,000 surgeries to correct this condition were performed in the United States alone in 2012 (1). Given that repairs of hammertoe and lesser metatarsophalangeal joint (MTPJ) deformities are common, it is important to improve our understanding of this joint and how to prevent complications. Traditional rebalancing techniques, such as capsulotomies and capsulorrhaphies, are commonly performed during complex hammertoe and lesser metatarsal osteotomy procedures involving MTPJ contractures. However, floating toes (Fig. 1), digital instability, and malalignment are concerns (2–4).

Financial Disclosure: This was an investigator-initiated study in which E.A. Cook and J.J. Cook applied for funding. This was not considered a grant, and we are both consultants for Smith & Nephew. The total amount provided in connection with our time for completing this study totaled $13,420; although we received this compensation, Smith & Nephew did not maintain rights to the data and did not have any input to the content or data analysis. We performed and interpreted our own data, and Smith & Nephew made no edits to the content of the report.

Conflict of Interest: J.J. Cook is a consultant to Smith & Nephew. E.A. Cook is a consultant to Smith & Nephew.

Address correspondence to: Emily A. Cook, DPM, MPH, FACFAS, Department of Surgery, Mount Auburn Hospital, 330 Mount Auburn Street, Cambridge, MA 02138.

E-mail address: ecook@mah.harvard.edu (E.A. Cook).

1067-2516/$ - see front matter © 2018 by the American College of Foot and Ankle Surgeons. All rights reserved.
https://doi.org/10.1053/j.jfas.2017.11.023

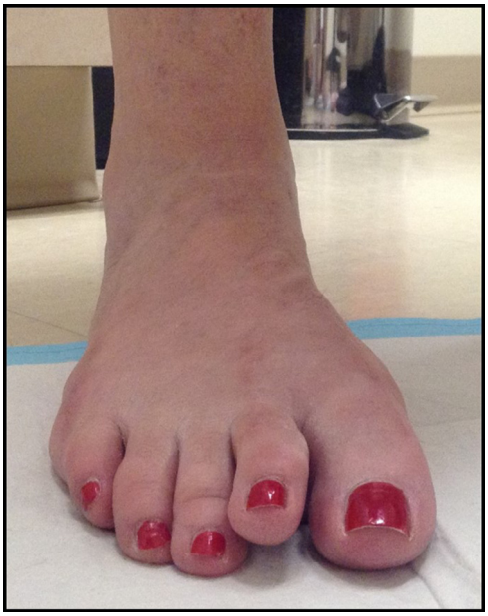

Fig. 1. Floating toe after lesser metatarsophalangeal joint traditional rebalancing techniques, including an extensor hood release, Weil osteotomy, and proximal interphalangeal joint arthrodesis.

Fig. 2. Example of a lesser metatarsophalangeal joint traditional rebalancing technique that included extensor hood release, plantar plate release with a McGlamry elevator, Weil osteotomies of the second and third metatarsals, proximal interphalangeal joint arthrodesis, and temporary Kirschner wire fixation that crossed the second metatarsophalangeal joint.

A recent increase in interest has occurred surrounding the role of the plantar plate in optimizing the outcomes after forefoot surgery (5–11). The plantar plate has been identified as an important static and dynamic stabilizer of the lesser MTPJs (12). A variety of risk factors have been identified that can lead to attenuation of the MTPJ soft tissues, contributing to pain, digital deformity, and poor function. Several techniques have been reported, ranging from the traditional plantar approach to modifications of a dorsal approach, both with and without an osteotomy (5–12).

Suero et al (13) demonstrated that resection of the plantar plate resulted in an ~20% increase in dorsal displacement of the digit. They further noted that when plantar plate failure occurred concomitantly with compromise of just 1 of the collateral ligaments, a threefold increase in instability was observed (13). Fleming and Camasta (14) authored an excellent review of lesser MTPJ pathoanatomy and pathomechanics. They posited that "the plantar plate along with the medial and lateral capsular ligaments (proper collateral ligaments and accessory collateral ligaments) creates an articular unit…" that work cooperatively to provide functional stability in multiple planes (14). Additional reports have supported the importance of the collateral ligaments in providing transverse plane stability and preventing medially or laterally drifting toes (15–19).

To the best of our knowledge, no studies have directly compared the effects of digital stability between patients undergoing and not undergoing anatomic MTPJ reconstruction. The purpose of the present study was to critically analyze the outcomes after MTPJ anatomic reconstruction of plantar plate and collateral ligaments versus traditional rebalancing techniques in patients who had undergone surgical correction for complex hammertoe deformities involving MTPJ contracture. We hypothesized that patients treated with the anatomic MTPJ reconstruction (cases) would have statistically significant ($p < .05$) improved digital stability outcome measures compared with the corresponding controls (traditional MTPJ rebalancing procedures). Our secondary aims were to compare the American College of Foot and Ankle Surgeons (ACFAS) forefoot module scores and visual analog scale (VAS) scores between the cases and controls.

Patients and Methods

A case-control study was conducted of consecutive adult patients who had undergone surgical correction of lesser MTPJ imbalances. These patients were from the surgical medical records from January 2013 to December 2014. The institutional review board approved the present study (protocol no. 045-2014). The cases were defined as consecutive patients who had undergone anatomic plantar plate and collateral ligament reconstruction. The control group was defined as patients who had undergone traditional lesser MTPJ rebalancing. The controls were propensity-matched 2:1 to the cases according to age, gender, follow-up duration (minimum 12 months), and concomitant procedures of the same lesser ray and digit.

The traditional lesser MTPJ rebalancing procedures included sequential MTPJ release with variable deformity-specific procedures until a negative push-up test result was achieved. The possible variable deformity-specific procedures included capsulotomy and capsulorrhaphy for transverse plane deformities, plantar plate releases using a McGlamry metatarsal elevator, extensor hood releases, proximal interphalangeal joint (PIPJ) arthrodeses, extensor tendon open Z-lengthening, skin-plasties, flexor tendon transfers, temporary MTPJ pinning, and metatarsal osteotomy (20,21) (Fig. 2).

For the cases, anatomic MTPJ reconstruction was performed through a dorsal approach in which the MTPJ collateral ligaments and plantar plate were detached from the proximal phalanx base, forming a cuff of tissue similar to that in a Broström procedure. This tissue cuff was plicated and anatomically reattached to the phalangeal base with controlled physiologic tension to rebalance and restore MTPJ function and alignment. Additional variable deformity-specific concomitant procedures in the anatomic repair group included PIPJ arthrodeses, extensor hood releases, extensor tendon open Z-lengthening, skin-plasties, and metatarsal osteotomy (Fig. 3).

Additional inclusion criteria were preoperative lesser MTPJ positive dorsal drawer test findings, adequate vascular status, age >18 years, and a minimum of 12 months of follow-up. The patients were excluded if they had a history of avascular necrosis or osteomyelitis in the surgical site area, had undergone revision or percutaneous MTPJ capsulotomy techniques, and those who had not undergone anatomic lesser MTPJ reconstruction of the plantar plate and collateral ligaments or traditional lesser MTPJ rebalancing techniques, as defined. The repair and reconstruction of lesser MTPJ pathology frequently involve a variety of concomitant procedures to address the influence of neighboring deformities. Therefore, the cases and controls who had undergone concomitant procedures involving joints and sites other than the lesser MTPJ of interest were not excluded but reported.

Download English Version:

https://daneshyari.com/en/article/8603022

Download Persian Version:

https://daneshyari.com/article/8603022

Daneshyari.com