



## Case Report

## Septic coxitis after an intramuscular injection in a young adult treated by two-steps total hip arthroplasty: a case report

Nicola Piolanti, Michele Giuntoli\*, Anna Maria Nucci, Enrico Bonicoli, Paolo Domenico Parchi, Michelangelo Scaglione

1st Orthopaedic Division, University of Pisa, Via Paradisa 2, 56100, Pisa, PI, Italy

## ARTICLE INFO

## Article history:

Received 11 March 2018

Accepted 2 April 2018

Available online 6 April 2018

## Keywords:

THA

Two-steps

Septic

Arthritis

Injection

Arthroplasty

## ABSTRACT

**Introduction:** Septic arthritis of the hip is a rare condition in adults and its treatment depends on symptoms duration: early onset of infection can be treated with open or arthroscopic debridement, while more aggressive surgery is required when articular damage takes place such as articular resection or total hip replacement (THA).

**Presentation of case:** We report a case of a 30 year old man affect by septic arthritis of the hip after an intramuscular injection of diclofenac successfully treated with a two-steps THA.

**Discussion:** In literature there aren't many cases of septic arthritis of the hip developed after intramuscular injections. Early onset of infection can be treated with an accurate articular debridement, while chronic conditions are traditionally treated by resection arthroplasty.

However resection arthroplasty gives to the patients a significant leg length discrepancy and, especially in young adults, a two-steps surgery with the implant of THA can lead to good results, as reported in recent case series published.

**Conclusion:** In our experience two-stage total hip arthroplasty proved to be a reliable solution for septic arthritis of the hip and may be used in patient with severe joint damage.

Furthermore we want underline importance of correct anamnesis to make quickly the right diagnosis and provide the right treatment of septic arthritis of the hip also in difficult clinical cases.

© 2018 The Authors. Published by Elsevier Ltd on behalf of Surgical Associates Ltd. This is an open access article under the CC BY-NC-ND license (<http://creativecommons.org/licenses/by-nc-nd/4.0/>).

## 1. Introduction

Primary septic arthritis of the hip is a rare condition in adult population, often related to patient's comorbidity. Several condition are involved in increased risk to develop septic coxitis in adults, as diabetes, rheumatoid arthritis, steroid therapy, alcoholism, chronic liver or kidney disease, cancer, malnutrition, and immune deficiencies [1].

To establish the right kind of treatment is important to determine symptoms duration: early onset of infection can be treated with open or arthroscopic debridement, while more aggressive surgery is required when articular damage takes place [2].

We report a case of a patient affected by septic arthritis of the hip after an intra-muscular injection treated successfully with a two-stage THA.

\* Corresponding author.

E-mail addresses: [nicpio@hotmail.it](mailto:nicpio@hotmail.it) (N. Piolanti), [michelegiuntoli87@gmail.com](mailto:michelegiuntoli87@gmail.com) (M. Giuntoli), [annamarianucci90@gmail.com](mailto:annamarianucci90@gmail.com) (A.M. Nucci), [enrico.bonicoli@gmail.com](mailto:enrico.bonicoli@gmail.com) (E. Bonicoli), [paolo.parchi@unipi.it](mailto:paolo.parchi@unipi.it) (P.D. Parchi), [michelangelo.scaglione@gmail.com](mailto:michelangelo.scaglione@gmail.com) (M. Scaglione).

## 2. Presentation of case

A 30 years old man presented for the first time at our institution on august 2016 with a painful hip during loading and during hip mobilization. He was also unable to walk or standing and to move the hip over a few degrees of R.O.M. (Range Of Motion).

The lower right limb presented externally rotated and fixed at 20° of flexion. Clinical examination revealed pain over the night and during the most of R.O.M.

The patient history revealed a cerebral meningioma surgically treated about four months before. After the surgery high levels of steroid therapy was done. On further questioning, the patient told us about an intramuscular diclofenac injection, into great gluteus to soothe pain, resulting in gluteus abscess and in systemic sepsis supported by *S. Aureus*. He reported that the infection has been successfully treated by systemic antibiotic therapy with symptoms complete resolution.

X-rays and TC examinations of right hip showed joint erosion and necrosis of the femoral head (Fig. 1).

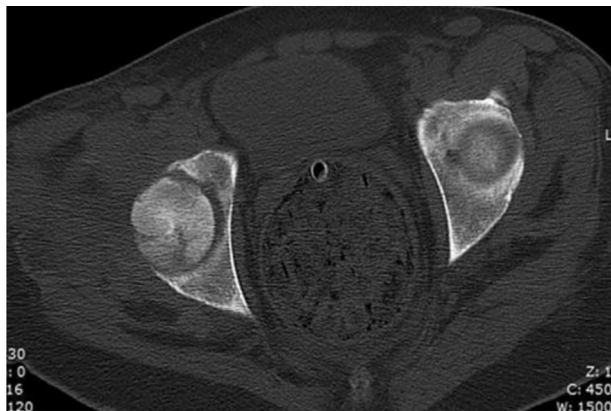

Fig. 1. TC of the right hip showing the necrosis of the femoral head.

During the stay the patient was high feverish (39 °C) and laboratory tests showed persistently high VES, PCR, PCT and leukocytes with neutrophilia.

A new TC examination was performed showing femoral head necrosis and joint spraying. So we decided to make a hip joint US-guided drainage that reveals the presence of a Meticilline resistant *S. Aureus* joint infection.

As first line of treatment a specific antibiotic therapy was set up and we performed an open surgical joint debridement.

After the articular debridement the lab indexes temporary decreased without complete resolution of pain.

For the recurrence of pain and fever an MRI evaluation was performed that reveal the presence of a right ileopsoas abscess and for that reason the patient underwent to another open surgical joint debridement with, in addition, an ileo-psoas abscess drainage.

For the persistence of the pain and of the disability related to the femoral head necrosis we decided to perform a two stage total hip replacement.

On October 2016 the patient underwent to the first surgery: all infected parts were removed (Fig. 2) and tissues samples were obtained for culture. After large wash with about 15 L of physiological saline solution, a preformed antibiotic-loaded hip spacer (Zimmer StageOne™ Select Hip Cement Spacer) was implanted. This kind of spacer consists of independent femoral and acetabular molds with interchangeable sizing options to create an articulating hip spacer accommodating various patient anatomies. Featuring a

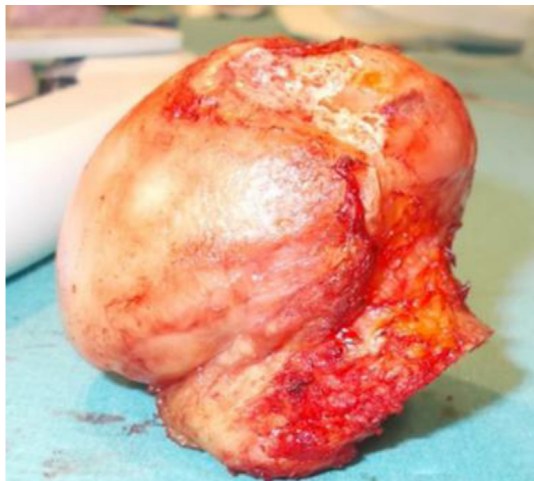


Fig. 2. Removed femoral head showing necrosis and joint damage.

reinforced stem for increased spacer strength and modular neck length options to adjust leg length and retain soft tissue tension.

The cement used was Biomet Refobacin Revision, pre-loaded with gentamicin and clindamycin by the manufacturer, developed for Zimmer StageOne spacer.

Postoperatively the patients received four months of a specific antibiotic therapy until the complete infection eradication was confirmed by the lab tests and by a scintigraphy with marked leucocytes.

Once the infection has been completely eradicated, on February 2017, the patient underwent to the second surgery in which the hip spacer was removed and, after large articular wash with physiological saline solution, a cement-less total hip prosthesis (Permedica Jump/Exacta) was implanted (Fig. 3).

All surgical procedures were performed by the same surgeons (NP, EB).

Partial weight bearing was allowed the day after surgery with crutches and therapist assistance, full weight bearing was allowed after 6 weeks from surgery. Systemic antibiotics were administered for 6 weeks after surgery.

Instrumental and clinic evaluation was performed before and after surgical debridement and spacer implantation, at spacer removal, after prosthesis implantation and afterward at 3 and 6 months postoperatively.

In all cases lab tests and X-rays of the hip (antero-posterior and lateral projections) were performed.

To evaluate pain a visual analogic scale (VAS) and numeric rating score (NRS) were administered each time at the patient. Regarding the VAS the values range from 0 to 100 mm, where 0 indicates no pain and 100 maximum pain, while regarding the NRS the values range from 0 to 10, where 0 indicates no pain and 10 maximum pain.

Clinical performance was evaluated using the Harris Hip Score (HHS) before surgery, after spacer implantation, after prosthesis implantation and afterward at each follow-up [10].

VAS pain score was 92 pre-operatively, 86 prior second time debridement, 80 prior spacer implantation, 30 prior spacer removal and 8 at the last follow-up 6 months after prosthesis implantation.

Similarly NRS score decreased from 10 pre-operatively to 9 prior second time debridement, to 7 prior spacer implantation, to 4 at spacer removal to 1 at 6 months follow-up after prosthesis implantation.

HHS was 15 before first time debridement, 15 before second time debridement, 62 at spacer removal, 75 after prosthesis implantation and 94 at the final follow-up 6 months after prosthesis implantation.

At last FU Patient was able to walking and weight-bearing without any supports and without pain.

No clinical or instrumental signs of infection were recorded at last follow-up and no signs of mobilization were noted after prosthesis implantation and at last follow-up.

### 3. Discussion

Primary septic arthritis of the hip is a relatively rare condition in healthy adults: usually it involves patient with several comorbidities [1].

Very rare are primary septic hip arthritis after an intramuscular injection [8,9]. We report one case, described by Papanikolaou et al. [8], of primary septic arthritis of the hip due to *Bacteroides fragilis*. In their case report the patients developed a pyomyositis of the right gluteus minimus muscle and an intramuscular abscess due to an intramuscular injection of diclofenac. The patient was successfully treated with articular debridement and specific systemic antibiotic therapy.

Download English Version:

<https://daneshyari.com/en/article/8604867>

Download Persian Version:

<https://daneshyari.com/article/8604867>

[Daneshyari.com](https://daneshyari.com)