



Research Paper

Case series of ante-grade biliary stenting: An option during bile duct exploration

Qaiser Jalal*, Amir Forouzanfar, Anand Bhatt, Ahmed Al-Mukhtar, James Gardner-Thorpe, Ali Waqar Majeed

HPB Unit Northern General Hospital, Sheffield Teaching Hospital Trust, Sheffield, UK

ARTICLE INFO

Article history:

Received 2 November 2017

Received in revised form

6 November 2017

Accepted 6 November 2017

Available online 22 November 2017

Keywords:

Choledocholithiasis

Ante-grade stenting

Choledochotomy

ABSTRACT

Background: Managing choledochotomy after bile duct clearance is an ongoing debate. T-tube insertion is not without complication and morbidity, requires significant post-operative care. Primary closure alone can result in a high pressure biliary system and bile leak. The placement of an ante-grade stent through the choledochotomy prior to primary closure is an option for ensuring biliary drainage after bile duct exploration. We reviewed our series of open bile duct explorations, where an ante-grade stent was placed when managing choledochotomy.

Methods: Patients who had ante-grade stent placement, all performed by same senior hepatobiliary surgeon, were identified retrospectively. Case note review was used to gather demographic, complication, length of stay, post-operative clinic visits and readmission data.

Results: 22 (M:F, 7:15) patients with a median age of 64 years (22–82). The indication for surgical stone clearance was failed ERCP in 20.2 patients were not suitable for ERCP. The median post-operative stay was 8 days (379) with the abdominal drain remaining for a median of 4 days (137). 16 (73%) patients had no complications. 4 (18%) had bile leaks, 5 (22%) wound infections, 1 (5%) cholangitis and 1 (5%) pancreatitis. All complications were Clavien-Dindo grade 3 or less.

Conclusion: In situations where primary CBD closure is not safe due to concern over high pressure in the biliary tree the placement of ante-grade stent may be preferred to T-tube placement.

© 2017 The Authors. Published by Elsevier Ltd on behalf of Surgical Associates Ltd. This is an open access article under the CC BY-NC-ND license (<http://creativecommons.org/licenses/by-nc-nd/4.0/>).

1. Introduction

The prevalence of common bile duct stones (CBD) varies from 10 to 20% in patients with symptomatic gallstones [1,2]. Majority of these can be managed with ERCP (Endoscopic Retrograde Cholangiopancreatography) or surgical exploration with common bile duct clearance. Surgical exploration can be through laparoscopic or open an approach depending on available expertise and facilities.

The main indications for surgically exploring the biliary tree are: failed ERCP, deranged anatomy, difficult ampullary access, impacted stones and multiple large stones.

Laparoscopic cholecystectomy and common bile duct clearance as a single stage procedure has shown advantages [4]. There is, however, a significant subset of patients who require open common bile duct exploration. The main indications for an open procedure include previous surgery with dense adhesions, aberrant biliary

ductal anatomy, impacted stones or large bile duct stones and need for conversion from laparoscopic to open surgery.

When performing laparoscopic or open clearance of the biliary tree managing the choledochotomy after bile duct clearance is an ongoing debate. The two prevalent ways of CBD closure after exploration and clearance are: primary closure or closure over T-tube with each having its demerits [9,10]. Primary closure alone can result in a high pressure biliary system and bile leak. Complications associated with T-tube insertion are: bile leak, T-tube displacement, T-tube entrapment, nutritional and electrolyte disturbance, cholangitis, wound infection, tube site infection, recurrent stones [11], and patient inconvenience associated with prolonged surgical drains [5].

More recently there has been a move away from the placement of a T-tube, a recent Cochrane review failed to show a significant difference in morbidity and mortality associated with primary closure compared to T-tube closure [6].

Postoperative bile leaks can have significant consequences for patients where primary closure has been performed, including biliary peritonitis, sepsis, prolonged hospital stay, prolonged period with a drain. This coupled with situations where primary

* Corresponding author. Hepato-Pancreatobiliary Surgery Unit, Northern General Hospital, Sheffield, S5 7AU, UK.

E-mail address: Qaiser.jalal@sth.nhs.uk (Q. Jalal).

closure is deemed not safe due to concerns over a high pressure biliary tree is often the situation where most surgeons would use a T-tube. A third option in these patients is the placement of an ante-grade stent through the choledochotomy prior to primary closure.

Ante-grade stenting has been performed in our unit in limited situations where there was a desire to avoid T-tube placement but concern over primary closure of choledochotomy in a high pressure biliary tree, risking a bile leak.

We analyzed our data retrospectively over a 5-year period (2010–2015) to assess morbidity and mortality associated with open CBD exploration with the placement of an ante-grade stent prior to closure of choledochotomy in patients who had failed ERCP and were not suited for laparoscopic procedure.

2. Methods

This study is a single center (Case series) retrospective review of patients that underwent an open CBD exploration and clearance with the subsequent placement of an ante-grade stent prior to primary closure of their choledochotomy.

Northern General Hospital is the regional tertiary care teaching unit for Hepatobiliary surgery in South Yorkshire. All procedures were performed by single surgeon who has more than 20 years experience of dealing with complex benign and malignant biliary surgery. All patients in our unit have preoperative optimization and post-operative critical care if required. A search was carried out of our electronic theater record (ORMIS) data base to identify all patients who had an ante-grade stent placed. Using this list generated by ORMIS, which also held the patient's electronic operation note, a detailed look at the patient's records was performed. Further data sources included Lorenzo, EDMS and the ICE system (our unit's electronic results system). The data captured included patient demographics, length of stay, complications, readmission rates, outpatient follow up and subsequent progress. Data acquisition and processing was in line with PROCESS criteria [21]. Project was registered with NGH audit department (Project reference: 8157).

2.1. Surgical technique

A standard cholecystectomy performed through a right sub-total incision, the anatomy of Calot's triangle defined and common bile duct identified after securing cystic artery. Longitudinal

choledochotomy was performed between stay sutures (4/0 PDS) and bile sent for culture in all patients. Choledochoscopy was performed in all patients to confirm presence of stones followed by duct clearance using Dormia basket, Endo grasper or Fogarty Catheter. Duct clearance was confirmed by completion choledochoscopy and size 7FR double pigtail stent was deployed under vision, over a guide wire placed in duodenum via choledochoscope.

After successful placement of stent, closure of CBD was with 4/0 PDS interrupted sutures. Copious saline wash was performed as a routine practice and all patients had a surgical drain placed in Morrison's pouch at the end of procedure.

2.2. Follow up

Regular post-operative blood tests were performed and drain output measured; the amount and contents of surgical drain dictated their removal. Post operatively patients were followed up in outpatients and regular liver function tests performed to monitor appropriateness of drainage. Endoscopic stent removal performed 8–12 weeks postoperative.

3. Results

Between 2010 and 2015 study period 22 patients were identified that had an open cholecystectomy and CBD exploration. All patients had failed attempted ERCP and common bile duct clearance. All operations were performed by the same consultant. And open procedure was carried out due to previous laparotomies, adhesions, and or difficult biliary anatomy.

Of the 22 patients 7 were female and 15 males with a median age of 64 years (22–82 range). The median post-operative stay was 8 days (3–79). One patient had a 79 days stay due to a subsequent hip fracture as an inpatient which requiring surgery. One patient had to be taken back to theater for open washout because of stent migration and biliary peritonitis resulting in a 20 days hospital stay. The Individual lengths of stay for each patient can be reviewed in Fig. 1. Abdominal drains remained in for a median of 4 days (range 1–27), the vast majority were removed by five days, Fig. 2.

16 (73%) patients had no complications, 4 (18%) had bile leaks, 5 (22%) wound infections, 1 (5%) cholangitis and 1 (5%) pancreatitis. All complications were Clavien-Dindo [22] grade 3 or less, Figs. 3 and 4. 4 (18%) patients required readmission, one for pancreatitis,

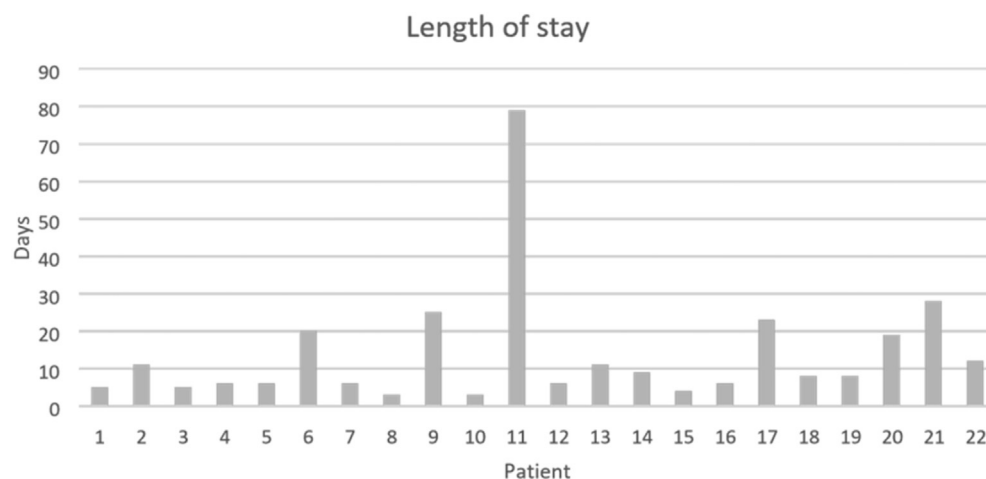


Fig. 1. Individual lengths of stay of the patients in the series the median stay being 8 days (3–79).

Download English Version:

<https://daneshyari.com/en/article/8604884>

Download Persian Version:

<https://daneshyari.com/article/8604884>

[Daneshyari.com](https://daneshyari.com)