

Catheter ablation of the slow pathway as a treatment for severe sinus node dysfunction in a patient with incessant atrioventricular nodal reentry tachycardia



Gilad Margolis, MD, Yoav Michowitz, MD, Aharon Glick, MD, Bernard Belhassen, MD

From the Department of Cardiology, Tel Aviv Sourasky Medical Center, Sackler Faculty of Medicine, Tel Aviv University, Tel Aviv, Israel.

Introduction

Radiofrequency ablation (RFA) of slow/fast atrioventricular nodal reentry tachycardia (AVNRT) is considered to be an effective and safe procedure associated with rare complications, the most disturbing being the occurrence of atrioventricular (AV) block.¹ A few electrophysiological disorders have been reported after AVNRT ablation: inappropriate sinus tachycardia after either fast pathway or slow pathway (SP) ablation² and marked shortening of the antegrade fast pathway refractoriness after SP ablation.^{3,4}

Herein we describe an unusual case of abolition of severe sinus node dysfunction after successful SP ablation in a patient with incessant AVNRT.

Case report

An 85-year-old woman with a 2-year history of recurrent paroxysmal supraventricular tachycardia (PSVT) was referred to the emergency department after another episode of PSVT. She was recommended to undergo RFA in the past, but she refused. Her medical history included hypertension, hyperlipidemia, bronchial asthma, and ischemic heart disease. Previous baseline electrocardiograms were normal with sinus rates above 60 beats/min. A recent echocardiographic examination showed normal left ventricular function with nonsignificant valvular disease. Her daily medications before hospitalization included ramipril 5 mg, atorvastatin 40 mg, clopidogrel 75 mg, lecanidipine 10 mg, and bisoprolol 2.5 mg (the last medication was taken 6 hours before hospitalization). At patient admission, a narrow complex supraventricular tachycardia at a rate of 150 beats/min presumably due to AVNRT was documented. The patient was given 6 mg adenosine intravenously (Supplemental Figure 1), which promptly terminated the tachycardia and

was followed by a sinus pause of 6.4 seconds, 4 AV junctional escape beats, and long RP tachycardia (150–170 beats/min) later proved to be due to atrial tachycardia (AT). The episodes of AT were always short-lasting (a few seconds) and repetitive, followed by marked sinus pauses lasting up to 6 seconds. Occasionally the AT degenerated into long-lasting episodes of rapid (160 beats/min) and apparently typical slow/fast AVNRT. The episodes of AVNRT during hospitalization were also self-terminating, lasting usually 15–30 seconds and invariably followed by sinus pauses as described above. Because of satisfactory patient's clinical and hemodynamic status during brady-tachycardia episodes, emergency implantation of a temporary pacemaker was not considered mandatory and the patient was transferred to the intensive cardiac care unit for monitoring before implantation of a permanent pacemaker. During the following 4-hour waiting period until patient's admission in the catheterization laboratory, well-tolerated incessant episodes of brady-tachycardia were documented including sinus pauses of 2.5–8.6 seconds. In the electrophysiology (EP) laboratory, it was decided first to ablate the arrhythmia before implanting the permanent pacemaker. A diagnostic EP study was performed under conscious sedation, which actually confirmed that the mechanism of incessant PSVT was due to slow/fast AVNRT. Prolonged posttachycardia sinus pauses ranging from 1.7 to 5.9 seconds were repeatedly observed spontaneously (Figure 1) as well as after termination of incessant AVNRT with rapid atrial pacing. Because of the impossibility to achieve stable sinus rhythm for guiding SP ablation, SP ablation was performed during AVNRT on the basis of anatomical considerations.

During the delivery of the third radiofrequency pulse at P2 area, the tachycardia terminated because of antegrade SP block and was followed by a sinus pause of 3.6 seconds. During the next 45 minutes, however, all subsequent sinus pauses recorded after spontaneous short-lasting AT (Figure 2) or bursts of atrial pacing at cycle lengths of 320–440 ms (Figure 3) ranged from 0.9 to 1.4 seconds. Stable sinus rhythm at ~60 beats/min was observed, and it became impossible to reinduce AVNRT or even echo beats despite

KEYWORDS Ablation; Slow pathway; Sinus node dysfunction; Atrioventricular nodal reentry tachycardia; Brady-tachycardia syndrome (Heart Rhythm Case Reports 2018;4:113–116)

Address reprint requests and correspondence: Dr Bernard Belhassen, Department of Cardiology, Tel-Aviv Sourasky Medical Center, Weizmann St 6, Tel-Aviv 64239, Israel. E-mail address: bbhass@tasmc.health.gov.il.

KEY TEACHING POINTS

- Sinus node function can be markedly improved after slow pathway (SP) ablation. The mechanism of this phenomenon is currently not fully understood.
- In patients presenting with tachy-bradycardia syndrome and atrioventricular nodal reentry tachycardia (AVNRT), the effects of SP ablation should be assessed before permanent pacemaker implantation.
- Whether SP ablation could improve sinus node function in patients without AVNRT should be assessed in future studies.

multiple pacing attempts (the effects of isoproterenol on induction were not assessed). The only spontaneous arrhythmias observed during this 30-minute period consisted of short-lasting AT (3–8 beats) (Figure 2).

Owing to this unexpected acute marked improvement of sinus node function after successful SP ablation, we decided to postpone the implantation of the permanent pacemaker at this stage and to closely follow up the patient. During 24-hour Holter monitoring performed the day after the procedure, the

average heart rate was 62 beats/min with only mild ectopic atrial activity and no abnormal sinus pauses. The patient was discharged home with the same medications as used before hospitalization, except for bisoprolol.

At follow-up 3 months after the ablation procedure, the patient has remained asymptomatic. Repeat Holter showed an average sinus rate of 74 beats/min (minimal rate 60 beats/min) without significant arrhythmias or sinus pauses.

Discussion

In this case report, we describe a patient with incessant AVNRT and severe brady-tachycardia syndrome in whom sinus node function markedly improved immediately after successful SP ablation. This allowed us to postpone and subsequently avoid pacemaker implantation that apparently seemed initially ineluctable.

The exact mechanism of improvement of sinus node dysfunction after SP ablation is not fully understood. Nevertheless, an association of sinus node dysfunction and AVNRT is well known, especially in older patients.⁵ In previous reports, patients with sinus node dysfunction and AVNRT at presentation were treated with a permanent pacemaker.^{6–8} Bae et al⁸ reported a patient who underwent an EP study for suspected sinus node dysfunction and in whom AVNRT was unexpectedly induced. After successful SP ablation the sinus node recovery time was unchanged and

Before ablation of slow pathway

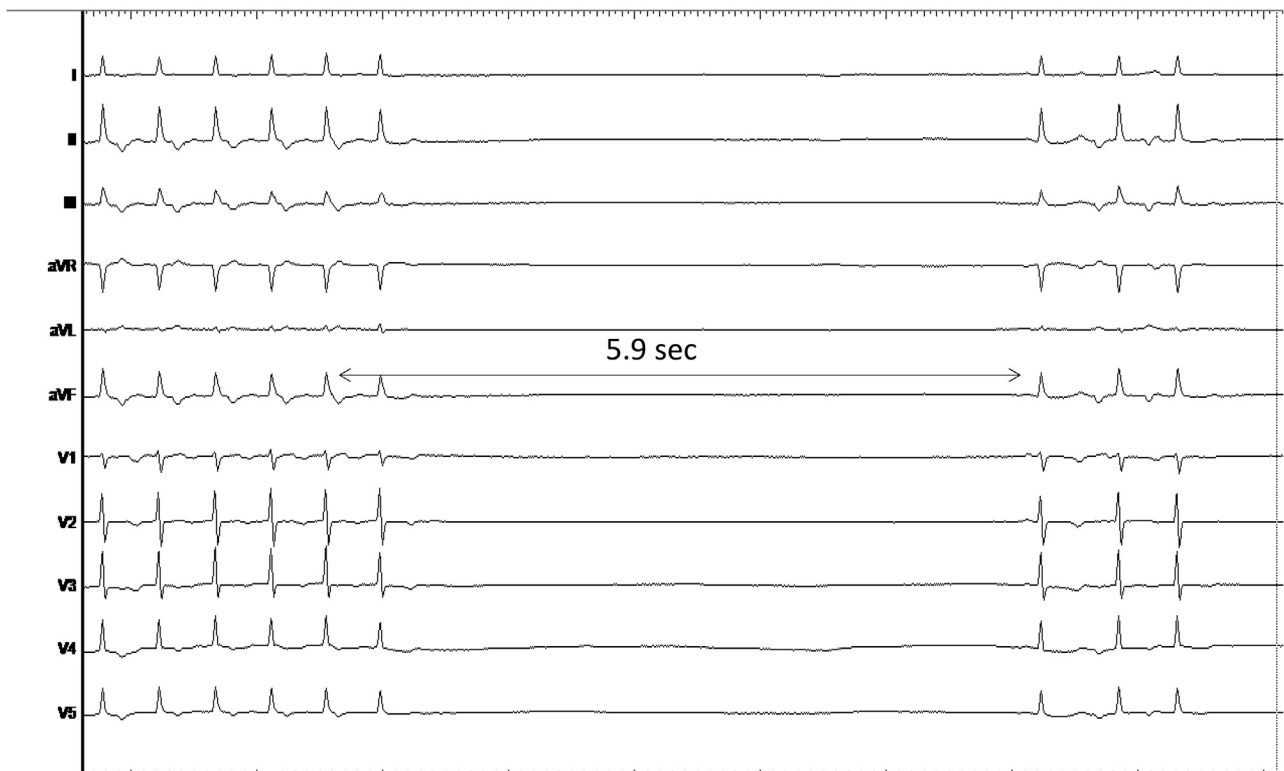


Figure 1 Longest posttachycardia sinus pause (5.9 seconds) recorded in the electrophysiology laboratory a few minutes before SP ablation. Note that the tachycardia preceding the sinus pause is an atrial tachycardia associated with long P-R intervals due to antegrade SP conduction. SP = slow pathway.

Download English Version:

<https://daneshyari.com/en/article/8660508>

Download Persian Version:

<https://daneshyari.com/article/8660508>

[Daneshyari.com](https://daneshyari.com)