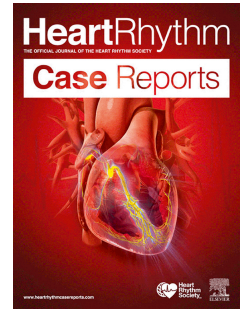


# Accepted Manuscript

A rare case of acute myocardial infarction during extraction of a septally placed implantable cardioverter-defibrillator lead

Eric Wierda, MD, LLM, Astrid A. Hendriks, MD, Giovanni Amoroso, MD, PhD, Daniel Mol, MD, PhD, Dirk J. van Doorn, Muchtiar Khan, MD



PII: S2214-0271(17)30190-2

DOI: [10.1016/j.hrcre.2017.11.001](https://doi.org/10.1016/j.hrcre.2017.11.001)

Reference: HRCR 455

To appear in: *HeartRhythm Case Reports*

Received Date: 16 February 2017

Revised Date: 7 October 2017

Accepted Date: 2 November 2017

Please cite this article as: Wierda E, Hendriks AA, Amoroso G, Mol D, van Doorn DJ, Khan M, A rare case of acute myocardial infarction during extraction of a septally placed implantable cardioverter-defibrillator lead, *HeartRhythm Case Reports* (2017), doi: 10.1016/j.hrcre.2017.11.001.

This is a PDF file of an unedited manuscript that has been accepted for publication. As a service to our customers we are providing this early version of the manuscript. The manuscript will undergo copyediting, typesetting, and review of the resulting proof before it is published in its final form. Please note that during the production process errors may be discovered which could affect the content, and all legal disclaimers that apply to the journal pertain.

1 **A rare case of acute myocardial infarction during extraction of a septally placed**  
2 **implantable cardioverter-defibrillator lead**

3

4

5 Eric Wierda<sup>1</sup>, Astrid A. Hendriks<sup>2</sup>, Giovanni Amoroso<sup>3</sup>, Daniel Mol<sup>4</sup>, Dirk J. van  
6 Doorn<sup>5</sup>, Muchtiar Khan<sup>6</sup>

7

8 <sup>1</sup>MD, LLM, Department of cardiology, Academic Medical Center, Amsterdam

9 <sup>2</sup>MD, Department of cardiology, Onze Lieve Vrouwe Gasthuis, Amsterdam

10 <sup>3</sup>MD, PhD, Department of cardiology, Onze Lieve Vrouwe Gasthuis, Amsterdam

11 <sup>4</sup>Department of cardiology, Onze Lieve Vrouwe Gasthuis, Amsterdam

12 <sup>5</sup>MD, PhD, Department of cardiology, Spaarne Gasthuis, Hoofddorp

13 <sup>6</sup>MD, Department of cardiology, Onze Lieve Vrouwe Gasthuis, Amsterdam

14

15

16 **Key words:** ICD, shock lead, acute myocardial infarction, perforation, coro-  
17 nary artery, left anterior descending coronary artery

18 **Word count:** Full text: 1.150 (2.500 accepted)

19 **Disclosures:** no disclosures

20 **Correspondence:** E. Wierda, MD, LLM

21 Department of Cardiology, Academic Medical Center,

22 Amsterdam

23 Meibergdreef 9 Amsterdam, the Netherlands

24 Phone: +31 6 1607 8145

25 Email address: [e.wierda@amc.uva.nl](mailto:e.wierda@amc.uva.nl)

26

Download English Version:

<https://daneshyari.com/en/article/8660512>

Download Persian Version:

<https://daneshyari.com/article/8660512>

[Daneshyari.com](https://daneshyari.com)