

Clinical Paper
 Craniofacial Anomalies

Precise osteotomies for mandibular distraction in infants with Robin sequence using virtual surgical planning

C. M. Resnick^{1,2}

¹Harvard School of Dental Medicine and Harvard Medical School, Boston, Massachusetts, USA; ²Department of Plastic and Oral Surgery, Boston Children's Hospital, Boston, Massachusetts, USA

C.M. Resnick: Precise osteotomies for mandibular distraction in infants with Robin sequence using virtual surgical planning. Int. J. Oral Maxillofac. Surg. 2017; xxx: xxx–xxx. © 2017 The Author(s). Published by Elsevier Ltd on behalf of International Association of Oral and Maxillofacial Surgeons. This is an open access article under the CC BY-NC-ND license (<http://creativecommons.org/licenses/by-nc-nd/4.0/>).

Abstract. Mandibular distraction osteogenesis (MDO) has become the first-line operation in many centers for the management of obstructive sleep apnea (OSA) in infants with (Pierre) Robin sequence (RS) not relieved by non-surgical approaches. Preoperative virtual surgical planning (VSP) may improve precision and decrease complications for this operation. This article reports a retrospective study of RS infants who underwent MDO for OSA using preoperative VSP and three-dimensionally printed cutting guides performed by one surgeon. Seventeen subjects who had MDO at a mean age of 87 ± 96 days were included. Maxillofacial computed tomography scans were obtained 15 ± 7 days prior to MDO. Osteotomy designs included linear ($n = 4$, 23.5%), inverted-L ($n = 11$, 64.7%), and multi-angular ($n = 2$, 11.8%). Cutting guides were used successfully and osteotomies were created as planned in all cases. Devices were removed 67 ± 15.6 days after placement. Bone formation in the distraction gap was seen in all cases at device removal. All patients had successful airway outcomes. There were no major and four minor complications during the follow-up period of 458 ± 267 days. In conclusion, MDO is a successful procedure for the management of OSA associated with RS in infants, and VSP facilitates its precise design and execution.

Key words: Robin; Pierre Robin sequence; mandibular distraction; virtual surgical planning.

Accepted for publication

Mandibular distraction osteogenesis (MDO) has become the first-line operation in many centers for infants with airway obstruction associated with (Pierre) Robin sequence (RS) who have failed non-invasive management¹. This procedure boasts high rates for successful resolution of obstructive sleep apnea (OSA) and avoid-

ance of tracheostomy^{2–12}. Long-term complications associated with the position of the osteotomies, such as injury to developing teeth and the inferior alveolar nerve, however, are common^{1,13–15}.

Preoperative virtual surgical planning (VSP) and the fabrication of three-dimensionally (3D) printed splints and/or cutting

guides for intraoperative use have been shown to improve outcomes and decrease operative times and costs in other areas of maxillofacial surgery^{16–19}. For neonatal MDO, VSP has been reported to aid in device selection and placement, facilitate vector management, and simplify the operation²⁰. Planning may also improve

precision and decrease complications. However, only single case reports of VSP and 3D printing for MDO in infants with RS currently exist in the literature.

The purpose of this study was to present a series of infants with RS who underwent MDO using preoperative VSP and 3D printed cutting guides. The specific aims were to (1) document the protocol used at Boston Children's Hospital for planning and execution of MDO in infants with RS using VSP, (2) evaluate osteotomy designs used to minimize damage to vital structures, and (3) present intraoperative findings and airway outcomes.

Materials and methods

Study design and subjects

This study analyzed a retrospective case series of infants at Boston Children's Hospital with OSA associated with RS who presented from February 2014 to December 2016. Inclusion criteria were the following: (1) a clinical diagnosis of RS made by a member of the Craniofacial Center, including micrognathia, glossoposis, and airway obstruction; (2) OSA that could not be completely treated by non-operative approaches and/or intubation with inability to extubate; (3) use of MDO by one surgeon (C.M.R.); (4) use of preoperative 3D virtual surgical planning and 3D printing of cutting guides. Subjects were excluded if they did not have pre-surgical VSP or if the virtual plan was not utilized in the operating room. This study was approved by the Institutional Review Board of the Center for Applied Clinical Investigation at Boston Children's Hospital.

Variables

Study variables included gestational age, birth weight, sex, syndromic diagnosis, age at presentation to Boston Children's Hospital, age at MDO, dates of preoperative maxillofacial computed tomography scan (CT), use of intubation for preoperative CT, need for repeat CT due to motion artifact, dates of pre- and postoperative polysomnograms (PSGs), dates of VSP Web session, intraoperative findings, overall severity score of OSA from the PSG as scored by the reading sleep medicine physician based on a compilation of all measured parameters (none = 0, minor = 1, minor-moderate = 2, moderate = 3, moderate-severe = 4, severe = 5)²¹, type of osteotomy used for MDO, need for additional airway inter-

vention after MDO, and surgical complications during the follow-up period.

Perioperative management

All patients were managed pre- and post-operatively in the neonatal intensive care unit. Prior to MDO, all non-intubated patients failed non-operative airway management including positioning maneuvers, insertion of a nasopharyngeal tube, and/or use of continuous positive airway pressure therapy. Direct laryngoscopy and bronchoscopy were performed prior to MDO in all non-intubated patients to rule out laryngomalacia, tracheomalacia, and subglottic stenosis as contributors to airway obstruction. Non-intubated patients had a pre-MDO PSG to confirm and characterize the OSA and a postoperative PSG at the end of active distraction prior to the removal of the activation arms. All PSGs were performed at the Boston Children's Hospital Sleep Center and were read by a pediatric sleep medicine physician.

Virtual surgical planning

The maxillofacial CT for each patient was uploaded to a third-party vendor for virtual surgical planning (3D Systems, Inc., Gold-

en, CO, USA) and a Web session was scheduled between the surgeon and a biomedical engineer using GoToMeeting (Citrix, Inc., Santa Clara, CA, USA). Prior to the Web session, the biomedical engineer segmented the CT volumes into relevant anatomical units to highlight structures such as developing teeth and the inferior alveolar nerve and to facilitate virtual surgical movement.

During the Web session, bilateral virtual osteotomies were drawn by the biomedical engineer based on input from the surgeon. These osteotomy positions and configurations were customized for each patient to: (1) minimize or avoid damage to developing dental structures, (2) avoid binding of the mobilized distal segment against the proximal segment during distraction, (3) avoid bringing the coronoid process forward with the distal segment, as this could lead to impingement with the zygomatic arch during distraction, (4) provide sufficient bone in each segment for device fixation, (5) achieve the desired vector for distraction, and (6) match the distraction vector between sides²². Common osteotomy designs included linear oblique, inverted-L, and multi-angular (Fig. 1). After completion of the virtual osteotomies, a digital version of the device

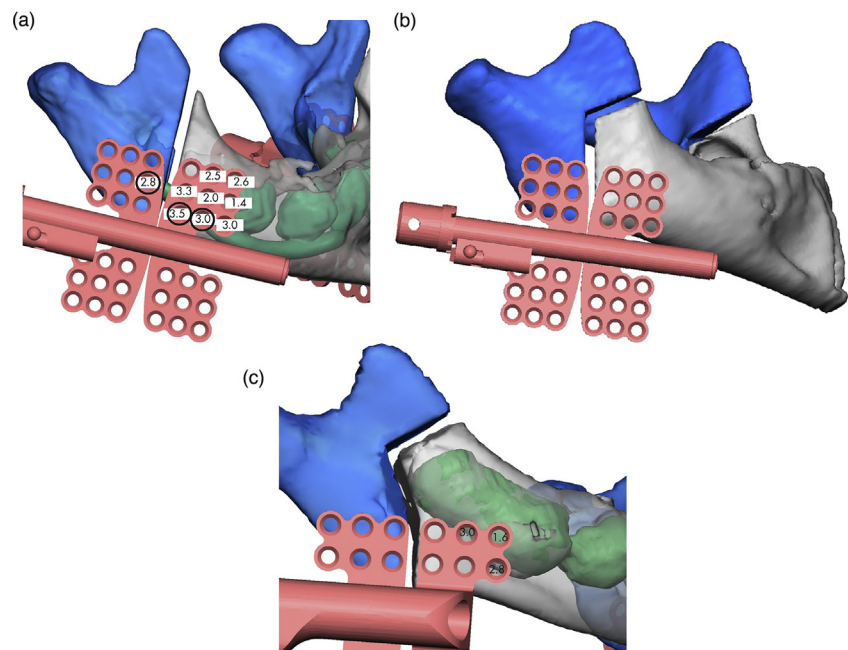


Fig. 1. Osteotomy designs for mandibular distraction. (A) A linear oblique osteotomy avoids the most posterior developing tooth (grey shadow) and overlaps the inferior alveolar nerve. Numbers indicate bone thickness from the buccal cortex to either the inferior alveolar nerve or a developing dental structure (green and grey). The screw holes outlined in black are those that are indexed in the cutting guide. (B) An inverted-L osteotomy is proximal to dental structures and ends anterior to the coronoid process. (C) A multi-angular osteotomy is necessary to avoid forming teeth (green and grey shadows) and remain anterior to the coronoid process in this patient.

Download English Version:

<https://daneshyari.com/en/article/8697902>

Download Persian Version:

<https://daneshyari.com/article/8697902>

[Daneshyari.com](https://daneshyari.com)