



ELSEVIER

Contents lists available at [ScienceDirect](#)

Oral and Maxillofacial Surgery Cases

journal homepage: www.oralandmaxillofacialsurgerycases.com

Giant tongue lipoma

Yehya E.K. Gamie*, Fazilet Bekiroglu, Simon N. Rogers

Oral and Maxillofacial Surgery, Regional Maxillofacial Unit, University Hospital Aintree, Longmoor Ln, Liverpool L9 7AL, UK



ARTICLE INFO

Article history:

Received 19 August 2017

Accepted 7 April 2018

Available online 9 April 2018

Keywords:

Lipoma

Tongue

Diagnosis

Histopathology

Treatment

ABSTRACT

Lipomas are the most common soft tissue mesenchymal neoplasms are uncommon in the oral and maxillofacial region. Oral lipomas usually exhibit slow asymptomatic growth and are less than 20 mm at their largest diameter. A 71-year-old man was referred to our regional oral and maxillofacial department by a dentist after noticing an asymptomatic tongue swelling. Examination and further radiographic and histological investigations revealed a large tongue lipoma which had been present for over three years. Initially it was decided to keep this benign lesion under review. However its relatively rapid growth over the next six months started to affect his speech, eating and airway and was subsequently removed surgically under general anaesthetic. This unusual case report documents the presentation, diagnostic considerations and treatment of this lipoma. It also highlights the important role clinicians have in detecting and investigating or referring any abnormal pathology.

© 2018 Published by Elsevier Inc. This is an open access article under the CC BY-NC-ND license (<http://creativecommons.org/licenses/by-nc-nd/4.0/>).

1. Initial presentation

A 71-year-old man was referred urgently by a dentist to our regional oral and maxillofacial department after examining him for the first time. The letter described a large left sided tongue swelling approximately five times the size of the right. Although not troublesome the patient complained it occasionally slurred his speech and was catching on his teeth while eating. The patient was aware it had been present and growing in size for over three years. Medically he had hypertension that was controlled by Amlodipine but was otherwise fit and well with no known allergies. On examination a large, firm, non-pulsatile sub mucosal mass was evident (Fig. 1). His dentition was well maintained and he had no sensory defects, weight loss, swallowing difficulties or cervical lymphadenopathy.

2. Investigations

A magnetic resonance imaging (MRI) scan was requested but because of the patients' claustrophobia a computerised tomography (CT) scan was performed (Fig. 2 a, b). This showed a well-defined fat density mass lesion measuring approximately 57 mm anteroposterior x 40mm medial lateral x 26mm craniocaudal in the left side of the tongue. This extended posteriorly into the base and was superior to the left genioglossus muscle and lingual artery. It was confined to the sublingual space with no deep extension to the mylohyoid or bone involvement.

* Corresponding author. Oral and Maxillofacial Surgery, Regional Maxillofacial Unit, University Hospital Aintree, Longmoor Ln, Liverpool, L9 7AL, UK.
E-mail address: yehya_gamie@hotmail.co.uk (Y.E.K. Gamie).

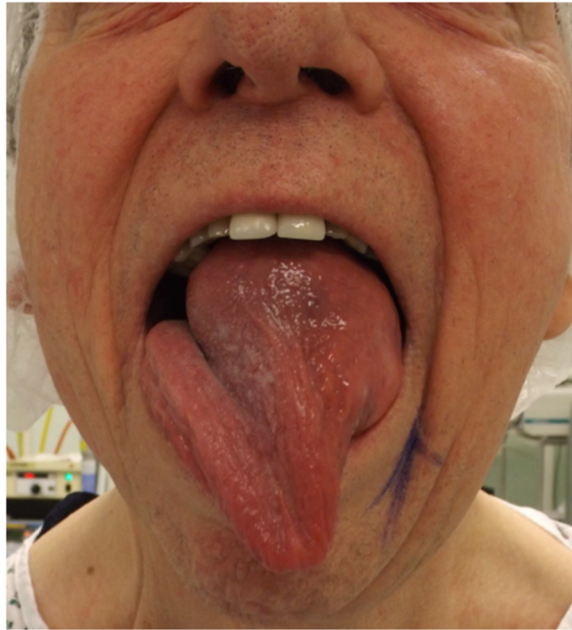


Fig. 1. Photograph of the tongue.

Differential diagnoses included granular cell tumours, neurofibromas, traumatic fibromas, haemangiomas, lymphangiomas, rhabdomyomas and salivary gland lesions (mucocele and mixed tumours) [1].

A punch biopsy under local anaesthetic was then performed for histopathological analysis. Microscopically the mucosa had parakeratosis, fibrosis, mild basal cell hyperplasia and no obvious dysplasia or inflammation. White soft tissue analysed showed sheets of packed mature adipocytes, consistent with a diagnosis of lipoma. No mitotic activity or atypia was seen. A diagnosis of lipoma was made. Histologically classic lipoma is the most common but variants include spindle cell lipoma, pleomorphic lipomas, fibrolipomas, chondroid lipomas, intramuscular or infiltrating lipomas, angio lipomas, salivary gland lipomas, myxoid lipomas and atypical lipomas ([2–4]).

3. Treatment

Initially it was decided to keep this benign lesion under review largely because of its asymptomatic nature and the risk of a functional defect and potential surgical morbidity if operated on.

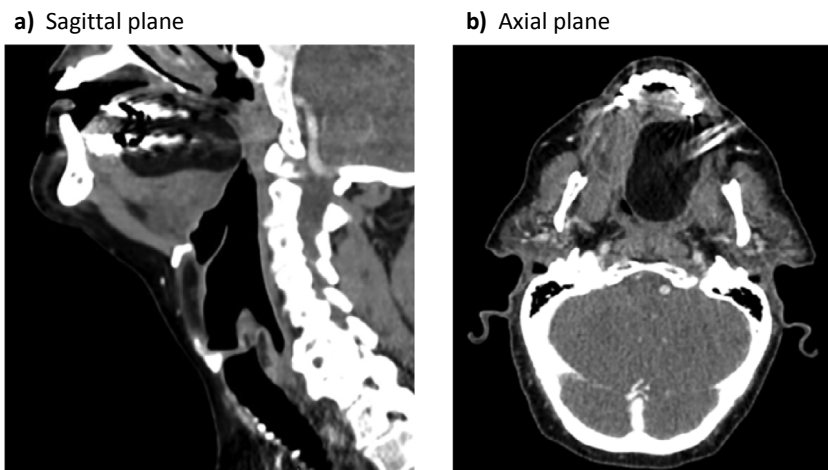

Fig. 2. CT scan of the head and neck showing an oval-shaped mass with distinct margins.

Download English Version:

<https://daneshyari.com/en/article/8706991>

Download Persian Version:

<https://daneshyari.com/article/8706991>

[Daneshyari.com](https://daneshyari.com)