

Case illustrated

A recurrent hydatid cyst of the thigh diagnosed 13 years after initial presentation

Sapha Barkati^{a,b,*}, Guillaume Butler-Laporte^a, Momar Ndao^{a,c}, Oluyomi Kabiawu Ajise^d, Makeda Semret^a, Cédric P. Yansouni^a, Michael Libman^a

^a J.D. MacLean Centre for Tropical Diseases, McGill University, Montreal, Canada

^b Centre Hospitalier de l'Université de Montréal (CHUM), Montreal, Canada,

^c National Reference Centre for Parasitology, Research Institute of the McGill University Health Centre, Montreal, Canada

^d Department of Pathology, McGill University Health Centre (MUHC), Montreal, Canada



ARTICLE INFO

Keywords:

Echinococcus granulosus
Hydatid cyst
Musculoskeletal hydatidosis
Surgical resection
Albendazole

ABSTRACT

This case presents a hydatid cyst of the thigh in a 57-year-old patient born and raised in rural Montenegro. He presented with a painful erythematous mass on the lateral aspect of the right thigh at the site of a previous cystic mass resection 13 years earlier. Complete surgical resection was conducted, histopathology revealed laminated membranes and polymerase chain reaction was positive for *Echinococcus granulosus*. Primary musculoskeletal hydatidosis is a rare entity and diagnosis is challenging. Any cystic lesion in a patient from an endemic area should raise the possibility of echinococcosis, regardless of anatomic location. The key aspects of diagnosis, albendazole treatment and surgical management are discussed.

A 57-year-old construction worker, born and raised in rural Montenegro, presented to the emergency department with a painful erythematous 7 × 6 cm mass on the lateral aspect of the right thigh (Fig. 1), at the site of a previous cystic mass resection 13 years earlier. The patient suffered from recurrent episodes of pain, swelling and erythema associated with minor traumas to the right thigh, although this relapse was more severe than prior episodes. No allergic symptomatology was reported. Histopathology of the submitted specimen from previously resected lesion had revealed a foreign body type of granulomatous reaction, with no malignancy or microorganism.

MRI showed a T1 hypointense lobulated cystic lesion in the previous surgical bed involving the vastus medialis and vastus intermedius muscles with extension to the dermis and subcutaneous prominence (Figs. 2 and 3,). Complete surgical resection was conducted. Histopathology revealed laminated membranes surrounded by dense fibrous tissue and granulomatous inflammation (Figs. 4 and 5,). Polymerase chain reaction amplification of the tissue block was positive for *Echinococcus granulosus*. A serum ELISA using crude antigens for *Echinococcus granulosus* was positive with an optical density (OD) of 0.59 (OD cut-off value: 0.35). Abdominal ultrasound and chest radiography showed no liver or lung involvement.

While primary musculoskeletal hydatidosis is a rare entity, and preoperative clinical and radiological diagnosis is challenging, any cystic lesion in a patient from an endemic area should raise the

possibility of echinococcosis, regardless of anatomic location [1]. Echinococcal serology can help support the diagnosis, and complete excision with albendazole therapy is the treatment of choice [2,3].

During the previous lesional excision, a significant amount of fluid was released, suggesting the cyst wall was breached. Though not diagnosed at the time, rupture of hydatid cysts increases the likelihood of recurrence. His episodes of recurrent localized inflammatory reaction were probably due to cyst leakage caused by minor traumas to the thigh. Prolonged albendazole treatment and follow-up are planned.

Authors contribution

All cited authors qualify for authorship according to the ICMJE recommendations.

SB was implicated in clinical care of the patient, reviewed medical chart, did the literature search and drafted the article.

GBL was implicated in clinical care of the patient, reviewed medical chart and revised critically the article.

MN is the parasitology laboratory director were polymerase chain reaction amplification for *Echinococcus granulosus* is performed and revised critically the article.

OKA is the pathologist who read the histopathology slides and who provided the histopathology images and revised critically the article.

MS was implicated in clinical care of the patient and revised

* Corresponding author at: 1001 Boul. Decarie, Montreal, Quebec, H4A 3J1, Canada.
E-mail address: sapha.barkati.chum@sss.gouv.qc.ca (S. Barkati).

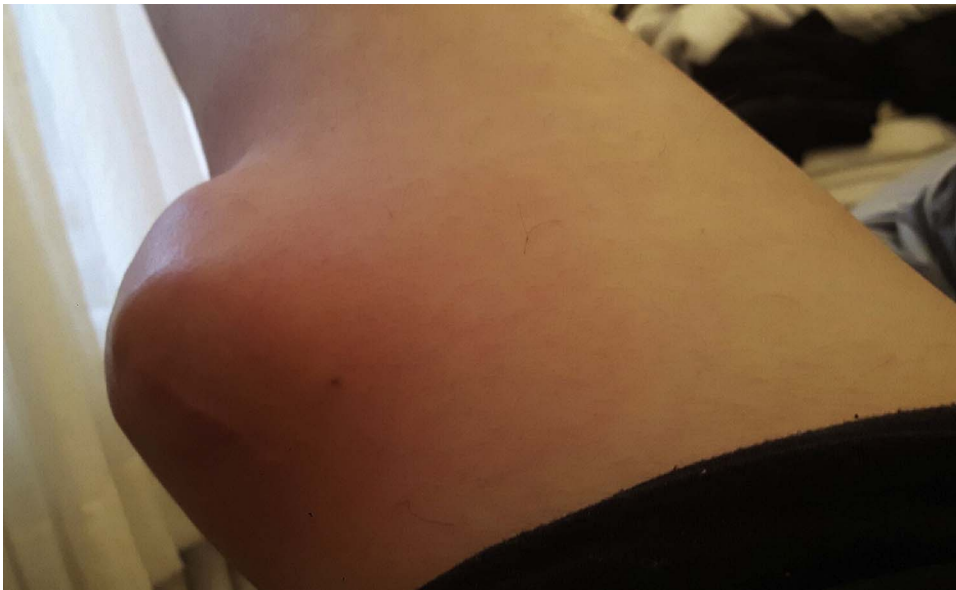

Fig. 1. Large erythematous mass at the lateral aspect of the right thigh.

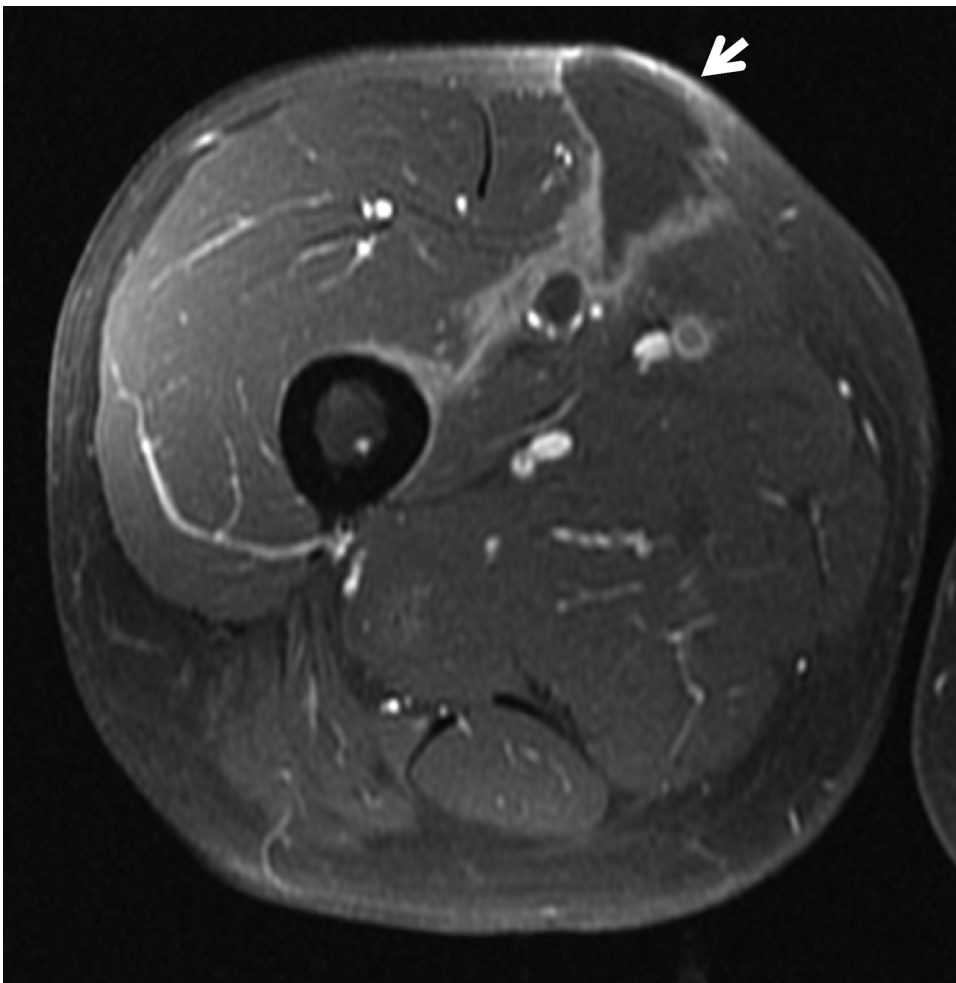


Fig. 2. Axial T1-weighted MRI of the right thigh showing a cystic lesion (white arrow) involving the vastus medialis and vastus intermedius muscles and extending up to the dermis.

critically the article.

CPY was implicated in clinical care of the patient and revised critically the article.

ML supervised clinical management, reviewed medical chart and revised critically the article.

All authors have read and approved the final manuscript.

The corresponding author declares she had full access to all the data and had final responsibility for the decision to submit for publication. Data supporting this manuscript are protected in the patient medical chart and laboratory information systems at our institution.

Download English Version:

<https://daneshyari.com/en/article/8745708>

Download Persian Version:

<https://daneshyari.com/article/8745708>

[Daneshyari.com](https://daneshyari.com)