



Contents lists available at ScienceDirect

# European Journal of Obstetrics & Gynecology and Reproductive Biology

journal homepage: [www.elsevier.com/locate/ejogrb](http://www.elsevier.com/locate/ejogrb)



## Correspondence

### Familial deep endometriosis: A rare monogenic disease?

#### ARTICLE INFO

*Article history:*  
Received 26 July 2017  
Available online xxx

*Keywords:*  
Deep endometriosis  
Chronic pelvic pain  
Dysmenorrhea  
Subfertility  
Gene  
Genetics

#### ABSTRACT

Endometriosis is a frequent cause of pelvic pain and subfertility in women of reproductive age. Presence of extra-uterine endometrial-like tissue is responsible for non-specific symptoms such as chronic pelvic pain, dysmenorrhea, dyspareunia, dyschesia and sometimes infertility. Three different phenotypes according to the location of the lesions are described, namely peritoneal, ovarian and deep infiltrating endometriosis. Deep endometriosis is considered as a distinct homogeneous disease. Heritability of endometriosis has been previously demonstrated. Despite extensive efforts to characterize candidate alleles contributing to genetic basis of endometriosis, these factors relevant to endometriosis pathophysiology remain unclear. No high penetrance pathogenic variant could be identified. We report herein two families with familial aggregation of severe deep infiltrating endometriosis, providing further evidence for monogenic mendelian inheritance of this form of endometriosis.

© 2017 Elsevier B.V. All rights reserved.

## Introduction

Endometriosis is a frequent cause of pelvic pain and infertility [1–3], and characterises by extrauterine location of functional endometrial tissue and non-specific symptoms. Presence of endometrial glands and stroma outside the uterus, may be observed into the peritoneal cavity or in rare cases on the diaphragm, pleura, and pericardium. Main clinical features include non-specific symptoms such as chronic pelvic pain, dysmenorrhea, dyspareunia, dyschesia and sometimes infertility [4]. Three different phenotypes according to the location of the lesions have been described, namely peritoneal, ovarian and deep infiltrating endometriosis [5]. Deep endometriosis is considered a distinct disease entity [2] and this extra-pelvic location of endometriotic lesions is particularly uncommon [6]. Several hypothesis, considering uterine or non uterine origin of the ectopic endometrial cells have been proposed. The Sampson's theory of retrograde menstruations is the most accepted [4], while metaplastic mesothelium differentiation or developmental origin of ectopic cells [7], dissemination through blood or lymphatic vessels have also been suggested. Pivotal pathways related to endometriosis include peritoneal inflammation [8], immune dysfunction [9,10] and angiogenesis [11]. Estrogen-dependent signaling, cell adhesion, migration and proliferation constitute major cellular events associated with endometriosis pathophysiology and disease progression [12,13]. Contribution of environmental factors to endometriosis pathophysiology has been established [14,15] and endometriosis is considered a multifactorial disorder.

Although endometriosis has been recognized as an heritable condition [16–18], its genetic determinants remain unclear.

Familial occurrence of endometriosis has been previously described and this may be important for the understanding of its genetic basis and pathophysiology. We report here clinical data of two families with a possible mendelian inheritance of the disorder. Advanced investigation of the genetic determinants involved in these families may increase the mechanistic understanding of endometriosis basis.

## Clinical reports

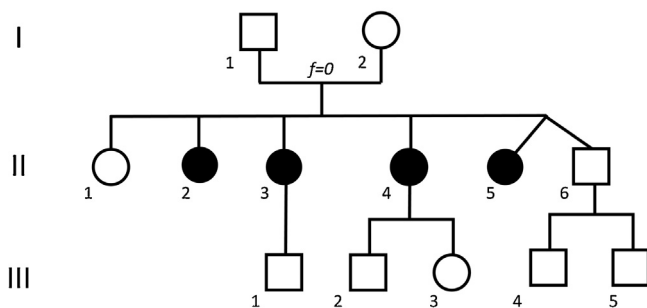
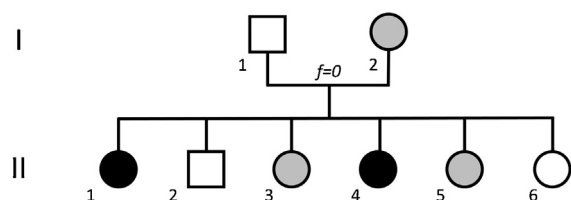
In the first family (Family A), four sisters were referred to the genetic consultation because they all had moderate to severe deep endometriosis (Table 1, Fig. 1). The proband, II.4, is a 38yo G2P2 woman presenting with pelvic pain since menarche, dysmenorrhoea, dyspareunia and dyschesia. Pelvic MRI showed a voluminous lesion of the recto-vaginal *cul-de-sac* and laparoscopic resection of the nodule was performed. Histological examination confirmed the diagnosis of stromal endometriosis. A severe, complicated, deep endometriosis was diagnosed in the sister of the proband, patient II.3. She presented with severe dysmenorrhoea, dyspareunia and dyschesia. Laparoscopic diagnosis of severe deep endometriosis occurred at the age of 26 years. Endometriosis of posterior vaginal *cul-de-sac* and torus, reaching uterosacral ligament and rectum have been identified in the pelvic MRI, as well as adenomyosis of posterior wall. Laparoscopic resection was performed at the age of 41 years. The patient II.5 presented with dysmenorrhoea and dyspareunia. Multiple pelvic deep endometriotic lesions have been identified, including a rectal lesion, lesion of the rectosigmoidal hinge, a voluminous lesion of the torus and vesical lesions. Surgical treatment included a nephroureterectomy. Patient II.2 had severe endometriosis, complicated by ureteral compression.

<https://doi.org/10.1016/j.ejogrb.2017.11.025>  
0301-2115/© 2017 Elsevier B.V. All rights reserved.

**Table 1**

Clinical features of the patients with familial endometriosis. N.D. no data available.

Family	Patient	Symptoms	Endometriosis	Age at diagnosis	Number of lesions	Localisation of the lesions	Comment
A	II.2	N.D.	severe deep	N.D.	N.D.	N.D.	ureteral compression
A	II.3	cyclic then daily pain, dysmenorrhea, dyspareunia, dyschesia, vesical pain	severe deep	26	>2	torus, posterior vaginal <i>cul-de-sac</i> , uterosacral ligament, rectum, bladder	surgical treatment
A	II.4	pelvic pain, dysmenorrhoea, dyschesia, dyspareunia	deep	38	2	rectosigmoid hinge, vagina, uterosacral ligament	recurrence, surgical treatment
A	II.5	dysmenorrhea, dyspareunia	severe deep	N.D.	2	rectosigmoid hinge, rectum, torus, bladder	left nephroureterectomy
B	I.2	dysmenorrhea	suspicion	N.D.	N.D.	N.D.	
B	II.1	pelvic pain, dysmenorrhea	severe deep	28	2	bladder, vesico-uterine pouch	transurethral bladder resection
B	II.3	pelvic pain	suspicion	N.D.	N.D.	N.D.	favourable outcome with hormonal treatment
B	II.4	pelvic pain, dysmenorrhoea, dyspareunia	severe deep	24	1	vesico-vaginal <i>cul-de-sac</i>	
B	II.5	pelvic pain	suspicion	N.D.	N.D.	N.D.	

**Family A****Family B****Fig. 1.** Pedigrees of families affected by deep endometriosis. The affected individuals are indicated with black circles. The individuals for whom the diagnosis of endometriosis has been strongly suspected, but not confirmed by coelioscopy, are indicated by shaded circles.

In the second family (Family B), four affected sisters and their mother presented with pelvic pain (Table 1, Fig. 1). The proband, patient II.1 presented with pelvic pain and dysmenorrhoea. A vesical mass was identified at pelvic ultrasound. The diagnosis of endometriosis was at the age of 28 years and led to a transurethral resection of the lesions. Recurrence of endometriosis was reported with a vesico-vaginal lesion and tubal obstruction. Patient II.3 had pelvic pain that responded to progestogen treatment. Endometriosis and adenomyosis had been suspected but not confirmed. Patient II.4 presented with pelvic pain since the menarche. Episodes of intolerable pain resistant to hormonal treatment started at the age of 18 years. Pelvic MRI showed a voluminous lesion of vesico-vaginal *cul-de-sac*. Laparoscopic resection at the age of 24 years confirmed the diagnosis of stromal endometriosis at the anatomopathological examination. Patient II.5 had pelvic

pain and strong suspicion of endometriosis. Patient I.2, mother of the proband gave a history of dysmenorrhoea.

**Discussion**

Familial aggregation of endometriosis suggested a strong influence of genetic factors [16,19,20]. An increase of endometriosis risk in first degree relatives of the affected patients has been documented [21–23]. In 1970, Ranney remarked the familial recurrence of endometriosis in 53 patients in a cohort of 350 patients treated by surgery for endometriosis [20]. Pairs of sisters, mother-daughter pairs and families with three affected sisters were the most frequent conditions. Later, Kennedy et al. described 5 families with at least 3 affected members, as well as 56 sister pairs, in a cohort of 230 patients with endometriosis [16]. An other familial cluster composed by three sisters and her mother has been described [24]. All individuals were affected by severe complicated endometriosis. Twin pair concordance studies confirmed the importance of genetic determinants in endometriosis [20,25–27]. Occurrence of endometriosis has been studied in two pairs of monozygotic twins in a series of 123 patients [28]. In 1994, eight siblings of twins with a 75% concordance have been described [27]. Twin pair analysis also allowed investigation of the role of environmental factors on endometriosis natural course. Hadfield et al. documented the disease status in an additional group of twin pairs, with 14 concordant and 2 discordant pairs, among 627 women [26] and an Australian twin sample has been later reported [29], estimating endometriosis heritability at 51%. A candidate gene approach allowed the identification and sequencing of over 70 genes, based on the review of relevant pathways. Detoxification enzymes as Glutathione-S-transferase enzymes were notably described, with polymorphisms in *GSTM1* and *GSTT1* [30]. Genotyping of candidate genes in a small number of patients did not lead to the conclusively association of these genes with endometriosis. Lack of power of original or replication studies, limited study size and the lack of replication suggest false positive association for some of these hits [25].

Genome-wide association studies (GWAS) have significantly improved our understanding of the molecular basis of endometriosis. At least ten genomic regions have been linked to increased endometriosis risk (Table S1). Data were replicated in consecutive studies, and across different populations [31–33]. Identified loci were mainly located in intergenic regions and the strongest association signals were observed in cohorts of patients with moderate to severe endometriosis [34,35]. Genes located in these regions are strong candidates for identifying the biological basis of endometriosis. Decoding these GWAS hits may enhance our understanding of the cellular

Download English Version:

<https://daneshyari.com/en/article/8778187>

Download Persian Version:

<https://daneshyari.com/article/8778187>

[Daneshyari.com](https://daneshyari.com)