



# A large hiatal hernia with cameron ulcer presenting as refractory sever iron deficiency anemia: A case report



Ayanaw Tamene\*, Masresha Mela

Bahir Dar University, College of Medicine and Health Sciences, Department of Pediatrics and Child Health, Ethiopia

## ARTICLE INFO

### Keywords:

Anemia  
Cameron lesions  
Cameron ulcer  
Hiatal hernia

## ABSTRACT

**Background:** Hiatal hernia is an abnormal protrusion of the stomach into thoracic cavity via esophageal hiatus. The prevalence is reported as 0.8–5.2% in upper gastrointestinal endoscopy. Patients with large diaphragmatic hiatal hernia occasionally manifest as sever iron deficiency anemia. The etiology is chronic bleeding from a gastric ulcer where a hiatal hernia passes through a diaphragmatic hiatus.

**Case presentation:** A 4-year-old female patient presented with easily fatigability, tinnitus, light headedness, epigastric abdominal pain, blacking of stool and geophagia of 1 year duration. She was transfused 03 times at different time at different hospital for congestive heart failure secondary to sever iron deficiency anemia while she was taking therapeutic iron therapy. The patient recovered completely after surgical repair of the hernia.

**Conclusion:** Cameron ulcer is a rare cause of iron deficiency anemia from chronic blood loss. It is fatal but easily treatable ulcer at hiatal hernia. It very rare in pediatrics age particularly under five children and high index of suspicion is lifesaving.

## 1. Introduction

Hiatal hernia is mostly an asymptomatic incidental finding during upper gastrointestinal endoscopy. This hernia is mostly associated with gastro esophageal reflux disease and Cameron ulcer. Cameron ulcer was first described by Cameron and Higgins in 1986 [1]. Cameron lesions are a linear ulcers or erosions on the gastric mucosal folds at the level of the diaphragm impressions from mechanical trauma secondary to diaphragmatic contraction from respiratory excursions in combination with acid injury [1,2]. It causes mainly iron deficiency anemia due to chronic gastrointestinal bleeding and dyspepsia [2]. Other complications are mucosal prolapse, incarceration, volvulus and esophageal shortening [3].

Cameron erosion and ulcers represent the mild and sever form of the same disease spectrum, respectively [2]. The exact prevalence of erosions and ulcers is not known. The prevalence rates of hiatal hernia ranges from 0.8 to 5.2 in all patients undergoing upper gastrointestinal endoscopy [3]. There are no case reports of Cameron lesions from African continent.

## 2. Case Presentation

A 4 years old female child presented to department of pediatrics and

child health with easily fatigability of 1 year duration associated with light headedness, tinnitus, geophagia, epigastric abdominal pain and intermittent blacking of stool. She had also history bilateral leg swelling, shortness of breath and fast breathing which was relieved by transfusion of 20 ml/kg of whole blood 02 times at 2 different district hospitals over 11 months period and referred to our hospital after 1 month of last transfusion. She had a total of 7 visits of health institution and was give iron for 1 year till arrival of emergency outpatient department (EOPD). She had no history nasal bleeding, malaria attack, fever or body rash. On our evaluation at EOPD, she was tachycardic and tachypnic with sever palmar pallor, systolic ejection murmur, S3 gallop and tender hepatomegaly despite her adherence for iron therapy.

On laboratory evaluation the following result were found: WBC = 8600/mm<sup>3</sup>, Hgb = 4.7 g/gl, Hct = 18.2%(8.1% drop within a month while on iron therapy), Plt = 529,000/mm<sup>3</sup>, MCV = 68.3 fl, RDWcv = 18.1%. Occult blood test was positive. Peripheral morphology showed hypochromic normocytic red blood cells. Helicobacter pylori stool antigen, stool examination, bone marrow aspiration, PT, PTT, INR, serum albumin and organ function test revealed normal result. Chest x-ray (Fig. 1) and chest ultrasound suggest diaphragmatic hernia. Barium meal study (Fig. 2) was conclusive for hiatal hernia. Congestive heart failure secondary to sever anemia was corrected with transfusion. Proton pump inhibitor with anti-acid syrup was given for

\* Corresponding author.

E-mail address: [zeelias04@gmail.com](mailto:zeelias04@gmail.com) (A. Tamene).

<https://doi.org/10.1016/j.epsc.2018.07.008>

Received 23 June 2018; Received in revised form 9 July 2018; Accepted 9 July 2018

Available online 12 July 2018

2213-5766/ © 2018 Published by Elsevier Inc. This is an open access article under the CC BY-NC-ND license (<http://creativecommons.org/licenses/by-nc-nd/4.0/>).

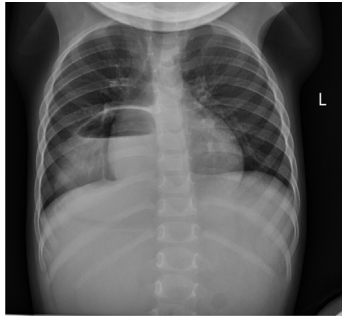


Fig. 1. Air fluid level over right lower chest and mediastinum on posteroanterior chest x ray.

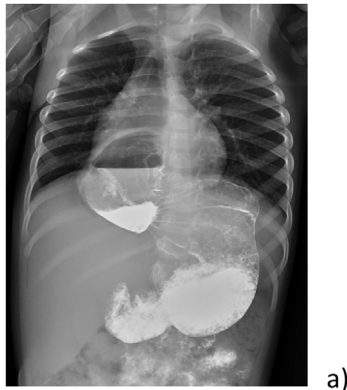

Fig. 2. Posteroanterior barium meal study shows air fluid level at mediastinum on right side and contrast agent seen above the diaphragm.

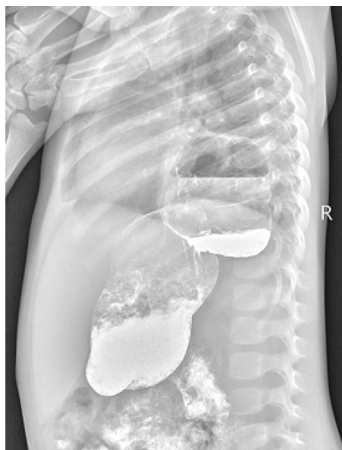

Fig. 3. Lateral barium meal study shows air fluid level at mediastinum on right side and contrast agent seen above the diaphragm.

01 month prior to surgery. Intra-operatively there was 4 cm by 5 cm hiatal defect in which stomach herniated without volvulus and the defect repaired by interrupted stitch. No mesh applied and fundoplication was not done. Hematocrit became 30% after transfusion and reached 40% after 01 month of surgery and anti-ulcer treatment. Anti-ulcer drugs were discontinued after a total 02 months treatment following resolution of epigastric pain, negative occult blood test and normalization of hematocrit. Endoscopy was not done to check healing of ulcer (no pediatric endoscopy). Chest x ray done after 02 month of surgical management showed normal. She had uneventful course after management and discharged from follow up after 6 month of surgical management (see Fig. 3).

### 3. Discussion

Hiatal hernia is an abnormal protrusion of stomach with or without another intra-abdominal organ through esophageal hiatus into the thoracic cavity [1,3]. The prevalence rates of hiatal hernia ranges from 0.8 to 2.9 in all patients undergoing upper gastrointestinal endoscopy [3]. It is classified into type I and type II [4]. Type I (sliding type) is the most commonly observed type associated with sliding of gastroesophageal junction with the stomach [5]. The incidence of hiatal hernia increases by advancing age due to relaxation at the diaphragmatic crura and esophageal shortening induced by short-term intraluminal acid perfusion in opossum resulting from aging process [6–8]. Hiatal hernia is commonly incidental asymptomatic find but may be associated with gastro esophageal reflux disease and Cameron ulcer.

Cameron lesions are a linear ulcers or erosions on the gastric mucosal folds at the level of the diaphragm impressions from mechanical trauma secondary to diaphragmatic contraction from respiratory excursions in combination with acid injury and ischemia [1,2,9]. Cameron erosion and ulcers represent the mild and severe form of the same disease spectrum, respectively [2]. Cameron ulcer was first described by Cameron and Higgins in 1986 [1]. The prevalence of Cameron ulcer is dependent on the size of hiatal hernia and increase as the size of hernia increases [10]. Cameron ulcers are seen in 5.2% of patients with hiatal hernia who undergo endoscopic gastroduodenoscopy [3]. There are no case reports of Cameron lesions from African continent accessed by the author likely not reporting or undiagnosed cases rather than epidemiological absence of this disease as there is no known genetic or environmental contributing factor.

It can be single, multiple, small or large. It causes mainly iron deficiency anemia due to chronic gastrointestinal bleeding and dyspepsia [2]. Other complications are mucosal prolapse, incarceration, volvulus and esophageal shortening [3]. Acute and chronic gastrointestinal bleeding from lineal ulcer or erosion is the commonest manifestation of Cameron lesion causing iron deficiency anemia [11,12]. Chronic gastritis associated with hiatal hernia also contributed to the development of anemia. Even though hiatal hernia is very rare in pediatrics age, there are few case reports of Cameron ulcer as early as 5 [13] years 7 [14] years old children. Our patient 4 years old patient whose symptoms started at the age of 3 years was the youngest age case report accessed by the author.

Clinical diagnosis of hiatal hernia and Cameron lesion is often difficult since they often present with gastroesophageal reflux disease and anemia [15]. Particularly in developing countries in a place where nutritional deficiency iron deficiency anemia, malaria, intestinal parasite and whole cows are commonest cause of anemia in young age, high index of suspicion has a pivotal role for the diagnosis of Cameron lesion in refractory iron deficiency anemia with gastrointestinal bleeding. Chest x ray and barium meal study can be used for first screening of hiatal hernia. It shows air fluid level in the mediastinum. Upper gastrointestinal endoscopy is the gold standard of diagnostic modality but it may miss the lesion and re look may be needed [16]. CT scan and MRI also may be diagnostic.

The treatment is mainly medical with acid suppressants and anti-ulcers for the ulcer and iron for anemia. If it is refractory, surgery is the definitive treatment [9]. No reports of recurrence of ulcer or hemorrhage after surgical management on long term follow up [17].

In our case she sign and symptoms of anemia for 01 year while she was on adequate dose of therapeutic iron. She was transfused whole blood 03 times for severe anemia secondary to congestive heart failure. Additionally, she was also complaining abdominal pain and blacking of stool. We reach to the diagnosis of a large hiatal hernia with Cameron ulcer presenting as refractory iron deficiency anemia made by chest x ray (gave the first clue for hernia), positive occult blood test and barium meal study.

Intra-operatively one-third of the stomach herniated to the thoracic cavity through 4 cm by 5 cm hiatal defect. After surgical correction,

Download English Version:

<https://daneshyari.com/en/article/8810757>

Download Persian Version:

<https://daneshyari.com/article/8810757>

[Daneshyari.com](https://daneshyari.com)